



Contents lists available at ScienceDirect

International Journal of Surgery Case Reports

journal homepage: www.casereports.com

Aldosterone deficiency after unilateral adrenalectomy for Conn's syndrome: a case report and literature review



Ekua Yorke^a, Sara Stafford^b, Daniel Holmes^c, Sachiv Sheth^c, Adrienne Melck^{a,*}

^a Department of Surgery, St. Paul's Hospital, Vancouver, British Columbia, Canada

^b Department of Endocrinology, Surrey Memorial Hospital, Surrey, British Columbia, Canada

^c Department of Pathology and Laboratory Medicine, St. Paul's Hospital, Vancouver, British Columbia, Canada

ARTICLE INFO

Article history:

Received 29 July 2014

Received in revised form

30 December 2014

Accepted 3 January 2015

Available online 10 January 2015

Keywords:

Aldosterone
Adrenalectomy
Hypertension
Conn's
Hypokalemia

ABSTRACT

INTRODUCTION: Approximately 35% of cases of Conn's syndrome (primary aldosteronism) result from a solitary functioning adrenal adenoma, and these patients are best managed by adrenalectomy. Postoperative hypoaldosteronism after unilateral adrenalectomy is uncommon.

CASE PRESENTATION: We present a case and literature review of hypoaldosteronism after unilateral adrenalectomy for Conn's syndrome, which demonstrates the insidious and sometimes delayed presentation.

DISCUSSION: In this clinical case we summarize the previously published cases of post-adrenalectomy hypoaldosteronism based on a PUBMED and EBSCOhost search of all peer-reviewed publications (original articles and reviews) on this topic. A few cases of aldosterone insufficiency post-adrenalectomy for Conn's syndrome were identified. The etiological factors for prolonged selective suppression of aldosterone secretion after unilateral adrenalectomy remain unclear.

CONCLUSION: It is important to be aware of the risk of postoperative hypoaldosteronism in this patient population. Close postoperative follow-up is necessary and strongly recommended, especially in patients with certain risk factors. Patients may need mineralocorticoid supplementation during this period.

© 2015 The Authors. Published by Elsevier Ltd. on behalf of Surgical Associates Ltd. This is an open access article under the CC BY-NC-ND license (<http://creativecommons.org/licenses/by-nc-nd/4.0/>).

1. Introduction

Primary aldosteronism (PA), or Conn's syndrome, results from unregulated release of excess aldosterone from one or both adrenal glands. Aldosterone-producing adenoma and bilateral idiopathic hyperaldosteronism are the two most common subtypes of PA. A much less common form, unilateral hyperplasia, is caused by micronodular or macronodular hyperplasia of the zona glomerulosa of predominantly one adrenal gland [1]. Between 30 and 35% of PA cases result from a solitary functioning adrenal adenoma [1] and these patients are best managed by adrenalectomy. Postoperatively, some patients may experience transient hypoaldosteronism requiring mineralocorticoid replacement, but this is an uncommon scenario. Here, we present a case report and literature review of hypoaldosteronism after unilateral adrenalectomy for PA.

2. Presentation of case

A 66-year-old female was referred for surgical management of her PA in January 2012. The patient presented with a

13-year history of hypertension and hypokalemia. On presentation, she was on nifedipine and triamterene/hydrochlorothiazide, but her blood pressure remained elevated at 134/84 mmHg. On June 29th 2011 she had a serum aldosterone level of 688 pmol/L (normal 70–660) which was associated with a suppressed plasma renin level of <0.05 ng/L/s (normal 0.05–0.55) yielding an elevated aldosterone/renin ratio of >13,760 (normal <2500). Her plasma potassium at this time was 3.9 mmol/L (normal 3.5–5.0 mmol/L). Soon after these results were received, spironolactone was added. On August 12th 2011, she was taken off her triamterene and spironolactone. At the same time she was started on potassium supplementation and her potassium was closely followed.

On September 26th 2011, after she had been off the spironolactone and triamterene for six weeks, she underwent confirmatory testing with a saline suppression test which was positive (post-saline aldosterone 445 pmol/L, normal <140 pmol/L). A CT scan revealed a 1.8 cm nodule in the left adrenal gland consistent with an adenoma and a normal appearing right adrenal gland (Fig. 1). She went on to have adrenal venous sampling on November 17th 2011 which showed marked left dominance in aldosterone production with a lateralization index of 72.6, well above the commonly employed threshold of 4 used to define lateralization [2].

In March 2012, she underwent an uneventful left retroperitoneoscopic adrenalectomy. She was discharged home on the first

* Corresponding author. Tel.: +1 604 806 9108.

E-mail address: amelck@providencehealth.bc.ca (A. Melck).

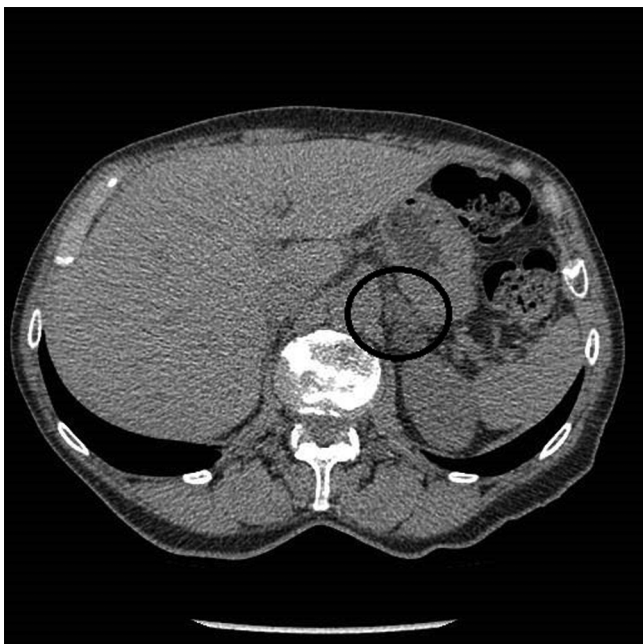


Fig. 1. CT image of left 1.8 cm adrenal nodule with an average attenuation of 2.6 Hounsfield units.

postoperative day with a blood pressure of 135/71 mmHg. She was advised to continue her preadmission antihypertensives except for spironolactone.

Gross pathologic examination revealed an 18.3 gram left adrenal gland measuring $6.0 \times 3.5 \times 1.5$ cm with a 1.8 cm round, firm, and well-circumscribed orange-tan nodule within the adrenal cortex without areas of hemorrhage or degeneration. The residual adrenal cortex appeared grossly normal without significant atrophy. Microscopic sections of the nodule confirmed the presence of a fibrous pseudocapsule at the expansive border of the tumor (Fig. 2). The component cells had large pale-staining, lipid-rich cytoplasm and smaller cells with relatively sparse lipid and lightly eosinophilic cytoplasm. Nuclear pleomorphism, hyperchromasia, and mitotic figures were absent (Fig. 3). These findings were consistent with a benign adrenal adenoma. The microscopic examination of the remaining adrenal cortex was normal, and there were no signs of nodular hyperplasia.

At her first follow-up appointment three weeks after surgery, her nifedipine had been stopped and her triamterene/hydrochlorothiazide halved. She was complaining of lightheadedness and her blood pressure was 130/80 mmHg. Her plasma potassium without any supplementation was normal at 4.9 mmol/L. Her remaining antihypertensives were discontinued. At her next follow-up visit four weeks postoperatively, she had ongoing lightheadedness and was found to be hypotensive with a blood pressure of 102/72 mmHg. Additionally, her potassium was elevated at 6.1 mmol/L and sodium was decreased at 132 mmol/L (normal 135–148). She was diagnosed with aldosterone deficiency and started on aldosterone replacement (fludrocortisone 0.1 mg daily). Her fludrocortisone was successfully weaned over the following months. By six months postoperatively she was off all medication, her potassium had normalized to 4.2 mmol/L and her blood pressure also normalized to 122/72 mmHg.

3. Discussion

We performed a literature review based on a search of all peer-reviewed publications on PUBMED and EBSCO-host databases. Our search terms included “aldosterone”,

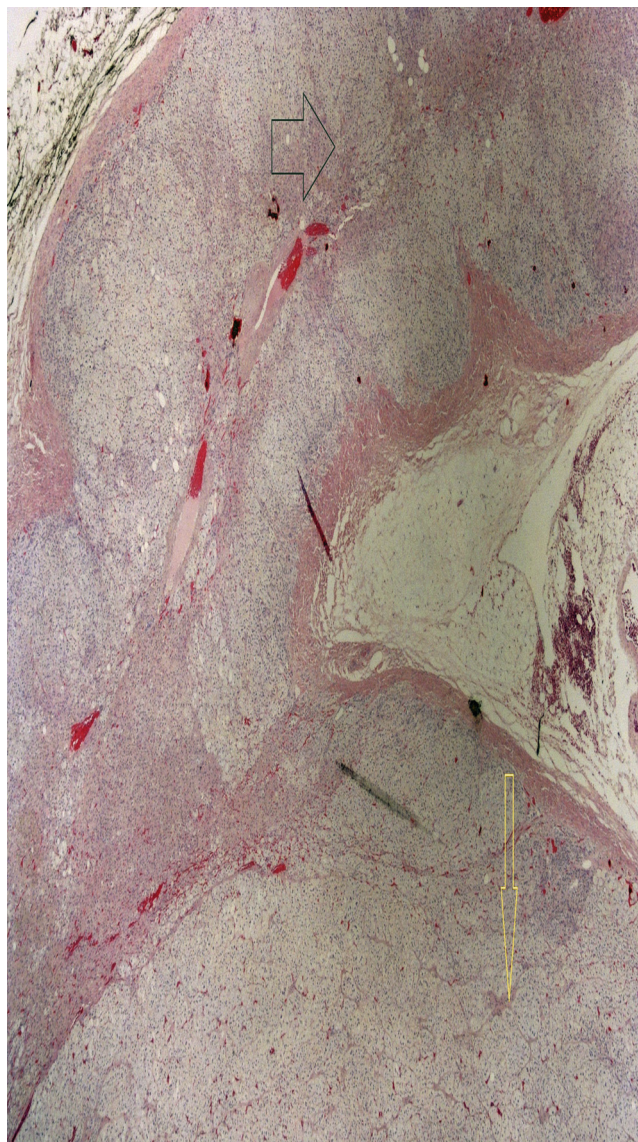


Fig. 2. Low power view (2× objective) of an adenoma with expansive smooth borders (yellow arrow) sharply demarcated from the adjacent normal adrenal cortex (black arrow).

“primary aldosteronism”, “adrenal adenoma”, “hyperaldosteronism”, “adrenalectomy”, “postoperative hyperkalemia”, “postoperative hypoaldosteronism”, “hyperkalemia”, “hypoaldosteronism”, and “adrenal hypotension”. The search was not restricted by date or language of publication.

After unilateral adrenalectomy for PA, some patients manifest hyperkalemia postoperatively [3]. Some think this is due to the inability of the remaining adrenal gland to secrete sufficient amounts of aldosterone immediately after surgery [3,4]. In 2010, Huang et al [5] described a case of a 62-year-old man who presented with prolonged and severe hyperkalemia after laparoscopic left adrenalectomy for an aldosteronoma. Two weeks after his surgery, he was found to have hyperkalemia and volume depletion. His volume depletion was determined by poor skin turgor, flat jugular veins and postural hypotension. The patient findings of elevated plasma renin activity and inappropriately low aldosterone in the setting of normal plasma cortisol and adrenocorticotropic hormone (ACTH) suggested hypoaldosteronism. They attributed the hypoaldosteronism to be due to defects in aldosterone biosynthesis or selective unresponsiveness to angiotensin II in the adrenal zona

Download English Version:

<https://daneshyari.com/en/article/4289146>

Download Persian Version:

<https://daneshyari.com/article/4289146>

[Daneshyari.com](https://daneshyari.com)