



Contents lists available at ScienceDirect

International Journal of Surgery Case Reports

journal homepage: www.casereports.com

A large primary dumbbell hydatid cyst causing neural foraminal widening of the thoracic spine: A case report and literature review



Ahmet Karakasli^b, Murat Yilmaz^{a,*}, Ali Osman Mucuoglu^a, Alaattin Yurt^c

^a Department of Neurosurgery, Dokuz Eylul University Medical Faculty, Izmir, Turkey

^b Department of Orthopedics, Dokuz Eylul University Medical Faculty, Izmir, Turkey

^c Department of Neurosurgery, Bozyaka Training and Research Hospital, Izmir, Turkey

ARTICLE INFO

Article history:

Received 9 October 2014

Received in revised form

25 November 2014

Accepted 28 December 2014

Available online 16 January 2015

Keywords:

Echinococcosis

Hydatid cyst

Surgical treatment

Thoracic spine

ABSTRACT

INTRODUCTION: Spinal hydatid cyst is a rare, but serious condition.

PRESENTATION OF THE CASE: Herein, we present a 17-year-old male patient with back pain radiating to the legs and progressive weakness in the lower limbs. CT and MRI showed a spinal-paraspinal hydatid cyst with a dumbbell appearance that caused neural foraminal widening and spinal cord compression. The case was explored via right T3-T4 hemilaminectomy, and the hydatid cyst was completely removed.

DISCUSSION: The clinical presentation, diagnosis, and surgical treatment of this rare case of spinal hydatid disease are discussed, and all published cases of primary dumbbell hydatid cyst are reviewed.

CONCLUSION: Even if serological test results are negative, hydatid cysts should be considered in the differential diagnosis of cystic lesions of the spine.

© 2015 The Authors. Published by Elsevier Ltd. on behalf of Surgical Associates Ltd. This is an open access article under the CC BY-NC-ND license (<http://creativecommons.org/licenses/by-nc-nd/4.0/>).

1. Introduction

Hydatid cyst disease is caused by *Echinococcus granulosus* infection [1,2]. Transmission of the pathogen to humans occurs via ingestion of food infected with the parasite's eggs. The liver and lungs are the most frequent locations of *E. granulosus* infection [1,2,6,22], whereas 0.5–2.0% of all cases occur in the musculoskeletal system, of which 50% of cases are spinal hydatid cyst [2,4,14,17,26].

The appearance of a dumbbell-shaped mass in the thoracic spine is highly suggestive of neurofibroma. Hydatid cysts, although very rare, can have a similar appearance [2,11,13,26]. Hydatid cysts of the bone and muscle are always primary, and neurologic recovery is possible because they are slow-growing lesions. Herein we present a 17-year-old male patient with a spinal-paraspinal hydatid cyst with a dumbbell appearance that caused neural foraminal widening and spinal cord compression. The patient was treated successfully via total surgical excision; no further medical treatment was required. The case's clinical symptoms and differential diagnosis are discussed, and the relevant literature is reviewed.

2. Case report

A 17-year-old male presented with a 2-month history of back pain radiating to the legs, progressive weakness in the lower limbs, and difficulty walking. Physical examination findings were normal. Neurological examination showed paraparesis, which was prominent on the left side. The patient also had urinary and fecal incontinence.

There are no specific laboratory signs of hydatid disease. The patient had a negative history of surgery for hydatid cysts. Abdominal ultrasonography, and MRI of the cranium and cervical region were normal. CT showed cystic lesions originating from the vertebral body and erosive widening of left T3-T4 neural foramen, which produced a dumbbell appearance because there were intraspinal and paraspinal components. The lesion was hypointense on T1-weighted MRI and hyperintense on T2-weighted MRI (Fig. 1a and b). Sagittal MRI showed epidural region extension of the lesion, which was compressing the dura and spinal cord. Initially, the lesion was considered a hydatid cyst, but serological testing (specific ELISA/Western blot) proved negative. The cyst was surgically exposed via left T3 hemilaminectomy and T3-T4 partial facetectomy, dissected from the spinal dura, nerve root, surrounding bone, and paraspinal space, and completely removed (Fig. 2). The exposure showed an encapsulated destructive lesion arising from the T3-T4 neural foramen. The area was irrigated with hydrogen

* Corresponding author. Tel.: +90 232 4123310/532 6215970; fax: +90 232 2788802.

E-mail address: muratran@yahoo.com (M. Yilmaz).

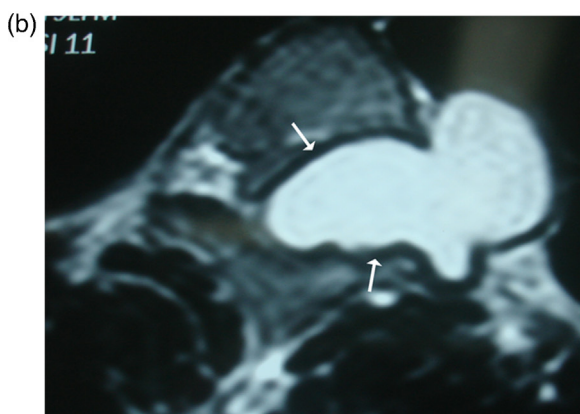
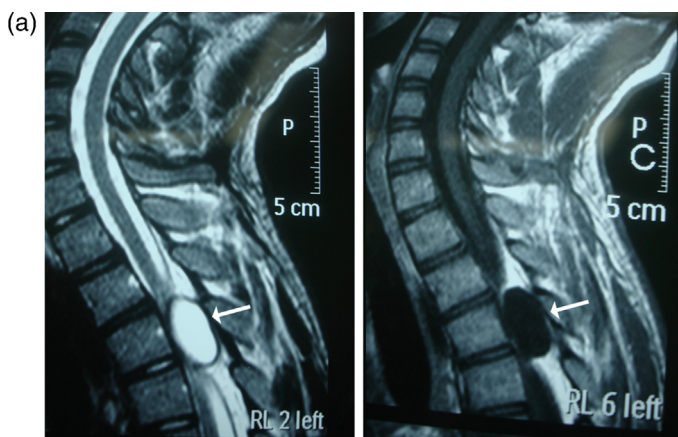


Fig. 1. (a) The cystic lesion (white arrows) is seen as hypointense in T1-weighted and hyperintense in T2-weighted sagittal MRI at the T3 and T4 levels. (b) The cystic lesion (white arrows) is seen as hyperintense in T2-weighted axial MRI at the T3 and T4 levels.

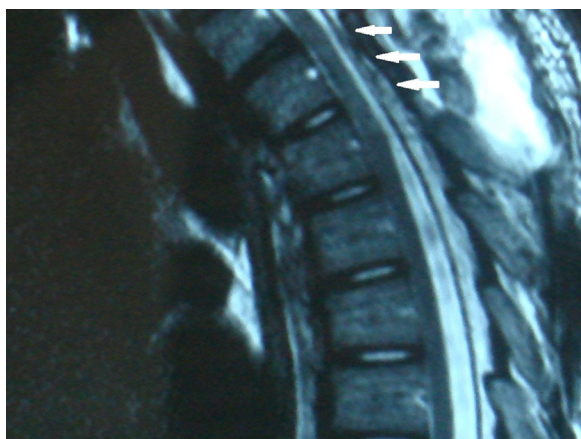

Fig. 2. The hydatid cyst was dissected from the spinal dura, nerve root, surrounding bone, and paraspinal space, and completely removed.

peroxide. Histopathological examination confirmed the diagnosis of hydatid cyst.

Follow-up examination 5 months post surgery showed that the patient’s paraparesis resolved almost completely and postoperative MRI showed that the hydatid cyst had been completely removed (Fig. 3). The patient was completely recovered 6 months post surgery.

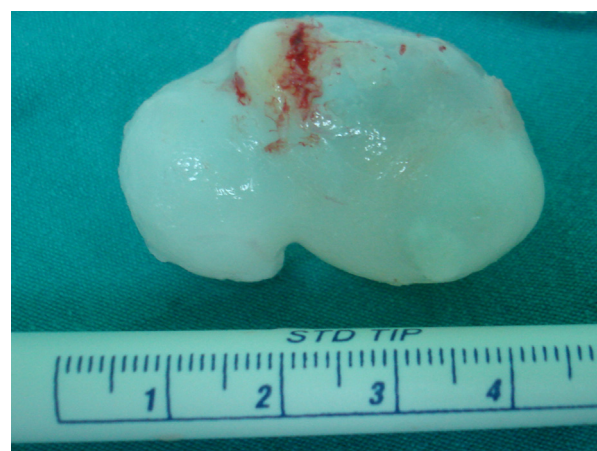

Fig. 3. T2-weighted sagittal MRI shows that the hydatid cyst was completely removed (white arrows).

3. Discussion

Hydatid disease is a zoonosis produced by the larval stage of *E. granulosus* and *Echinococcus multilocularis*, and occurs worldwide [1,2,4,6,10,12,18,20]. *E. granulosus* manifests as the common hydatid form and *E. multilocularis* manifests as the rare alveolar form. The former is the more benign form and is characterised by cyst formation, whereas the latter is not encapsulated and presents as a ramifying, porous, and necrotic mass. The prognosis for the alveolar form is extremely poor, with an almost 100% mortality rate [5,7,10]. Their gradual invasion of adjacent tissue is tumor-like and sections of parasite may metastasize to distal parts of body. Initial imaging studies are usually highly suspicious for carcinoma or sarcoma [6,7,10].

In humans hydatid disease involves the liver in approximately 75% of cases, the lungs in 15%, and other anatomic locations in 10%. The frequency of osseous involvement in hydatid disease is 0.5–4% [18,20,24,26]. It most commonly occurs in the spine (50%) and pelvis [4,5,7,18]. In the presented case the lesion extended to the paraspinal and intraspinal space. Spinal hydatid cysts are usually situated in the dorsal region and generate medullary or radicular symptoms, according to their location [2,6,12,15,16,20]. In the present case the hydatid cyst was extradural and located in the dorsal region, with paraspinal extension. To the best of our knowledge widening of the spinal neural foramen caused by hydatid cyst has been reported only one case [17]. Parvaresh et al. [17]. reported a dumbbell hydatid cyst of the spine, but in their case spinal involvement of hydatid disease was considered secondary, because the primary lesion was located in the liver, whereas in the presented case spinal involvement was primary.

Primary hydatid infestation of the spine without any other systemic involvement can be explained by the direct porto-vertebral venous shunt theory, as follows: in rare instances the disease begins in the extradural area, suggesting that the parasite’s embryo is possibly being transported through the porto-vertebral venous shunts [6,9,10]. Braithwaite and Lees classified spinal hydatid cysts into 5 radiological types: intramedullary, intradural-extramedullary, extradural, hydatid cyst of vertebrae, and paravertebral lesions extending to spinal structures [6]. The last 2 types affect the spinal neural structures via extension and these are more common, but the first 3 types are primary and extremely rare. Based on the presented case, we think that hydatid cysts can pass through the neural foramen to produce a dumbbell-shaped lesion. CT and MRI findings in the presented case were typical for hydatid cyst, which facilitated exclusion of the aforementioned lesions from the differential diagnosis.

Download English Version:

<https://daneshyari.com/en/article/4289172>

Download Persian Version:

<https://daneshyari.com/article/4289172>

[Daneshyari.com](https://daneshyari.com)