



Contents lists available at ScienceDirect

International Journal of Surgery Case Reports

journal homepage: www.casereports.com

Can pelvic tilting be ignored in total hip arthroplasty?

Won Yong Shon^{a,*}, Vivek Sharma^a, Oh jong keon^a, Jun Gyu Moon^a, Dong Hun Suh^b^a Department of Orthopedics Surgery, Korea University, Guro Hospital, Seoul, South Korea^b Department of Orthopedics Surgery, Korea University, Ansan Hospital, Gyeonggi-do, South Korea

ARTICLE INFO

Article history:

Received 1 January 2014

Received in revised form 29 June 2014

Accepted 16 July 2014

Available online 24 July 2014

Keywords:

Dislocation

Impingement

Surgical anteversion

Acetabular component

Spino-pelvis sagittal balance

Total hip arthroplasty

ABSTRACT

INTRODUCTION: The orientation of acetabular component is influenced by pelvic tilt, body position and individual variation in pelvic parameters. Most post-operative adverse events may be attributed to mal-position of the component in the functional position. There is evidence that orientation of the pelvis changes from the supine to standing position. Authors report a case of recurrent dislocation after total hip arthroplasty due to excessive pelvic tilting.

PRESENTATION OF CASE A 69-year old female with coxarthrosis had undergone total hip replacement with recurrent dislocation of the hip on bearing weight in spite of using constrained acetabular component.

DISCUSSION: Our case report substantiates the influence of pelvic tilt, incurred by a sagittal deformity of spine, on dynamic orientation of the acetabular cup which was positioned in accordance with the anatomic landmarks alone. If the reference is only bony architecture and dynamic positions of the pelvis are not taken into account, improper functional orientation of the acetabular cup can result in sitting and standing positions. These can induce instability even in anatomically appropriately oriented acetabular component.

CONCLUSION: The sagittal position of pelvis is a key factor in impingement and dislocation after total hip arthroplasty. Pelvic tilting affects the position of acetabular component in the sagittal plane of the body as compared with its anatomic position in the pelvis. We suggest a preoperative lateral view of spine-pelvis, in upright and supine position for evaluation of a corrective adaptation of the acetabular cup accordingly with pelvic balance.

© 2014 The Authors. Published by Elsevier Ltd. on behalf of Surgical Associates Ltd. This is an open access article under the CC BY-NC-SA license (<http://creativecommons.org/licenses/by-nc-sa/3.0/>).

1. Introduction

In total hip arthroplasty, anterior or posterior tilt of the pelvis can affect the position of acetabular component in the sagittal plane of the body as compared with its anatomic position in the pelvis.^{1–3} The rotation of pelvis leads to anterior tilt (where the upper portion of the pelvis tips forward) and posterior tilt (upper portion of the pelvis tips backward).³ The aging process and spinal deformities may lead to an altered sagittal balance. The sacrum and pelvis therefore forms a rigid structure (sacropelvis), which translates and rotates around the bicoxofemoral axis for the necessary compensatory balance.⁴

Of importance is the fact that each individual possesses a pelvic equilibrium which is specific and is different in standing and lying positions; however there are variations in the position of pelvis from the lying to the standing position.^{2,5,6} Consequently the

orientation of the acetabular cup version changes dynamically from supine to standing position. In the presence of a normal range of motion of the spine, the pelvis rotates around the transverse axis giving some room for adjustment during movements of the prosthetic hip. We now report a patient who had recurrent dislocations after total hip arthroplasty because of excessive pelvic tilting.

2. Presentation of case

This was a 69-year old female with painless limp without any significant history of trauma, with associated severe degenerative kypho-scoliosis. She had left hip coxarthrosis [Fig. 1]. Total hip arthroplasty was performed by a posterolateral approach in lateral decubitus position, using a ceramic on metal articulation. A 48 mm acetabular cup (Pinnacle[®]) 28 mm metal head and a standard offset stem (Summit[®]) [Depuy, USA] were used.

Postoperative radiographs showed inclination of the cup 45° on anterior posterior view and anteversion 24° on the lateral view [Fig. 2]. Hip was stable preoperatively with adequate soft tissue tension. The hip dislocated anteriorly, postoperative three

* Corresponding author. Tel.: +80 2 2626 3085.

E-mail addresses: shonwy@hotmail.com (W.Y. Shon), hun.suh@gmail.com (D.H. Suh).

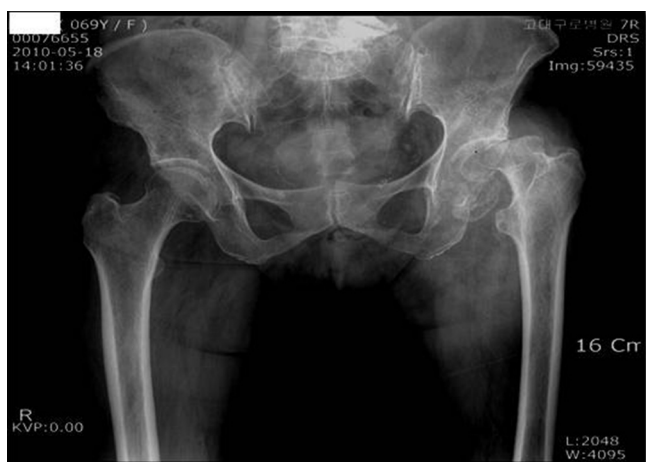

Fig. 1. Anteroposterior view of pelvis with both hips showing left hip coxarthrosis.

months during standing position while walking, and was confirmed by radiography [Fig. 3]. Closed reduction was followed by recurrence of anterior dislocation four weeks later. Revision was done with a constrained liner (Duraloc shell, 50 mm constrained liner 28 × 50 mm Depuy USA). Postoperative radiographs showed inclination of the cup 45° and acetabular component anteversion 24° in supine position.

After episode of anterior dislocation with constrained liner [Fig. 4], the relevant pelvic parameters were studied but only open reduction with exchange of constrained polyethylene liner was done because patient's guardian refused re-revision of second acetabular cup. During the postoperative period the patient was maintained in the hip brace at 15° abduction and 15° flexion for six months by locking the joint in the brace and allowing only about 75° of flexion of the hip joint and also preventing adduction during walking in standing position. The patient had been amenable to postoperative prophylactic care and the tendency to dislocation eventually had resolved.

Apart from routine radiographs, sacral tilt (ST) and measured acetabular tilt (MAT) were determined in lateral radiographs for evaluation of any pelvic tilt, as described by Lazennec et al.³ Measurements were made using a digitized computer system PACS (picture archiving and communication system PiView STAR version 5, Infinit, Seoul Korea). ST measured in supine and standing position was 49° and 16° and MAT in supine and standing position was 25° and 60° respectively [Fig. 5].

3. Discussion

The sagittal position of pelvis is a key factor in impingement as well as dislocation; it is not vertical nor is it static.⁷ In supine position, the pelvis tilts anteriorly, which decreases anteversion of the acetabular component, and in the standing and sitting position, the reverse happens and anteversion is increased.^{3,8}

Optimal adjustment of the acetabular cup is of utmost importance for ensuring stability and maximum range of motion of the prosthetic joint, without causing impingement on the femoral neck.¹⁰ After total hip arthroplasty increased anterior tilt of acetabular component can cause posterior impingement and anterior dislocation, similarly, posterior tilt or retroversion can cause anterior impingement and posterior dislocation.¹¹

Impingement was prevalent even when components were implanted in the anatomic safe zone in a study of 162 retrieved acetabular components.¹² With increased trend of using hard on hard bearing surfaces, minimizing the risk of impingement which leads to catastrophic events like chip fracture, metallosis, and loosening in these bearing surfaces should be considered.

When faced with this disappointing outcome, it is worth reckoning that component orientation is made in static lying position, whereas prosthesis dislocates out of the result of a dynamic phenomenon which occurs during change in position during the movements of daily life.^{2,3,5,7} This is a reasonable explanation, as to why an anatomically oriented cup, placed in supine position may functionally prove to be wrongly oriented, so favoring subsequent dislocations.

The patient described here had a fixed kyphoscoliotic deformity, which was compensated by pelvis being tilted posteriorly with a more vertical position of the sacrum. This verticalized the cup and placed the hip in hyperextension during change of position from supine to standing position.^{2,3} A retroverted pelvis led to functional anteversion that was more than the normal range, causing uncovering of the femoral head anteriorly.⁸ Even though the cup was placed appropriately in accordance with the pelvic bony landmarks it led to posterior impingement and anterior dislocation.

This patient had constant low values of ST in supine and standing position, signifying posterior tilt of the pelvis. ST showed variation of 33° from supine to standing position, which was much more than normal variation.^{2,6,9} Reported normal range of pelvic extension from supine to standing position is less than 10–15°.^{2,5} The patient was clearly an outlier among the 5–7% of people who demonstrate excessive hyperextension of hip from supine to standing position.² There is significant inter-subject and intra-subject variation in ST and MAT values from supine to standing position which is directly

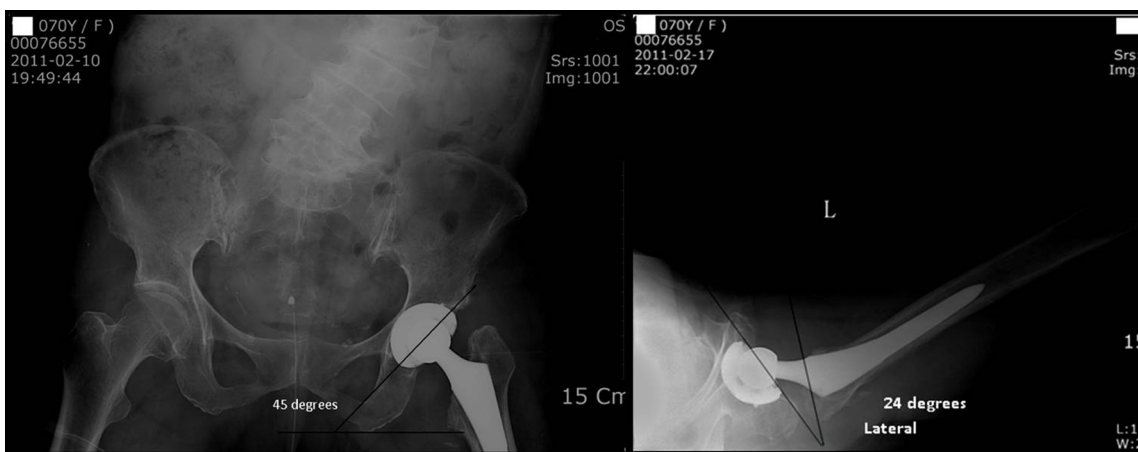


Fig. 2. Anteroposterior and lateral view of total hip replacement.

Download English Version:

<https://daneshyari.com/en/article/4289525>

Download Persian Version:

<https://daneshyari.com/article/4289525>

[Daneshyari.com](https://daneshyari.com)