

Contents lists available at [SciVerse ScienceDirect](http://www.elsevier.com/locate/ijscr)

International Journal of Surgery Case Reports

journal homepage: www.elsevier.com/locate/ijscr

A multidisciplinary approach to desmoid tumors. When intra-abdominal fibromatosis degenerates into an abscess, which is the right treatment?☆



Giovanni Alemanno*, Daniela Zambonin, Alessandro Sturiale, Tiziana Cavalli, Francesco Bellucci, Benedetta Pesì, Carmela Di Martino, Francesco Giudici, Francesco Tonelli

Digestive Surgery Unit, Department of Clinical Physiopathology, University of Florence Medical School, Careggi University Hospital, Florence, Italy

ARTICLE INFO

Article history:

Received 17 January 2013
Received in revised form 20 April 2013
Accepted 9 May 2013
Available online 15 June 2013

Keywords:

Desmoid tumor
familial adenomatous polyposis

ABSTRACT

INTRODUCTION: Desmoid tumors are rare benign tumors that originates in the fibrous sheath or musculo-aponeurotic structure. Histologically benign, they tends to invade locally and to be recurrent.

PRESENTATION OF CASE: We report a rare case of an intra-abdominal desmoid tumor in a patient affected by familial adenomatous polyposis, which degenerated into abscess. Male, 38 years, was hospitalized for abdominal pain, bowel obstruction and fever. The computed tomography showed a big dishomogeneous mass occupying the whole mesentery with internal massive liquefaction. The mass extended from the epigastrium for 13 cm up to L3. On the right mesogastric side a solid, thick mass of about 2 cm, with a length of 4.5 cm, was identified; it was not cleavable from the wall and from some of the loops. We decided to perform a computed tomography-guided percutaneous drainage. Two hundred ml of purulent necrotic material was aspirated, and washing with antibiotic solution was carried out. Cytological examination of fluid drainage showed histiocytes and neutrophils. At follow-up, the patient's clinical condition had improved. An abdominal ultrasound showed a substantial reduction in the diameter of the mass.

DISCUSSION: Diagnosis and treatment of desmoids tumor in patients with familial adenomatous polyposis may be difficult, especially when desmoids are located intra-abdominally and in the mesentery. Seldom will desmoid tumors be complicated by abscess formation.

CONCLUSION: The management of desmoids tumors is not easy and the choice of the best treatment may be difficult due to the different possible anatomical presentations.

© 2013 Surgical Associates Ltd. Published by Elsevier Ltd. Open access under [CC BY-NC-ND license](http://creativecommons.org/licenses/by-nc-nd/3.0/).

1. Introduction

Desmoid tumors (DTs) are rare benign tumors originating from the proliferation of well differentiated fibroblast. They are benign with no metastatic capacity, yet locally aggressive. They tend to invade locally and to have recurrences following local excision; hence, may be considered as malignant. Sporadic or associated with Familial Adenomatous Polyposis (FAP), DTs have a multifactorial etiology. In FAP patients, they are associated with germline

mutations beyond codon 1444 of the APC (Adenomatous Polyposis Coli) gene and their appearance is more frequent after laparotomy.

Desmoid tumors can grow intra-abdominally, extra-abdominally or within the abdominal wall. Desmoid tumors localized in the abdomen have a worse prognosis, as they may cause intestinal obstruction, ureter obstruction with hydronephrosis and may also invade major vessels.¹ Degeneration into an abscess is a rare condition.

The peculiar aspect of this case is the abscess formation on an intra-abdominal desmoid tumor. In literature, few cases of DTs presented as an abscess are reported, and the treatment of choice for these tumors is not yet clearly defined.

2. Presentation of case

Male, 38. At 31 he was diagnosed FAP after colonoscopy (father died at 33 of colon cancer). The patient underwent surgery: a total colectomy, an ileo-rectal anastomosis and a temporary ileostomy

Abbreviations: DT, desmoid tumor; FAP, Familial Adenomatous Polyposis; APC, Adenomatous Polyposis Coli; CT, computed tomography; MRI, Magnetic resonance imaging.

☆ Authors declare that only the abstract of this clinical case was presented to the 35th SICO (Italian Society of Surgical Oncology) National Congress (14 June 2012) and therefore published in the Abstracts section of the European Journal of Surgical Oncology.

* Corresponding author at: Careggi Hospital, Digestive Surgery Unit, Largo Brambilla 3, 50134 Florence, Italy. Tel.: +39 055 7947449; fax: +39 055 7947449.

E-mail address: g.alemannomd@gmail.com (G. Alemanno).

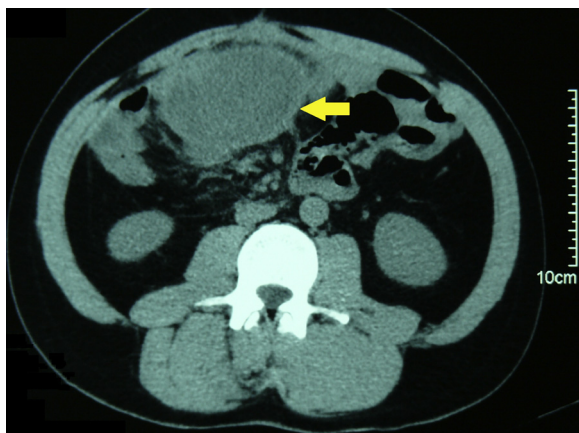


Fig. 1. Abdominal computed tomography showed a large mesenteric mass, extending 13 cm from the epigastrium to L3, with internal massive liquefaction.

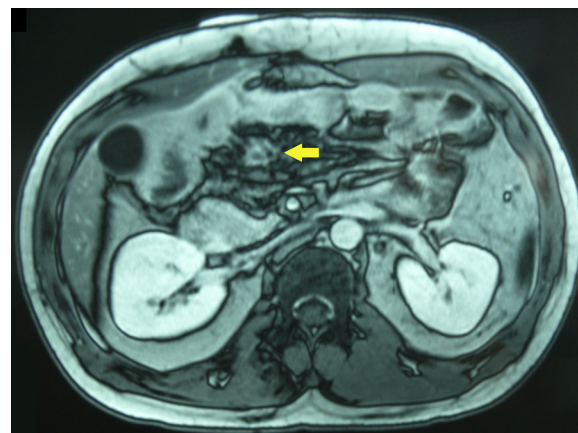

Fig. 2. Magnetic resonance imaging performed after CT-guided percutaneous drainage. The abdominal mass had a smaller diameter (2.5 cm).

were performed. After 3 month he underwent surgery for the closure of the stoma. Twelve months after surgery, in a time of good health conditions, there was an onset of abdominal swelling near the surgical scar closure of the stoma. Computed tomography (CT) showed thickening of the root of the mesentery. A 15-cm solid and dishomogeneous mass on the right wall of abdominal cavity appeared, stretching unto the pelvis, over the bladder and the right paracolic site. Exploratory laparotomy showed the mass to be composed by 2 separate units: the first occupying the entire wall from the right hip, under the skin, to the peritoneum; the second extended throughout the mesentery from Treitz ligament to the pelvis, and was surrounded by satellite nodules. Following anatomical consideration, we decided to perform a resection on the mass wall (9 cm × 7 cm × 5.5 cm), leaving the mesenteric mass in place, as it was impossible to preserve the vascularity of the bowel, and because of the considerable number of nodules. Histological examination was positive for abdominal fibromatosis. After surgery a medical therapy was administered, with Raloxifene for 3 months. The abdominal control CT showed no changes in the diameter of the abdominal mass; hence, the patient was treated with chemotherapy: Dacarbazine 150 mg/m²/day, 7 cycles for a total of 6 months. After chemotherapy the control CT showed a reduction in the diameter of the intra-abdominal mass (the pelvic region: 3 cm versus 5 cm; the cranial part: 6 cm versus 7.5 cm), with a more dishomogeneous aspect likely to overlap necrotic and regressive processes. The patient began therapy with Tamoxifen 40 mg and Meloxicam 7.5 mg and was followed-up for 3 years performing regular examinations and control X-rays every six months. Throughout that time, the size of the mass remained unchanged. Three month ago, he was hospitalized for abdominal pain, bowel obstruction and fever. An abdominal X-ray showed a slight overdistension of the ileal loops and small air–fluid levels. The CT scan showed a big dishomogeneous mass occupying the whole mesentery with internal massive liquefaction, and hyperemic and blurred bowel walls (Fig. 1). The mass extended from the epigastrium for 13 cm up to L3. On the right mesogastric side a solid, thick mass of about 2 cm, with a length of 4.5 cm, was identified; it

was not cleavable from the wall and from some of the loops. Consequently, the safest procedure was a CT- guided percutaneous drainage. Two hundred ml of purulent necrotic material was aspirated, and washing with antibiotic solution was carried out. Cytological examination of fluid drainage showed histiocytes and neutrophils. At follow-up, the patient’s clinical condition improved, and obstruction symptoms and fever regressed. An abdominal ultrasound showed a substantial reduction in the diameter of the mass (2.5 cm), subsequently confirmed by the MRI (Fig. 2). At discharge the patient continued treatment with Tamoxifen and Meloxicam.

3. Discussion

The etiology of DTs is still unclear. Extra-abdominal DTs are more frequent on the shoulders, the upper limbs and in the gluteal region; intra-abdominal DTs are located, in 85% of cases, in the mesentery.^{2,3} Consequently, they would be responsible for increasing morbidity and mortality rates in patients affected by FAP.^{4,5} Mesenteric desmoids originate as white plaques and progress to form a lobulated mass of considerable size.⁶ The abscess formation in desmoid tumors is a rare finding. Different interpretations of this phenomenon have been provided in literature, and the etiopathogenetic process is not yet completely clear. Some researchers have, however, hypothesized that surgical manipulation may contribute to the formation of an abscess due to transient bacteremia. Moreover, desmoid tumors compressing the vascular structures may lead to intestinal ischemia, with consequent bacterial transposition. Venous and lymphatic drainage of bacteria within intra-mesentery DTs, resulting in abscess formation,⁷ may be another possible triggering factor.

Only few reports of intra-abdominal DTs degenerated into abscess were reported in literature, as shown in Table 1.^{7–10} In the majority of cases the first approach to DTs complicated by abscess formation consisted of a percutaneous drainage plus antibiotic therapy. As a second approach, due to persistent symptoms

Table 1
Summary of reports of DTs complicated by abscess formation.

Report	Year	No. of patients	FAP related	1st treatment (no. of patients)	2nd treatment (no. of patients)
Maldjian et al. ⁷	1995	3	3	Percutaneous drainage (3) + antibiotics (3)	Surgical resection (2)
Cholongitas et al. ⁹	2006	1	None	Percutaneous drainage (1) + antibiotics (1)	Surgical resection (1)
Ebrahimi-Daryani et al. ¹⁰	2008	1	None	Antibiotics (1)	Surgical resection (1)
Peled et al. ⁸	2012	1	None	Antibiotics (1)	Surgical resection (1)

Download English Version:

<https://daneshyari.com/en/article/4289808>

Download Persian Version:

<https://daneshyari.com/article/4289808>

[Daneshyari.com](https://daneshyari.com)