



## Case Report

# Closure of leak at the tip of the “J” after ileal pouch-anal anastomosis using a novel over-the-scope clipping system



Lei Lian, Bo Shen\*

Digestive Disease Institute, The Cleveland Clinic Foundation, Cleveland, OH, USA

### ARTICLE INFO

#### Article history:

Received 6 November 2013

Accepted 13 December 2013

Available online 13 April 2014

#### Keywords:

Ileal pouch anal anastomosis

Leak

Clipping

Endoscopy

### ABSTRACT

**Objective:** leaks from the body or the tip of the J-pouch can occur after restorative proctocolectomy. Although it may follow an indolent clinical course, it often requires surgical repair or pouch revision. Here we describe a novel endoscopic approach to close the leak at the tip of the J pouch.

**Design:** pouchoscopy was performed under sedation and endoscopic over-the-scope clipping system was used for the management of a leak from the tip of a J-pouch.

**Results:** under sedation, a pouchoscopy was performed and the deep tip of “J” leak was detected with a guidewire, along with water-contrasted pouchogram. The contained cavity from the leak was cleaned with hydrogen peroxide and 50% dextrose. Debridement of the epithelialized mouth of the leak was performed with an endoscopic cytology brush. Then endoscopic over-the-scope clipping system was used and the leak defect was completely closed. There was no bleeding or perforation. The entire procedure took 25 min. The patient continued to do well and reported resolution of the low back pain symptom.

**Conclusion:** we reported the first case in the literature that a leak from the tip of a J-pouch was endoscopically occluded using a novel over-the-scope clipping system.

© 2014 Sociedade Brasileira de Coloproctologia. Published by Elsevier Editora Ltda.  
Este é um artigo Open Access sob a licença de [CC BY-NC-ND](#)

## Fechamento de vazamento na extremidade de bolsa ileal em J após anastomose bolsa ileal-anal usando um novo sistema “over-the-scope” clip (OTSC)

### R E S U M O

**Objetivo:** vazamentos do corpo da bolsa e da extremidade da bolsa ileal em J podem ocorrer após proctocolectomia restauradora. Embora possam apresentar um curso clínico indolente, muitas vezes requerem procedimentos abdominais.

**Desenho:** endoscopia da bolsa ileal foi realizada sob sedação e clipagem endoscópica usando o sistema “over-the-scope” foi utilizada para fechar um vazamento na extremidade da bolsa ileal em “J”.

#### Palavras-chave:

Anastomose Bolsa ileal-anal

Vazamento

Clip

Endoscopia

\* Corresponding author.

E-mail: [shenb@ccf.org](mailto:shenb@ccf.org) (B. Shen).

<http://dx.doi.org/10.1016/j.jcol.2014.03.003>

2237-9363/© 2014 Sociedade Brasileira de Coloproctologia. Published by Elsevier Editora Ltda.

Este é um artigo Open Access sob a licença de [CC BY-NC-ND](#)

**Resultados:** sob sedação, uma endoscopia de bolsa ileal foi realizada e a extremidade profunda do vazamento da bolsa ileal em “J” foi detectada com um fio-guia. A cavidade que continha o vazamento foi limpa com peróxido de hidrogênio e 50% de dextrose. Desbridamento da borda epitelizada do vazamento foi realizada com uma escova de citologia endoscópica. Então o sistema endoscópico “over-the-scope” clip foi usado e o vazamento foi completamente fechado. Não houve sangramento ou perfuração. O processo todo levou 25 minutos. O paciente evoluiu bem e relatou a resolução do sintoma de dor lombar.

**Conclusão:** relatamos o primeiro caso na literatura de vazamento na extremidade de bolsa ileal em J que foi fechado através de procedimento endoscópico usando um novo sistema “over-the-scope” clip (OTSC).

© 2014 Sociedade Brasileira de Coloproctologia. Publicado por Elsevier Editora Ltda.

Este é um artigo Open Access sob a licença de [CC BY-NC-ND](#)

## Introduction

The J pouch is preferred for an ileal pouch-anal anastomosis (IPAA) after total proctocolectomy (TPC)<sup>1</sup> over S or W pouch configuration, for ulcerative colitis (UC) or familial adenomatous polyposis, because of technical feasibility and the similar functional outcomes. The tip of the J-pouch consists of the disconnected end of the distal ileum which is usually closed with a linear stapler and sometimes additional reinforcement sutures.

The leak at the tip of the J-pouch (Fig. 1) is less often to occur than anastomotic leak. But leaks in the both sites are known to be associated with pouch failure.<sup>2</sup> In a previous study of 27 patients with pouch leak from the tip of the “J”, we found that predominant symptoms were abdominal pain and fever, and salvage surgery was required in up to 93% of the patients with pouch repair, new pouch creation, or redo anastomosis.<sup>3</sup> In this report, we describe a novel treatment of a leak from the tip of the J-pouch using an over-the-scope clipping system (or “Bear Claw”) that successfully occluded the leak at the tip of “J”.

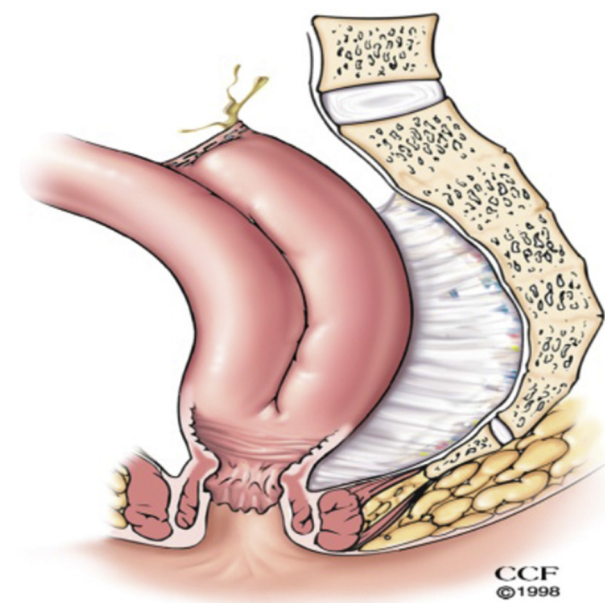


Fig. 1 – Leak at the tip of the J-pouch.

## Case report

A 58-year-old female was diagnosed with UC in 2000 and underwent 3-staged TPC and hand-sewn IPAA with mucosectomy in 2002 for medically refractory disease. Postoperatively the patient was complicated by perianal abscess which was successfully managed by drainage with incision and seton placement. During the follow up, she developed recurrent small bowel obstruction requiring hospitalization, bowel decompression, and intravenous fluid infusion. She was also diagnosed as having “trapped ovarian syndrome” with large cystic lesions after IPAA surgery, which was managed by CT-guided drainage.

The patient presented to our Center for Ileal Pouch Disorders in August 2012 with increased watery bowel movements (average of 12/day) and occasional nocturnal symptoms with mild incontinence. She also complained of intermittent low back pain. On physical examination the patient was afebrile. Pouch endoscopy showed a normal pouch body, inlet, and outlet, anal transitional zone, and afferent limb. However, an ulcerated lesion was found in the tip of the “J”. A leak from the tip of the “J” was suspected and confirmed with a soft guidewire via endoscopy operating channel. The leak from the tip of the “J” was further confirmed by pouchogram with contrasted watery soluble enema (Fig. 2). Treatment options were discussed including conservative management, major re-operative abdominal surgery, and endoscopic treatment. Risks and benefits of the endoscopic therapy were discussed with the patient and informed consent was obtained.

The patient was taken to the outpatient endoscopy suite. Under sedation, a pouchoscopy was performed with a GIF-1T gastroscope (Olympus, Tokyo, Japan). Carbon dioxide insufflation was used to reduce intraluminal gas. The afferent limb, pouch inlet, and proximal and mid pouch body, and anal transitional zone were normal. Again, the deep leak at the tip of “J” was detected (Fig. 3). We believed that this leak was the source of her low back pain. The contained cavity from the leak was cleaned with hydrogen peroxide and 50% dextrose. Endoscopic cytology brush was used to debride the epithelialized mouth of the leak cavity. Then 12-6t-sized over-the-scope clipping system (or “Bear Claw”) and OTSC Anchor 220tt (Ovesco Endoscopy USA, Campbell, CA) were used and the leak defect was completely closed (Fig. 4). There was no bleeding or

Download English Version:

<https://daneshyari.com/en/article/4297010>

Download Persian Version:

<https://daneshyari.com/article/4297010>

[Daneshyari.com](https://daneshyari.com)