

Endovascular repair of thoracic aortic injury after spinal instrumentation

Paul Claiborne, MD, Alexandros Mallios, MD, Kevin Taubman, MD, and John Blebea, MD, MBA,
Tulsa, Okla

Aortic injury after thoracic spinal instrumentation is a rare complication that carries significant potential morbidity and mortality if it is not appropriately managed. We report a patient successfully treated in an endovascular manner, thereby applying minimally invasive techniques to avoid the morbidity of open thoracotomy. Decreased short-term morbidity with the endovascular approach offers significant advantage over open repair, thereby omitting aortic cross-clamping, thoracotomy, and increased risk from the patient's comorbidities. An endovascular approach to this potentially devastating complication of thoracic spinal instrumentation can be both safe and effective in selected patients and not exclusively performed in cases of hemorrhage, hematoma, or pseudoaneurysm. (J Vasc Surg Cases 2015;1:264-7.)

Aortic injury after thoracic spinal instrumentation is a rare complication that carries significant potential morbidity and mortality if it is not appropriately managed. Interventions in the literature vary, specifically between endovascular and open repair. Many patients have delayed presentation and incidental discovery of the injury rather than acute hemorrhage. We present a case of descending thoracic aortic perforation resulting from posterior pedicle screw instrumentation and review the literature of both endovascular and open repair. The patient consented to use of case information and images for publication. To our knowledge, this study is the most comprehensive review of the literature including open and endovascular repairs from thoracic aortic injury due to spinal hardware as well as the indication for vascular repair.

CASE REPORT

A 65-year-old woman, suffering from severe thoracolumbar kyphoscoliosis causing intractable pain, required a spinal reconstruction involving a T2 to S1 posterior pedicle screw instrumentation. The procedure and postoperative course were uneventful. Fifteen months later, spine evaluation was performed for possible extension of spinal fixation in the cervical spine because of progressive pain and disability. A computed tomography (CT) scan revealed that one of the multiple previously placed pedicle screws

was possibly inside the proximal part of the descending thoracic aorta (Fig 1).

Because of the significant risk of hemorrhage or serious complication associated with removal of intraluminal hardware, we elected to perform a thoracic endovascular aortic repair immediately before the removal of the spinal instrumentation. The spine surgeon elected to remove only the offending hardware with replacement at a later time.

Under general anesthesia and with the patient in a supine position, a cutdown was performed for exposure of the left femoral artery that was used as an access vessel. Using oblique views with the vascular C-arm (Fig 2, A) and in combination with a view of the prior CT scan, we identified the offending pedicle screw at the T3 level. A Gore C-TAG 31 × 100 mm (W. L. Gore & Associates, Flagstaff, Ariz) was deployed in standard fashion through a 20F sheath using an Amplatz Super Stiff guidewire (Boston Scientific, Natick, Mass) after systemic heparinization. A proximal retrograde type B dissection was identified, and we decided to remove the offending screw because of the risk of stent perforation before further addressing the dissection. Subsequently, the patient was moved into the right lateral decubitus position while maintaining sterility; the pedicle screw was removed through a posterior longitudinal incision, and the skin was closed. The patient was placed back supine, and a proximal stent graft Gore C-TAG 34 × 100 mm was placed to correct the retrograde dissection. Completion angiography was satisfactory with good graft deployment and no evidence of extravasation (Fig 2, B). The patient's recovery was uneventful, and she was discharged 2 days after intervention. Subsequent CT angiography and physical examination were performed at 6 months and 1 year, showing recurrence of type B dissection without symptoms or graft complications.

METHODS

A MEDLINE/PubMed search was performed using the parameters of *spinal instrumentation and aortic injury, pedicle screw and aortic injury*. More than 150 publications were identified. Inclusion required injury of the thoracic aorta after spinal instrumentation. Excluded were abdominal aortic and iliac injuries, thoracic aortic injuries not due to previous spinal instrumentation, and placement of

From the Department of Surgery, University of Oklahoma-Tulsa School of Community Medicine.

Author conflict of interest: none.

Correspondence: Paul Claiborne, MD, Department of Surgery, University of Oklahoma-Tulsa School of Community Medicine, 1802 E 19th St, Kravis Building, Tulsa, OK 74104 (e-mail: paul-claiborne@ouhsc.edu).

The editors and reviewers of this article have no relevant financial relationships to disclose per the Journal policy that requires reviewers to decline review of any manuscript for which they may have a conflict of interest.

2352-667X

Copyright © 2015 The Authors. Published by Elsevier Inc. on behalf of the Society for Vascular Surgery. This is an open access article under the CC BY-NC-ND license (<http://creativecommons.org/licenses/by-nc-nd/4.0/>).

<http://dx.doi.org/10.1016/j.jvsc.2015.09.001>

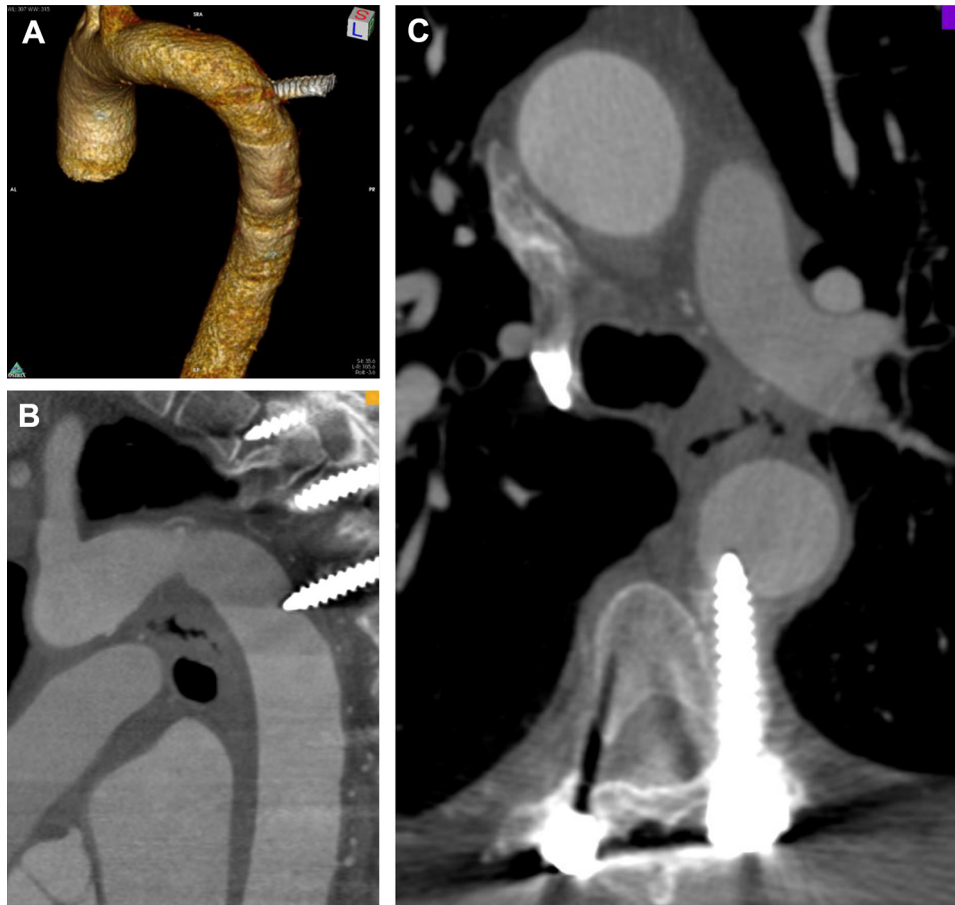


Fig 1. Three-dimensional reconstruction (A) of the aortic perforation at the level of the third thoracic vertebra. Sagittal (B) and transverse (C) views of the aortic injury on computed tomography (CT).

stent graft without identified injury.^{1,2} All articles not excluded were reviewed, and all cases were identified up to December 2013. All cases that met criteria were compared using parameters of level of spinal hardware, time to presentation for aortic injury, symptoms or lack thereof, open vs endovascular repair, and method of hardware removal or augmentation. A search of related articles and references was also performed on included articles.

RESULTS

Twenty-two publications were included describing 27 cases of aortic injury. There were 16 endovascular repairs reported and 9 open repairs. One patient died before repair could be attempted, and one patient underwent instrumentation removal without vascular intervention.³ Indications for removal due to pseudoaneurysm or hemorrhage accounted for only five of the identified cases. One patient had aortic repair without spinal instrumentation removal because of poor respiratory status without complication after 5 years of follow-up.⁴ Pain was the most common

symptom leading to aortic injury diagnosis, representing 11 of the 27 cases.

DISCUSSION

The presentation of and treatment approach for thoracic aortic injuries from spinal instrumentation vary substantially. Presentations ranged from acute hemorrhage to asymptomatic injury found on incidental or routine imaging. Whereas intervention in the symptomatic patient can clearly be justified, incidental aortic impingement without frank evidence of aortic injury represents a clinical challenge. From the reported cases, it seems clear that many aortic repairs are done without evidence of hemorrhage, hematoma, or pseudoaneurysm. As in our case, probable evidence of perforation on imaging has been used to justify repair with or without other symptoms. The significant risk of removing the hardware without repair of suspected injury presents a significant clinical and medicolegal dilemma. Pedrosa et al⁵ suggested the use of transesophageal echocardiography for evaluation of aortic integrity and injury. Intravascular ultrasound has

Download English Version:

<https://daneshyari.com/en/article/4305546>

Download Persian Version:

<https://daneshyari.com/article/4305546>

[Daneshyari.com](https://daneshyari.com)