

# Endograft limb trimming and resheathing can be an alternative for emergent aortic repair without adequate stent graft availability

Francisco Álvarez Marcos, MD, MSc, Delfín Couto Mallón, MD, Pilar Vilariño López-Barranco, MD, Jorge Vilariño Rico, MD, PhD, Francisco José Franco Meijide, MD, and Santiago Caciro Quinteiro, MD, Coruña, Spain

Endograft limb trimming can be an easy customization to perform in some emergent setups and when alternative adequate covered stents are lacking. A man aged 74 years presented with aortoenteric fistula and hemodynamic instability years after an aortobifemoral bypass, and a 56-year-old woman was admitted with acute ischemia due to an aortic ulcer-like lesion. In both cases, tabletop deployment and removal of two stents from an Endurant iliac limb (Medtronic, Fridley, Minn), followed by resheathing and deployment, allowed successful repair as a bridging therapy for open surgery. Both patients are alive and without walking impairment 8 and 6 months later, respectively. (J Vasc Surg Cases 2016;2:88-91.)

The spread of endovascular techniques entails the need of a vast armamentarium available for vascular surgeons worldwide. Proper planning should offer good performance and reliability for most cases,<sup>1</sup> although some situations require adaptive solutions because of the emergent need of repair, delay in the material's availability, or both. We present two cases in which a conventional endograft component (iliac limb) was customized for a rapid endovascular solution in the infrarenal aorta; both patients signed a dedicated consent form before this report.

## CASE REPORT

**Case 1.** A 74-year-old man was admitted to the emergency department with abdominal pain and hemodynamic instability, maintained with vasoactive drugs. The patient's comorbidities included Sjögren syndrome and autoimmune hepatitis. Previous abdominal interventions included an aortobifemoral bypass because of severe buttock claudication, a complicated appendectomy 3 years later, a reintervention due to adhesions, and an intestinal resection with colostomy, reconstructed a year later. On admission, the main diagnostic suspicion was an aortoenteric fistula, although computed tomography showed no active extravasation of contrast material (Fig 1).

From Complejo Hospitalario Universitario de A Coruña (CHUAC).  
Author conflict of interest: none.

Correspondence: Francisco Álvarez Marcos, MD, MSc, Servicio de Angiología y Cirugía Vascular, Complejo Hospitalario Universitario de A Coruña (CHUAC), 8ª planta As Xubias 84, 15006 A Coruña, Spain (e-mail: [francisco.alvarez.marcos@sergas.es](mailto:francisco.alvarez.marcos@sergas.es)).

The editors and reviewers of this article have no relevant financial relationships to disclose per the Journal policy that requires reviewers to decline review of any manuscript for which they may have a conflict of interest.

2468-4287

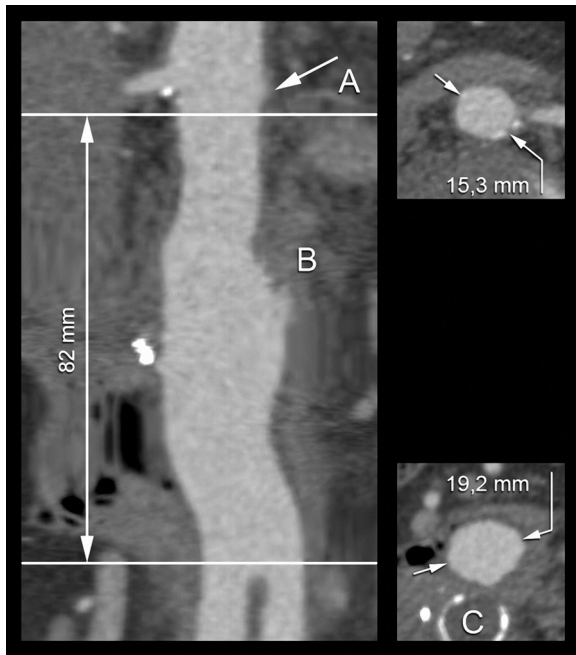
© 2016 The Author(s). Published by Elsevier Inc. on behalf of Society for Vascular Surgery. This is an open access article under the CC BY-NC-ND license (<http://creativecommons.org/licenses/by-nc-nd/4.0/>).

<http://dx.doi.org/10.1016/j.jvscit.2016.04.003>

The right limb of the previous aortobifemoral bypass was exposed and punctured, and above-renal angiography confirmed an 82-mm distance between the lowest renal artery and the bypass bifurcation. On the back table, a 93-mm Medtronic Endurant iliac extension (Medtronic, Fridley, Minn) was flushed and prepared in the conventional way (16-mm proximal and 20-mm distal diameters). While being held in place, the outer sheath was retracted and the two proximal stents were deployed, holding the third inside the delivery sheath (Fig 2). A scalpel was used to section the fabric between the second and the third nitinol stents, resulting in a length loss of 21 mm for a final customized graft length of 72 mm. The outer delivery sheath was replaced in its original position, and the iliac limb could be deployed under fluoroscopy without complications. The completion angiogram showed no active bleeding or endoleaks. The patient recovered with immediate hemodynamic stability, no further drop in serum hemoglobin level, and remarkable improvement in his abdominal pain.

Thirteen days after the procedure, the bifurcated graft was removed and replaced by a silver-coated Dacron graft. A full duodenectomy was performed, and the retroperitoneal area was secured with a vast omentoplasty. *Pseudomonas aeruginosa* and *Candida glabrata* were isolated in the microbiologic studies performed on the graft, and the correspondent antimicrobial therapy was administered. However, positron emission tomography performed 10 weeks after the reconstruction showed active leukocyte activity in the graft bifurcation, correlated with some collection-like images in the same area. Thus, in a new procedure, the silver-coated graft was explanted and an axillobifemoral bypass was performed, with good immediate results. The patient is active and walking 8 months after the first procedure, without fever or inflammatory symptoms.

**Case 2.** A 56-year-old woman previously observed at the clinic for stable bilateral buttock claudication was admitted with bilateral acute ischemia. A computed tomography scan identified an infrarenal ulcer-like aortic lesion, which conditioned a significant stenosis of the aorta at that level, in the context of a hypoplastic aortoiliac axis (Fig 3, A and B). Her comorbidities and risk



**Fig 1.** Centerline reconstruction and measures performed over computed tomography image showing the distance between the lowest renal artery (A) and the bifurcation of the previous Dacron graft, with identification of the possible bleeding point (B). The thrombosed and calcified native aortic axis is right below (C).

factors included mild smoking, insulin-dependent type 2 diabetes, and dyslipidemia.

After three-dimensional reconstruction and case planning, nondeferrable endovascular treatment was completed by trimming

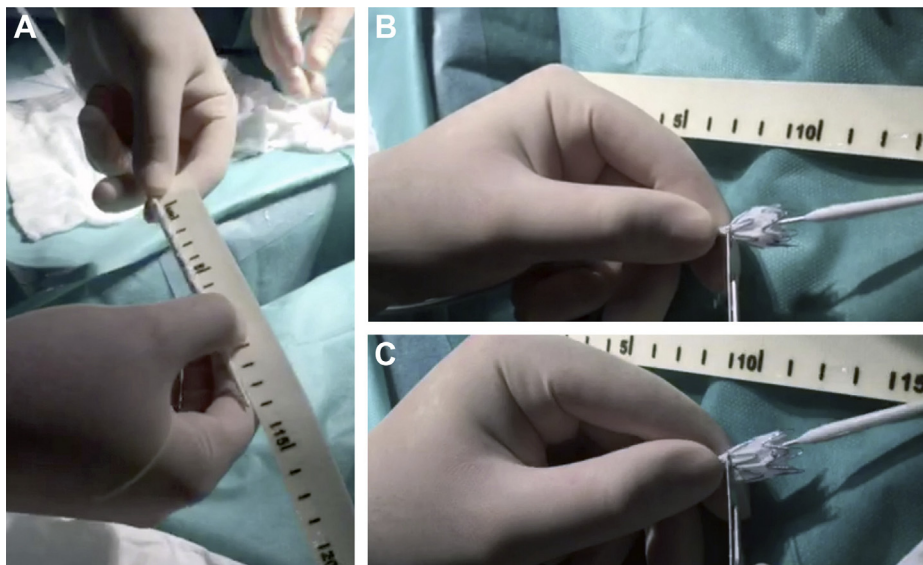
an 82-mm Medtronic Endurant iliac limb (13-mm proximal and 13-mm distal diameters). The centerline reconstruction and the subsequent angiographic confirmation indicated a distance of 68 mm from the lowest renal artery to the aortic bifurcation. Accordingly, the two proximal stents were removed in a way similar to the previously described case for an implant length of 61 mm (Fig 3, C and D). The patient recovered pedal pulses in the operating room and was discharged under antiplatelet therapy the day after.

Three months after the procedure, some degree of buttock claudication was reported at the follow-up visit, which correlated with bilateral common iliac stenosis in the imaging studies performed. To offer a long-lasting fix, the previous repair was explanted and an aortobifemoral Dacron bypass was performed, allowing the patient to have full recovery of both pedal pulses and no walking impairment 6 months after the surgery.

## DISCUSSION

Endograft customization with reshaping has been used as an alternative in select cases. Some authors have performed successful hand-made fenestrations over standard infrarenal endografts, mainly Zenith (Cook Medical, Bloomington, Ind)<sup>2-7</sup> and C3 (W. L. Gore & Associates, Flagstaff, Ariz) devices.<sup>8</sup> Others have transformed a bifurcated graft into a uni-iliac configuration<sup>9</sup> or reversed the disposition of an iliac limb to change it from a flared to a tapered configuration.<sup>10,11</sup> Some degree of parallelism with our technique can be found in the trimming of a Valiant graft (Medtronic) deployed in an acute ascending aortic penetrating ulcer, reported by Allen et al.<sup>12</sup>

The main justification for this technique is a combination of anatomic constraints, the lack of large enough covered stents, and the need of a quick repair. Both diameter and length boundaries were found in our cases. The



**Fig 2.** Back-table limb partial deployment and trimming. A, Desired length confirmation with a radiopaque ruler. B, The two proximal stents have been deployed while the third is still held in place by the outer delivery sheath. C, Fabric cut out right under the second nitinol stent.

Download English Version:

<https://daneshyari.com/en/article/4305646>

Download Persian Version:

<https://daneshyari.com/article/4305646>

[Daneshyari.com](https://daneshyari.com)