



## Dental diagnosis from X-Ray images: An expert system based on fuzzy computing

Le Hoang Son<sup>a,\*</sup>, Tran Manh Tuan<sup>b</sup>, Hamido Fujita<sup>c</sup>, Nilanjan Dey<sup>d</sup>, Amira S. Ashour<sup>e</sup>,  
Vo Truong Nhu Ngoc<sup>f</sup>, Le Quynh Anh<sup>f</sup>, Dinh-Toi Chu<sup>g,h</sup>

<sup>a</sup> VNU University of Science, Vietnam National University, Vietnam

<sup>b</sup> Thuy Loi University, Vietnam

<sup>c</sup> Iwate Prefectural University, Iwate, Japan

<sup>d</sup> Techno India College of Technology, Kolkata, India

<sup>e</sup> Faculty of Engineering, Tanta University, Egypt

<sup>f</sup> School of Odonto - Stomatology, Hanoi Medical University, Hanoi, Vietnam

<sup>g</sup> Institute for Research and Development, Duy Tan University, 03 Quang Trung, Danang, Vietnam

<sup>h</sup> Faculty of Biology, Hanoi National University of Education, Hanoi, Vietnam

### ARTICLE INFO

#### Article history:

Received 2 April 2017

Received in revised form 12 June 2017

Accepted 11 July 2017

Available online 6 August 2017

#### Keywords:

Dental X-Ray image

Decision making

Graph-based clustering

Medical diagnosis

Semi-Supervised fuzzy clustering

### ABSTRACT

**Background:** Computerized medical diagnosis systems from X-Ray images are of great interest to physicians for accurate decision making of possible diseases and treatments. Subclinical disease has no recognizable clinical findings, thus it is desirable to segment the dental X-Ray image into groups and then use soft computing methods to check the possibility of whether or not any disease occurs therein.

**Methods:** The current work proposed a novel framework called Dental Diagnosis System (DDS) for dental diagnosis based on the hybrid approach of segmentation, classification and decision making. It utilized the best dental image segmentation method based on semi-supervised fuzzy clustering for the segmentation task. A new graph-based clustering algorithm called APC+ for the classification task was proposed. A new decision making procedure was designed to determine the final disease from a group of diseases found from the segments.

**Results:** The proposed DDS was modeled under the real dental case of Hanoi Medical University, Vietnam including 87 dental images of five popular diseases, namely: root fracture, include teeth, decay, missing teeth, and resorption of periodontal bone. The DDS accuracy is 92.74% which is superior to the other methods namely fuzzy inference system (89.67%), fuzzy k-nearest neighbor (80.05%), prim spanning tree (58.46%), kruskal spanning tree (58.46%), and affinity propagation clustering (90.01%).

**Conclusion:** Empirical results established that superior performance of the DDS to other related methods the findings of the achieved results can assist dental clinicians in their professional work.

© 2017 Elsevier Ltd. All rights reserved.

## 1. Introduction

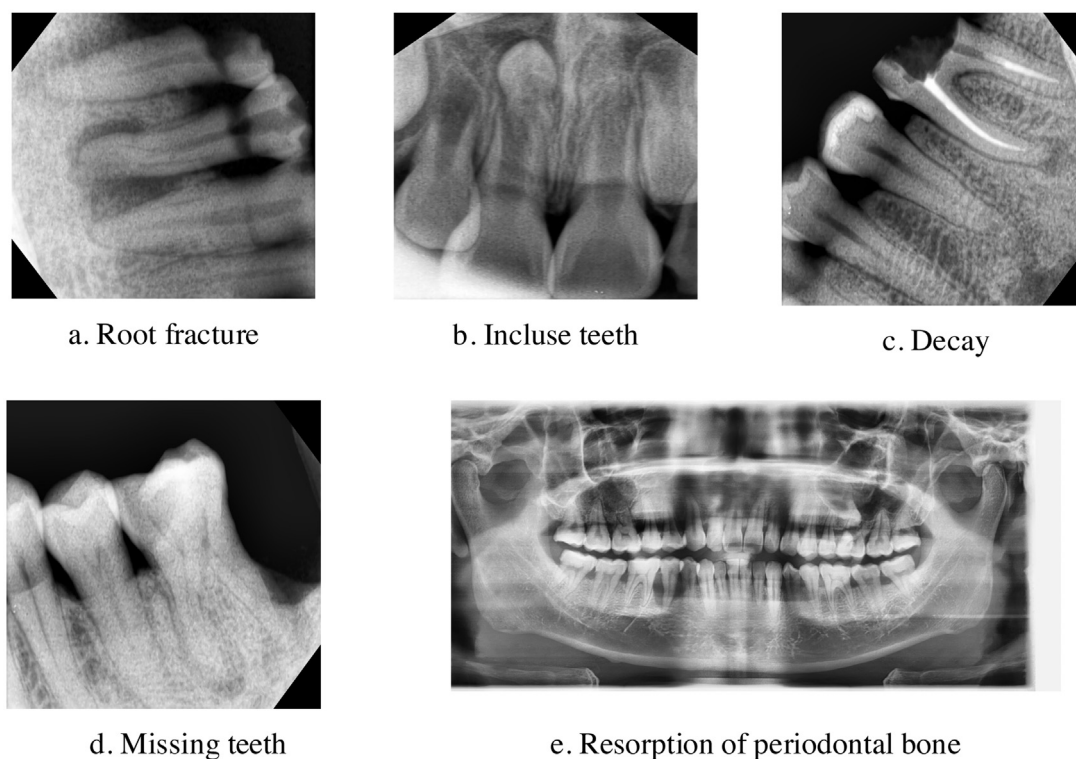
Dental X-ray images analysis and processing play a significant role for the dental diseases'/conditions' diagnosis, treatment, and studying the dental diseases nature as well as predicting dental diseases at their early stage [28,29]. Typically, dental X-rays represent pictures of the teeth, soft tissues, and bones for determining

\* Correspondence to: 334 Nguyen Trai, Thanh Xuan, Hanoi, Vietnam. Tel.: +84 904 171 284.

E-mail addresses: [sonlh@vnu.edu.vn](mailto:sonlh@vnu.edu.vn) (L.H. Son), [tuan.tm@tlu.edu.vn](mailto:tuan.tm@tlu.edu.vn) (T.M. Tuan), [HFujita-799@acm.org](mailto:HFujita-799@acm.org) (H. Fujita), [nilanjan.dey@tict.edu.in](mailto:nilanjan.dey@tict.edu.in) (N. Dey), [amirasashour@yahoo.com](mailto:amirasashour@yahoo.com) (A.S. Ashour), [nhungoc@hmu.edu.vn](mailto:nhungoc@hmu.edu.vn) (V.T.N. Ngoc), [lequynhanh@hmu.edu.vn](mailto:lequynhanh@hmu.edu.vn) (L.Q. Anh).

diseases/problems within the mouth, teeth, and jaw. It can display buried dental structures, cavities, and bone loss that visual examination cannot detect [31].

In dental diagnosis, fuzzy inference system (FIS) is one of the most common approaches for determining a projection from a given input data set to an output data set using fuzzy logic [18,33]. Besides, Chattopadhyay et al. [7,8] presented an application of Bayesian network to diagnose toothache. Kavitha et al. [23] used Support Vector Machine (SVM) to predict the osteoporosis from dental images. In 2014, Oad et al. [34] proposed a fuzzy-based method to predict heart risk. Ramírez, Castillo and Soria [40,41] used Fuzzy Neighbor K-Nearest Neighbor (FKNN) in different dentistry problems. Nevertheless, forming fuzzy rules and knowledge in those works requires experts' experience to avoid duplicate, con-



**Fig. 1.** Examples of dental X-ray images in each disease group: (a) Root fracture; (b) Include teeth; (c) Decay; (d) Missing teeth; (e) Resorption of periodontal bone.

flict and meaningless rules as well as guarantee accurate diagnosis [16]. Such problems can be solved using a combination of segmentation, classification and decision making algorithms, which can reduce the ambiguity and vagueness of determining the rules [11,37,38,42,45].

The first step of this process is to segment a dental X-Ray image into groups for further examination of whether or not any disease exists. Dental X-Ray image segmentation is applied to create several distinct groups in the image, whereas pixels in a group have more similarity than those in other groups [54]. This problem has been studied extensively in [2–4,9,15,20,26,27,32,35,39,49–52,55]. The typical approach- semi-supervised algorithm uses additional information, for example Bouchachia and Pedrycz [3] used the membership matrix in the semi-supervised fuzzy c-mean algorithm (SSFCMBP). Yasunori et al. [49] carried out semi-supervised algorithm with standard fuzzy clustering (SSFC) based on mixing the membership function into the entire clustering process. Yin et al. [51] proposed semi-supervised entropy regularized fuzzy clustering algorithm (eSFCM) that integrated the entropy factor into the semi-supervised clustering algorithm and used additional values to increase clustering performance. Portela et al. [36] proposed semi-supervised classifier based clustering algorithm for magnetic resonance brain tissue segmentation.

Then in the next steps, once having the segments, a classification algorithm in [5,7,10,20,22,23,40,47] can be used to match the segmented images with disease' patterns in the database to conclude whether the image is for 'disease' or 'non-disease'. Finally, a decision making algorithm is applied to determine the final disease image from segments.

In this paper, we propose a novel framework called Dental Diagnosis System (DDS) for dental diagnosis based on the hybrid approach of segmentation, classification and decision making. It utilizes the best dental image segmentation method based on semi-supervised fuzzy clustering for the segmentation task. A new graph-based clustering algorithm called APC+ for the classification

**Table 1**

Statistical information of the groups of patients.

Group	Sex		Age		
	Male	Female	16–22	23–30	31–38
Root fracture	8	8	0	5	11
Include teeth	9	10	5	6	8
Decay	9	8	8	3	6
Missing teeth	8	8	5	6	5
Resorption of periodontal bone	10	9	4	7	8
Sum	44	43	22	27	38

task was proposed. A new decision making procedure was designed to determine the final disease from a group of diseases found from the segments. In the dental professional view, the DDS was modeled under the real dental cases including real dental images of diseases' classes [19].

The structure of the remaining sections is as follows. Section 2 presents the materials and methods. Section 3 shows the experiment results and discussions about performance of methods with further studies. Conclusions are highlighted in Section 4.

## 2. Materials and methods

### 2.1. Dental images datasets

The proposed DDS was modeled under the real dental case of Hanoi Medical University, Vietnam including 87 dental images of five popular diseases in the period 2014–2015 [19]. The used dataset was collected from patients of age range from 16 to 38 and divided into 5 groups, namely: i) 16 with root fracture, ii) 19 with include teeth, iii) 17 with decay, iv) 16 with missing teeth, and v) 19 with resorption of periodontal bone as shown in Table 1. Those images taken by VATECH machine are both intraoral and panoramic in each group (Fig. 1). Panoramic radiography captures the entire

Download English Version:

<https://daneshyari.com/en/article/4973466>

Download Persian Version:

<https://daneshyari.com/article/4973466>

[Daneshyari.com](https://daneshyari.com)