



CASE REPORT

# Thrombosis of iliac vessels, a rare complication of endometriosis: Case report and review of literature



Rita Chiaramonte<sup>a,\*</sup>, Salvatore Castorina<sup>b</sup>, Emilio Giovanni Castorina<sup>c</sup>,  
Alessandra Panarello<sup>d</sup>, Salvatore Alessandro Maria Antoci<sup>d</sup>

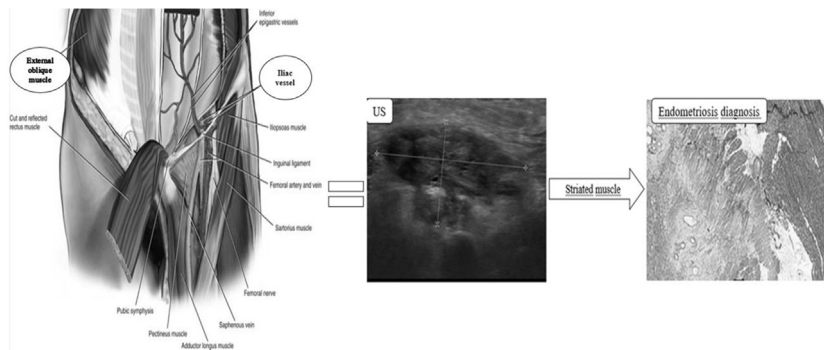
<sup>a</sup> Department of Physical Medicine and Rehabilitation, University of Catania, 95125 Catania, Italy

<sup>b</sup> Department of General Surgery of Fondazione Mediterranea “G.B. Morgagni”, 95100 Catania, Italy

<sup>c</sup> Department of Radiology of Fondazione Mediterranea “G.B. Morgagni”, 95100 Catania, Italy

<sup>d</sup> Department of Medicine of Fondazione Mediterranea “G.B. Morgagni”, 95100 Catania, Italy

GRAPHICAL ABSTRACT



ARTICLE INFO

Article history:

Received 7 August 2016

Received in revised form 23 October 2016

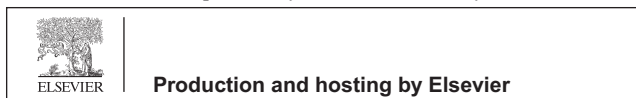
ABSTRACT

A young women presented with iliac vein thrombosis, as extrapelvic endometriosis complication. Endometriosis mass had a subfascial position at the level of external oblique muscle and extended to the iliac vein. This paper reviewed the literature on endometriosis cases localized into striated muscles and cases of deep vein thrombosis due to this disease. There are not similar cases in the literature. The diagnostic role of ultrasound, in obtaining the definitive

\* Corresponding author. Fax: +39 0957315384.

E-mail address: [ritachiamond@gmail.com](mailto:ritachiamond@gmail.com) (R. Chiaramonte).

Peer review under responsibility of Cairo University.



Accepted 24 October 2016  
Available online 1 November 2016

**Keywords:**

Endometriosis  
Ultrasonography  
Elasticity Imaging Techniques  
Thrombosis

histological diagnosis, may be further enhanced through Elasticity Imaging Techniques and ultrasound-guided biopsy.

© 2016 Production and hosting by Elsevier B.V. on behalf of Cairo University. This is an open access article under the CC BY-NC-ND license (<http://creativecommons.org/licenses/by-nc-nd/4.0/>).

## Introduction

Endometriosis is an estrogen-dependent inflammatory process. Cyclic hormonal changes produce different symptoms depending on the site of implantation. Pelvic endometriosis primarily affects ovaries, pelvic peritoneum, utero-sacral ligaments, Douglas pouch, vagina, rectum and bladder. But different rarer localizations are described. The history of present illness and an accurate assessment through Ultrasound (US) examination leads physician to a correct diagnosis, management and follow-up. But an extraperitoneal localization makes radiologic imaging diagnosis more difficult.

The aim of this study was to assess the precision of US scanning in identifying the specific features of endometriosis and its eventual associated complications. The study illustrated the precision and the appropriateness of ultrasound-guided biopsy in providing definitive histological diagnosis of this rare condition.

This paper reviewed endometriosis cases with regard to importance of US examination for the diagnosis of the disease localized into striated muscles and for the follow-up of deep vein thrombosis (DVT) as its complication. Cases of endometriosis localized in external oblique muscle and associated with DVT have not been previously reported in the literature.

## Case report

*All procedures performed in our study involving human participants were in accordance with the ethical standards of the institutional and/or national research committee and with the 1964 Helsinki declaration and its later amendments or comparable ethical standards. Informed consent was obtained from the participant included in the study.*

A 38-year-old white woman, with no previous pregnancies, presented to hospital for acute onset of right groin pain. She described her menses as painless and regular. She denied episodes of menorrhagia, metrorrhagia, dyspareunia, dysmenorrhea, abdominal and pelvic cramping.

The lower limb appeared swollen warm and with an erythematous skin rash. Pulses, sensation and strength were intact. The symptomatology did not seem associated with menstruation and the patient did not report similar previous events.

## Results

Ultrasound examination, using a convex multi-frequency probe with a range of 1.0–6.0 MHz, showed normal morphological structures of abdomen. A solid fusiform mass, with a

diameter of  $4.45 \times 2.18$  cm, was localized in the right inguinal region, near to the iliac vessels. The mass had a sub-fascial localization in the right external oblique muscle, adjacent to subcutaneous fat. It had an inhomogeneous echotexture with low level internal iso-hypochoic echoes, irregular borders, without an endometrioid aspect (Fig. 1a). It was very extensive and compressed the iliac vein, without evidence of DVT during the first evaluation. Doppler ultrasound showed a diffuse peripheral vascularization (Fig. 1b). The shear wave elastographic evaluation (Elasticity Imaging Techniques) showed a higher elasticity in the peripheral region of the lesion. The central part of the lesion presented a homogeneous blue color distribution, representing hard stiffness (Fig. 1c). Computed tomography, with intravenous contrast, revealed a 22 mm irregular thickening, with spiculated margins, located in the subfascial of external oblique muscle (Fig. 2a). It was thickened and inhomogeneous. Regional lymphadenopathy was present.

Differential diagnosis included hematoma, abscess, enlarged lymph node, desmoid tumor and malignant tumors such as malignant melanoma, sarcoma or metastatic carcinoma. Percutaneous biopsy, using a 16 gauge Tru-cut needle system, was performed under US guidance. Histopathological examination confirmed endometriosis nodule involving the muscular layer of the external oblique muscle.

The mass, for its dimension and position, obstructed the flow of blood circulation predisposing to DVT. Indeed, despite prompt treatment with anticoagulant therapy (enoxaparin 4000 IU once daily) and elastic stocking, after 3 days the clinical condition evolved into DVT of iliac vein (Fig. 2b). Therefore, a transcatheter thrombolysis to prevent post-thrombotic syndrome was performed and complete recanalization of the vessel was obtained in 24 h. Surgical resection of the mass was performed. The patient refused hormonal therapy, to preserve her reproductive capacity.

At 6-month follow-up the patient was pain free and showed substantial improvement in her ambulation and quality of life.

## Discussion

An extensive electronic search was performed in PubMed, Scopus, Web of Science and Google. Studies were considered eligible if they described the presence of endometriosis in the context of striated muscles.

Extrapelvic endometriosis is an uncommon condition but can involve nearly every organ, resulting in a wide range of clinical manifestations. The symptoms are often nonspecific and do not correlate with extent or severity of the disease [1–5]. The presented patient had a very rare localization of endometriosis and an uncommon complication, the

Download English Version:

<https://daneshyari.com/en/article/5022873>

Download Persian Version:

<https://daneshyari.com/article/5022873>

[Daneshyari.com](https://daneshyari.com)