

## CASE REPORT

# Accidental hanging among children and adults: A report of two cases and review of the literature



Y. Nouma <sup>\*</sup>, W. Ben Ammar, S. Bardaa, Z. Hammami, S. Maatoug

*Forensic Department, University Hospital Habib Bourguiba, Sfax, Tunisia*

Received 22 February 2015; revised 26 April 2015; accepted 5 July 2015

Available online 29 August 2015

### KEYWORDS

Accidental hanging;  
Asphyxia syndrome;  
Forensic autopsy

**Abstract** Accidental hanging is rare. The circumstances of death are sometimes so strange and bizarre. It represents a differential diagnosis with suicidal hanging and even criminal hanging. We report two cases of accidental hanging. The first one occurred with a 7-year-old girl playing with a curtain rope. The second with a thief who was found head-trapped between two bars of a metal outer-door. We summarize the findings of the death scene examination, the forensic autopsy and the world literature concerning death by accidental hanging.

© 2015 The International Association of Law and Forensic Sciences (IALFS). Production and hosting by Elsevier B.V. This is an open access article under the CC BY-NC-ND license (<http://creativecommons.org/licenses/by-nc-nd/4.0/>).

## 1. Introduction

Accidental hanging is rare, which leads to the difficulty of distinguishing its diagnosis from the diagnosis of suicidal and even criminal hanging. Accidental hangings have a common characteristic that causes death to unsuspecting victims. It concerns children as well as adults mainly in auto-erotic context. This study presents two unusual cases of death by accidental hanging that occurred to a child and an adult in different circumstances.

## 2. Case reports

### 2.1. Case 1

A seven-year-old girl was discovered by her mother suspended by a window-curtain rope usually used to play the swing. The

rope was fixed to a metal bar in the wall situated 2 m from the ground, it constitutes a simple loop and it does not contain a knot. The body was found in a sitting position with the feet touching the ground. The neck was caught in the loop and the suspension point rising to the left ear, tilting the head to the opposite side. The death occurred on the scene of the accident and the body was freed by the mother in the hope of saving her girl.

External examination showed that the deceased was 130 cm tall presenting an incomplete ligature mark of 0.2–0.6 cm wide, more marked on the anterior and right side of the neck (Figs. 1–3). No other traumatic lesion was noted, mainly defensive wounds. The autopsy revealed a marked asphyxia syndrome associated with small intramuscular haemorrhages on the right sternocleidomastoid muscle (Fig. 4), a small bruise on the posterior surface of the esophagus (Fig. 5) and a bruise at the posterior wall of the right common carotid artery, near the carotid sinus (Fig. 6).

The dissection of the right carotid artery did not reveal an intimal tear. No other cervical injuries were observed, especially in the laryngeal cartilage and the hyoid bone.

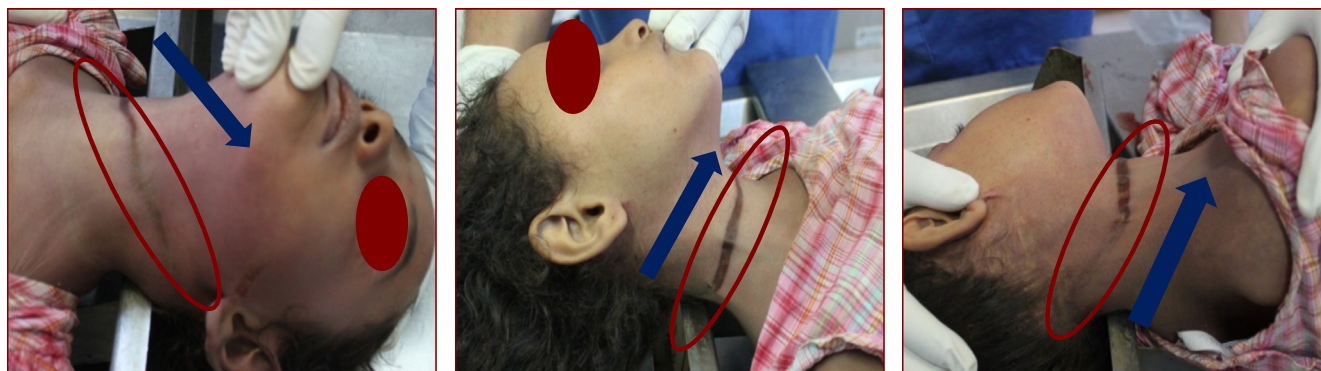<sup>\*</sup> Corresponding author.

E-mail address: [docyoussef@live.fr](mailto:docyoussef@live.fr) (Y. Nouma).

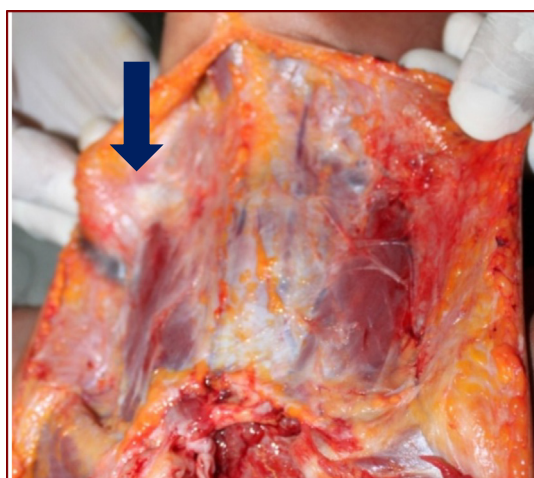
Peer review under responsibility of The International Association of Law and Forensic Sciences (IALFS).

<http://dx.doi.org/10.1016/j.ejfs.2015.07.001>

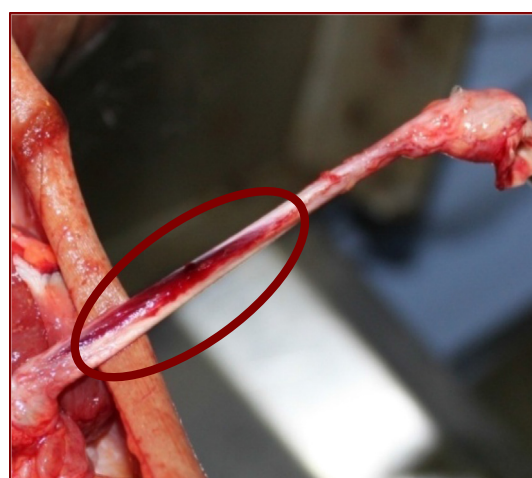
2090-536X © 2015 The International Association of Law and Forensic Sciences (IALFS). Production and hosting by Elsevier B.V. This is an open access article under the CC BY-NC-ND license (<http://creativecommons.org/licenses/by-nc-nd/4.0/>).



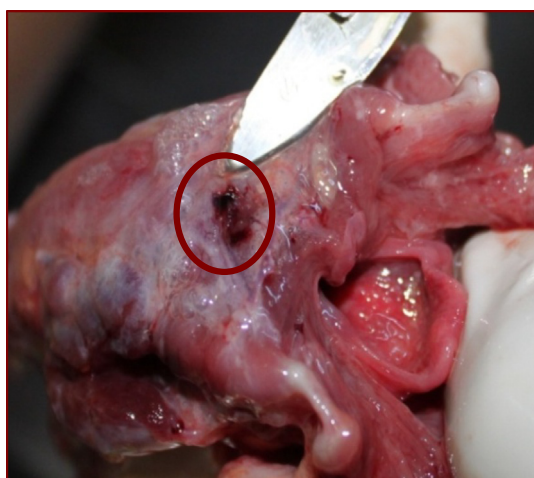
**Figures 1–3** The cervical ligature mark in case n°1.



**Figure 4** Intramuscular hemorrhage on the right anterior part of the sternocleidomastoid muscle in case n°1.



**Figure 6** Bruise at the posterior wall of the right common carotid artery near the carotid sinus in case n°1.



**Figure 5** Bruise in the posterior surface of the esophagus in case n°1.

## 2.2. Case 2

A thirty-five-year-old man, free from any psychiatric illness, was found suspended by head trapped between two bars of a metal outer-door (Fig. 7). He was a thief who attempted to



**Figure 7** The deceased's position in case n°2.

climb the door at the night. He was trapped, his head wedged between the bars and his feet are far from the ground. The extremities of the arrow-shaped metal bars did not let him remove his head. Over the time his neck became more and more compressed. The death occurred on the scene of the accident.

Download English Version:

<https://daneshyari.com/en/article/5123809>

Download Persian Version:

<https://daneshyari.com/article/5123809>

[Daneshyari.com](https://daneshyari.com)