



CASE REPORT

Percutaneous closure of iatrogenic femoral arteriovenous fistula using a covered coronary stent



Juan Carlos Rama-Merchan, Ignacio Cruz-González*, Javier Martín-Moreiras, Alejandro Diego-Nieto, Javier Rodríguez-Collado, Pedro Luis Sánchez

Department of Cardiology, University Hospital of Cardiology & IBSAL, Salamanca, Spain

Received 20 January 2016; accepted 12 May 2016
Available online 27 February 2017

KEYWORDS

Left atrial appendage;
Arteriovenous fistula;
Covered coronary stent

Abstract We present the case of a patient with a high-output fistula between the right superficial femoral artery and femoral vein after left atrial appendage closure successfully treated with a PK-Papyrus covered coronary stent using a 6F guiding catheter. To the best of our knowledge this is the first time a PK-Papyrus coronary stent has been used in this setting.
© 2017 Sociedade Portuguesa de Cardiologia. Published by Elsevier España, S.L.U. All rights reserved.

PALAVRAS-CHAVE

Apêndice atrial esquerdo;
Fístula arteriovenosa;
Stent coronário recoberto

Oclusão percutânea de fístula arteriovenosa femoral iatrogénica usando *stent* coronário recoberto

Resumo Apresentamos o caso de um paciente com uma fístula de alto débito entre a artéria femoral superficial direita e a veia femoral, depois de uma oclusão do apêndice atrial esquerdo, tratada com êxito com um *stent* coronário recoberto PK-PAPYRUS usando um cateter 6 F. Até onde sabemos, esta é a primeira vez que o PK-PAPYRUS é o usado neste contexto.
© 2017 Sociedade Portuguesa de Cardiologia. Publicado por Elsevier España, S.L.U. Todos os direitos reservados.

Introduction

Percutaneous left atrial appendage (LAA) closure devices have been developed as a non-pharmacologic alternative to oral anticoagulant (OAC) therapy for stroke prevention in patients with non-valvular atrial fibrillation (NVAF).¹ Vascular access site complications following percutaneous LAA

* Corresponding author.
E-mail address: cruzgonzalez.ignacio@gmail.com
(I. Cruz-González).

closure are infrequent,^{2,3} but may be associated with serious consequences.

We present the case of a patient with a high-output fistula between the right superficial femoral artery and femoral vein after LAA closure successfully treated with a PK-Papyrus covered coronary stent using a 6F guiding catheter.

Case report

An 86-year-old female patient with NVAF, high risk of stroke (CHA₂DS₂-VASC score of 5) and contraindication to OAC therapy (previous hemorrhagic stroke), underwent percutaneous closure of the LAA with an Amulet device (AGA/St. Jude Medical, Minneapolis, MN). The procedure was performed under general anesthesia, with fluoroscopic and two- and three-dimensional transthoracic echocardiographic guidance. The right femoral vein was cannulated using the Seldinger technique and a transseptal puncture was performed with a Mullins sheath and Brockenbrough needle. A 20 mm Amulet occluder device was successfully deployed (Figure 1).

At the end of the procedure after manual compression, prolonged pulsatile bleeding by the femoral venous access was observed. A control angiography obtained from the contralateral (left) femoral artery revealed a high-output fistula between the right superficial femoral artery and

femoral vein (Figure 2A). After discussion with the vascular team the decision was made to implant a covered stent. A 26 mm×4.5 mm PK-Papyrus covered coronary stent (Biotronik, Bülach, Switzerland) was inserted via the left femoral artery and deployed at the arteriovenous (AV) fistula using a 6F multipurpose catheter (Cordis Corporation) and a coronary guidewire (Balanced Heavyweight, Abbott Vascular Inc.). At final angiography, complete sealing of the AV fistula was documented (Figure 2B).

The patient was discharged after 48 hours without complications. Six months after the procedure, she was asymptomatic and Doppler ultrasonography of the right femoral segment was normal.

Discussion

Percutaneous LAA closure is a demonstrated alternative strategy to OAC therapy for stroke prophylaxis in patients with NVAF.¹ Vascular access site complications (perforations, pseudoaneurysms or AV fistulas) following percutaneous LAA closure are infrequent,^{2,3} but require immediate assessment and management and may be associated with adverse outcomes.

These vascular complications can be treated percutaneously using covered stents with high technical success, thus avoiding high-risk urgent vascular surgery.⁴⁻⁶ To the best of our knowledge this is the first time a PK-Papyrus coronary stent has been used in this setting.

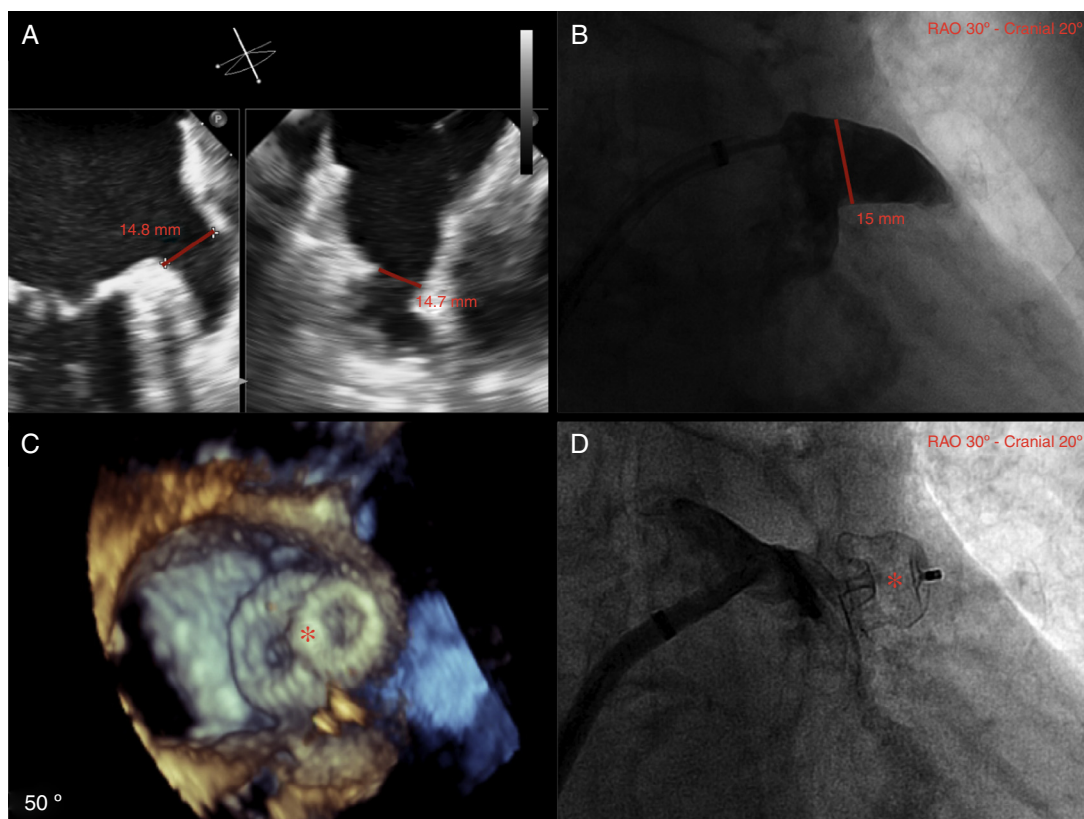


Figure 1 (A) Left atrial appendage (LAA) size by biplane two-dimensional transthoracic echocardiography (TEE); (B) LAA size by angiography (windsock morphology); (C) three-dimensional TEE showing complete occlusion of the LAA with the Amulet device (red asterisk); (D) angiography showing complete occlusion of the LAA with the Amulet device (red asterisk).

Download English Version:

<https://daneshyari.com/en/article/5126506>

Download Persian Version:

<https://daneshyari.com/article/5126506>

[Daneshyari.com](https://daneshyari.com)