




Ain Shams University  
The Egyptian Journal of Medical Human Genetics

www.ejmhg.eg.net  
www.sciencedirect.com



CASE REPORT

# Neurofibromatosis type 1 and multiple sclerosis: Genetically related diseases



Solaf M. Elsayed<sup>a,\*</sup>, Nagia Fahmy<sup>b</sup>, Radwa Gamal<sup>a</sup>, Mohamed Wafik<sup>a</sup>,  
Dina Zamzam<sup>b</sup>, Mai Fahmy<sup>b</sup>, Mahmoud Suelam<sup>b</sup>

<sup>a</sup> Genetics Unit, Children's Hospital, Ain Shams University, Egypt

<sup>b</sup> Neurology Department, Faculty of Medicine, Ain Shams University, Egypt

Received 24 June 2016; accepted 4 October 2016

Available online 25 October 2016

## KEYWORDS

Neurofibromatosis;  
Multiple sclerosis;  
Demyelinating disease;  
Autoimmune;  
Relapsing remitting;  
Myelin

**Abstract** Neurofibromatosis type I (NF1) is an autosomal dominant disorder with involvement of both the cutaneous and nervous systems. Patients are susceptible to neurological complication in the form of tumors of the brain and spinal cord. Multiple sclerosis (MS) is a chronic autoimmune disease that affects the myelinated axons in the central nervous system. Unlike MS, none of the neurological complications of NF1 is demyelinating. The association of these two diseases in the same patient is rare and could be genetically related. Early detection of the presence of MS in patients with NF1 is of utmost importance as treatment will certainly decrease further neurological disability. Here we report the first Egyptian lady with this association.

© 2016 Production and hosting by Elsevier B.V. on behalf of Ain Shams University. This is an open access article under the CC BY-NC-ND license (<http://creativecommons.org/licenses/by-nc-nd/4.0/>).

## 1. Introduction

Neurofibromatosis type I (NF1) is considered a neurocutaneous autosomal dominant disorder characterized by café-au-lait spots, eye Lisch nodules, and skin fibromatous tumors with increased susceptibility to tumor formation whether benign or malignant. The worldwide incidence of NF1 is 1 in 2500 to 1 in 3000 [1]. The prevalence in Egypt is unknown. Multiple sclerosis (MS), on the other hand, is an immune mediated inflammatory disorder causing progressive demyelination of the brain and spinal cord [2]. The association of these disorders is rare and exclusive and has been previously reported [3–13]. Although both diseases affect the neurological

system, only MS is potentially treatable and therefore early recognition of this association is of utmost importance.

## 2. Case presentation

We report a 32 year old female of healthy non consanguineous parents who presented to the genetics clinic because her son had multiple café au lait patches. Both (mother and son) were diagnosed with NF1 on the basis of the National Institutes of Health Diagnostic Criteria for NF1 [14]. The mother has multiple café au lait spots (more than 6) on various parts of her body, axillary freckling and multiple cutaneous neurofibromas all over her body while the child showed delayed speech, variable sized hyperpigmentation patches over all the body noticed since birth, the largest was over his abdomen.

Two years before presentation, the mother developed a sense of pins and needles in lower limbs up to her knees. It

\* Corresponding author at: Medical Genetics Center, 27 A Baghdad St., Korba, Cairo, Egypt. Fax: +20 224150977.

E-mail address: [elsayed683@yahoo.com](mailto:elsayed683@yahoo.com) (S.M. Elsayed).

Peer review under responsibility of Ain Shams University.

<http://dx.doi.org/10.1016/j.ejmhg.2016.10.001>

1110-8630 © 2016 Production and hosting by Elsevier B.V. on behalf of Ain Shams University.

This is an open access article under the CC BY-NC-ND license (<http://creativecommons.org/licenses/by-nc-nd/4.0/>).

started in the right side and progressed to the left side a few days later. This was associated with sense of swollenness as if walking on soft ground. She also reported difficulty in passing urine while the desire of micturition remained intact. She sought medical advice and over the counter drugs were prescribed to her (she could not remember their names) after which she felt a partial improvement. One and a half years later, she developed a sense of severe lancinating pain followed by a sense of pins and needles on her right side of the face including the tongue lasting for 1 h, then resolved spontaneously. This attack was repeated nearly three times in one month. Two months later, she developed swaying of gait with tendency to fall to either side not related to dim light. This was followed by bilateral lower limbs weakness left more than right, distal more than proximal with no change in tone but again she felt the pins and needles and as if she walked on soft ground. Few days later, she reported passing few drops of urine before reaching an appropriate place with no post voiding satisfaction. Through the past 6 months, she started to develop short term memory loss with intact long term memory. There was no other motor, sensory, cranial, or cerebellar affection.

On examination, the patient had multiple café au lait patches all over her body sparing the face, axillary freckling, and multiple cutaneous neurofibromas. She was fully conscious, oriented to time, place and person with intact recent and remote memory. She had fluent speech with no dysarthria or dysphasia.

Cranial nerve examination showed decreased visual acuity of the left eye counting fingers at 1 m, sluggish reactive left pupil to light. Left horizontal jerky nystagmus. No other cranial nerve affection. Motor power 5/5 bilateral normal tone, brisk deep tendon reflexes, bilateral extensor planter, lost abdominal reflexes with no muscle atrophy. Superficial sensation was lost till the level of thoracic vertebrae D7. Coordination tests were intact and she had normal gait.

Complete blood count (CBC) and erythrocyte sedimentation rate (ESR) were normal. Antinuclear antibodies test (ANA) and double stranded DNA were negative. Slit lamp showed Leish nodules while fundus examination and EEG were unremarkable. Electromyogram (EMG) and nerve conduction velocity (NCV) showed no abnormalities.

Auditory evoked potential revealed a right sided demyelinating lesion at the pontomesencephalic region while visual evoked potential revealed normal retino-cortical pathway. CSF analysis showed only albumin band with no detected oligoclonal band.

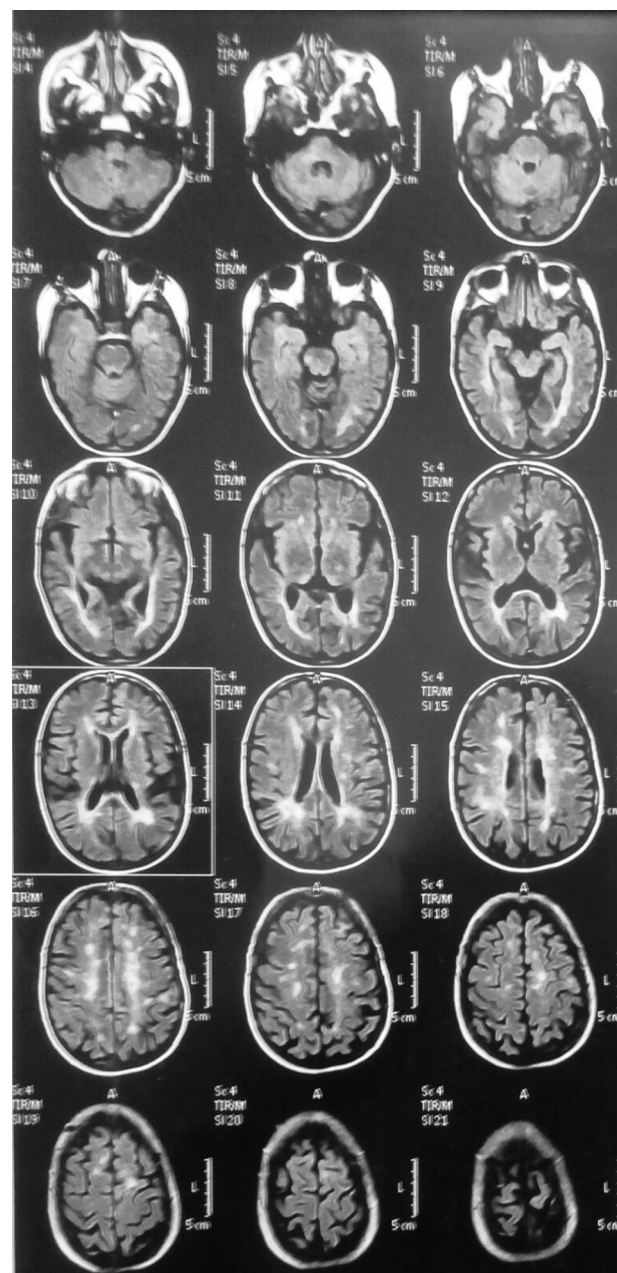
MRI brain exhibited multiple variable sized patchy areas of abnormal signal intensity in both periventricular regions, both centrum semi ovale, right middle cerebellar peduncle and right side of mid brain (Figs. 1 and 2). MRI of cervico dorsal spine revealed multiple patchy enhancing intra medullary abnormal signal along the whole cord, (Fig. 3).

Expanded Disability Status Scale assessment for MS [14] revealed the following: Visual: 3 (p) due to Leish nodules, Cerebral: 0, Cerebellar: 0, Pyramidal: 1, Brain stem: 1, Sensory: 2, Sphincter: 0, Ambulation: 0, Total: 2.5.

The patient received corticosteroids and had a good response regarding improvement of her symptoms after two months of treatment.

### 3. Discussion

Here we report the first Egyptian patient with both NF1 and MS. The diagnosis of NF1 was made according to the clinical



**Figure 1** MRI brain of patient showing multiple variable sized patchy areas of abnormal signal intensity that were seen in both periventricular regions, both centrum semi ovale, right middle cerebellar peduncle and right side of mid brain.

criteria suggested by the National Institutes of Health Consensus Development Conference on Neurofibromatosis [14] while the diagnosis of MS was based on both clinical and radiological findings [15,16]. Although NF1 complications involve primarily the neurological system (including tumors like gliomas and glioblastomas), none of these lesions has a demyelinating nature similar to what our patient experienced and so required further investigations one of which was the MRI brain which were highly suggestive of MS.

There are 4 types of MS: Relapsing-Remitting MS (RRMS) is the most common in which patients have alternating periods

Download English Version:

<https://daneshyari.com/en/article/5532096>

Download Persian Version:

<https://daneshyari.com/article/5532096>

[Daneshyari.com](https://daneshyari.com)