

UNUSUAL GROSS PRESENTATION OF SARCOCYSTIS-LIKE PECTORAL MUSCLE LYMPHOMA ATTRIBUTED TO MAREK'S DISEASE IN A BACKYARD CHICKEN

Carlos Daniel Gornatti Churria, Med Vet, Panayiotis Loukopoulos, DVM, PG Dip.V St, PhD, Javier Origlia, Med Vet, Nancy Arias, Med Vet, Miguel Herrero Loyola, Med Vet, and Miguel Piscopo, Med Vet

Abstract

Marek's disease-induced lymphomas of skeletal muscle are rarely reported in chickens. Three mixed-breed, adult backyard chickens, which belonged to a flock with a previous history of anorexia, depression, ruffled feathers, whitish diarrhea, weight loss and death, were submitted for *postmortem* examination and diagnostic testing. Grossly, 2 birds had moderate pectoral atrophy, whereas the remaining chicken had numerous white, rice-grain sized foci distributed throughout the pectoral musculature. Severe proventricular wall thickening was observed in all 3 chickens and moderate intestinal *Ascaridia* spp. parasitism was diagnosed in 2 of the birds. Microscopically, the peripheral nerves, cerebrum, proventriculus, and pectoral musculature were severely infiltrated by mononuclear pleomorphic cells. Formalin-fixed, paraffin-embedded tissues from all 3 chickens were polymerase chain reaction positive for Marek's disease virus. A diagnosis of Marek's disease was based on the combined necropsy, histopathology, and polymerase chain reaction findings. This article describes the unusual gross presentation of rice-grain sized and shaped lymphomas in the pectoral musculature of chickens caused by Marek's disease. Copyright 2017 Elsevier Inc. All rights reserved.

Key words: backyard chicken; lymphoma; Marek's disease; *Sarcocystis*-like lesions; pectoral musculature

Marek's disease (MD) is a common lymphoproliferative disease of chickens,^{1,2} which in the absence of preventive measures (e.g., vaccination) can cause high mortality and economic losses in both commercial² and backyard flocks.^{3,4} MD is caused by Gallid herpesvirus 2 (serotype 1), a member of the *Mardivirus* genus and *Alphaherpesvirinae* subfamily.⁵ Based on virulence, Marek's disease virus (MDV) is divided into 4 pathotypes: mild, virulent, very virulent, and very virulent plus strains.^{1,2,6} Often chickens infected with MDV develop characteristic peripheral nerve and visceral lymphomas that may affect a wide range of organs including the gonads, lung, heart, kidney, mesentery, liver, spleen, bursa of Fabricius, thymus, adrenal gland, pancreas, proventriculus, intestine, eye, skeletal muscle, and skin.¹ There is a paucity of information regarding skeletal muscle lymphomas associated with MDV infection in chickens, and all have described variably sized, whitish nodular lesions in the pectoral muscle of pure-breed chickens.⁷⁻⁹ This report describes pectoral muscle lymphomas caused by MDV, grossly mimicking *Sarcocystis*-like rice-grain sized skeletal muscle lesions in chickens.

From the *Cátedra de Patología de Aves y Pilíferos y Laboratorio de Diagnóstico de Enfermedades de las Aves y los Pilíferos, Facultad de Ciencias Veterinarias, Universidad Nacional de La Plata, La Plata, Provincia de Buenos Aires, Argentina; the Veterinary Diagnostic Laboratory, School of Animal and Veterinary Sciences, Charles Sturt University, Wagga Wagga, New South Wales, Australia; and the Graham Centre for Agricultural Innovation, Charles Sturt University, Wagga Wagga, New South Wales, Australia.*

Address correspondence to: Carlos Daniel Gornatti Churria, Med Vet, *Cátedra de Patología de Aves y Pilíferos y Laboratorio de Diagnóstico de Enfermedades de las Aves y los Pilíferos, Facultad de Ciencias Veterinarias, Universidad Nacional de La Plata, 60 y 118 s/n, CC 296, B1900AVW La Plata, Provincia de Buenos Aires, Argentina. E-mail: danielgornatti@fvc.unlp.edu.ar, danielgornatti@gmail.com*

© 2017 Elsevier Inc. All rights reserved.

1557-5063/17/2101-\$30.00

<http://dx.doi.org/10.1053/j.jepm.2016.10.007>

CASE REPORT

Three mixed-breed, adult backyard chickens (chickens 1, 2, and 3) from an MDV unvaccinated flock composed of 100 pure-breed and mixed-breed chickens of different ages were submitted to the Laboratorio de Diagnóstico de Enfermedades de las Aves y los Pilíferos (Cátedra de Patología de Aves y Pilíferos, Facultad de Ciencias Veterinarias, Universidad Nacional de La Plata) in June 2014 for *postmortem* examinations and diagnostic testing. Most of the affected juvenile and adult chickens of the backyard flock had exhibited anorexia, depression, ruffled feathers, whitish diarrhea, and cachexia; 46 chickens (~46%) died. No neurological signs were observed in the affected chickens and none had received therapeutic treatment.

When necropsied, moderate pectoral atrophy was noted in chickens 1 and 2, whereas chicken 3 had numerous well-demarcated, white, rice-grain sized and shaped foci distributed both on the surface and within the pectoral muscle (Figs. 1 and 2). The proventriculus was severely transmurally and circumferentially thickened, obliterating the lumen in all the 3 chickens. Moderate roundworm intestinal parasitism due to *Ascaridia* spp. was identified in chickens 1 and 3.

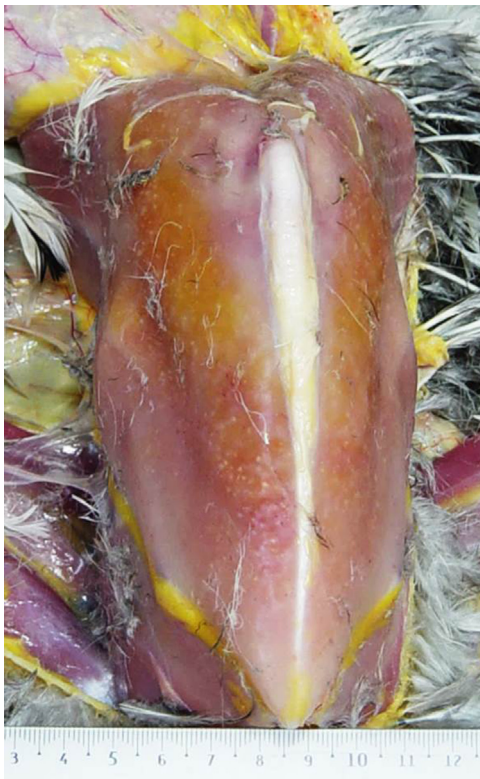

FIGURE 1. Mixed-breed, adult backyard chicken (chicken 3). Note numerous well-demarcated, white, rice-grain sized and shaped areas (lymphoma) on the surface of the pectoral muscle.

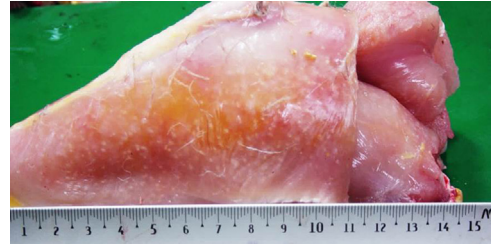


FIGURE 2. Mixed-breed, adult backyard chicken (chicken 3). Note numerous well-demarcated, white, rice-grain sized and shaped areas (lymphoma) on the surface of the pectoral muscle.

Samples of the brain, cervical vagus and sciatic peripheral nerves, lungs, heart, pectoral muscle, liver, spleen, kidneys, proventriculus, ventriculus, gonads, pancreas, and small and large intestine from all 3 chickens were fixed in 10% buffered formalin, pH 7.2, for 48 hours. All tissues were processed by standard histological techniques for the production of 4- μ m thick hematoxylin and eosin stained sections. Fresh samples of the liver and spleen of the 3 birds were inoculated onto MacConkey agar (Oxoid Ltd., Hampshire, UK) and sheep blood agar (Oxoid Ltd.) plates and incubated aerobically at 37°C for 24 hours. DNA was extracted from formalin-fixed, paraffin-embedded (FFPE) tissues of all birds by the use of a DNA commercial extraction kit (QIAamp DNA FFPE Tissue Kit, QIAGEN, GmbH, Hamburg, Germany) according to the manufacturer's instructions. Amplification and detection were carried out with an IQ5 Multicolor Real-Time PCR Detection System (Bio-Rad Laboratories, CA USA) by using SYBR Green (SYBR Green PCR Master Mix, Applied Biosystems, Life Technologies, CA USA) chemistry to detect the *meq* gene of the virus as described by Abdul-Careem et al.¹⁰ Intestinal contents of the 3 chickens were pooled and analyzed by a fecal floatation test.

RESULTS AND DISCUSSION

Microscopically, the pectoral musculature of chicken 3 showed multifocal to coalescing pleomorphic mononuclear cell infiltration (PMCI), which was prominent in several perivascular, primarily periarterial areas (Fig. 3). The PMCI is composed of variably sized large, neoplastic lymphocytes, including large blastic lymphocytes together with a small number of macrophages (Fig. 4). The infiltrating neoplastic lymphocytes were characterized by distinct cellular borders and rounded nuclei with dense chromatin surrounded by scarce cytoplasm (Fig. 4), and a low to moderate degree of necrosis and mitotic index.

Download English Version:

<https://daneshyari.com/en/article/5535758>

Download Persian Version:

<https://daneshyari.com/article/5535758>

[Daneshyari.com](https://daneshyari.com)