cor et vasa xxx (2016) e1–e4

Available online at www.sciencedirect.com
ScienceDirect
journal homepage: http://www.elsevier.com/locate/crvasa

Case report

Chondrosarcoma resection followed by a branched crural revascularization of the right calf: Case report

Róbert Novotný [a,*], *Jan LesensKy* [b], *Jan Hrubý* [a], *Jaroslav Hlubocký* [a], *Petr Mitáš* [a], *Jaroslav Lindner* [a]

[a] *2nd Department of Cardiovascular Surgery, General Teaching Hospital, Prague & 1st Faculty of Medicine, Charles University, Prague, Czech Republic*
[b] *Department of Orthopedic Surgery, Bulovka Hospital, Prague, Czech Republic*

ARTICLE INFO

Article history:
Received 31 January 2016
Accepted 6 February 2016
Available online xxx

Keywords:
Chondrosarcoma
Tibia
Resection
Arterial reconstruction
Branched bypass

ABSTRACT

Background: Chondrosarcoma is a malignant bone tumor accounting for 20% of all malignant bone malignancies. We are presenting a case of a lower extremity recurrence of chondrosarcoma that encapsulated the anterior tibial artery and the fibular artery in a 35-year-old Caucasian male patient. The patient underwent a primary resection of a chondrosarcoma of the right lower extremity 3 years ago. The patient underwent regular MRI and CT check-ups of the affected lower extremity. The patient reported a hard palpable mass with intermittent pain attacks and occasional limb swelling on his right calf 3 years from the initial surgery. A CT scan revealed a new tumor arising from the tibial bone in the place of the original tumor resection.

Case presentation: After a CT angiography revealed the tumor's anatomical localization to the surrounding structures, we performed a surgical resection of the entire tumor with a safe margin of soft tissue and encapsulated crural arteries. Extra attention was paid to the preservation of the tibial nerve. The resected crural arteries were replaced with a branched crural reconstruction (popliteal-fibular, anterior tibial bypass). Due to the young age of the patient, the great saphenous vein was the first choice as a graft for the vascular reconstruction. After the tumor resection, the patient was instantly relieved from intermittent pain attack and limb swellings. Based on the preoperative evaluation of the tumor and its surrounding structures, the patient underwent a complete tumor resection with crural arteries reconstruction after which the patient retained full limb functionality. The branched crural arteries reconstruction that replaced the resected crural arteries remains patent up-to-date with no signs of stenosis, when checked by Doppler ultrasonography.

Conclusion: Wide resection is the only adequate surgical treatment of choice and has to be planned carefully.

* *Corresponding author at*: 2nd Department of Cardiovascular Surgery, General Teaching Hospital, Prague, U nemocnice 2, 128 08 Prague 2, Czech Republic. Tel.: +420 773 679 206.
E-mail address: novotny_robert@hotmail.com (R. Novotný).
http://dx.doi.org/10.1016/j.crvasa.2016.02.005

Introduction

Chondrosarcoma is the second most common primary malignancy of a bone [1]. Chondrosarcomas conglomerate a heterogeneous group of neoplasms producing the cartilage matrix [2].

Based on the etiopathogenesis we can differentiate primary chondrosarcomas (CHSs) and much more common secondary CHSs arising from previously benign chondomatous tumors. Depending on the location, we can further distinguish CHS "central" (originating from enchondroma) or "peripheral" (originating from osteochondroma) chondrosarcomas. From a histopathological point of view chondrosarcomas are a heterogeneous group with a large variety of biological behaviors. "Conventional" CHSs are classified into three grades. A GI CHS is often difficult to distinguish from other benign cartilaginous tumors and has a fairly benign course; therefore, it has been renamed to "atypical chondromatous tumor". On the other hand, GII and GIII CHSs are highly malignant tumors with a potentially fatal course. The metastasizing process is often late, but it is typical that these tumors do not show sensitivity to chemotherapy nor radiotherapy. Therefore, these tumors are invariably fatal in generalized state [3,4]. Besides "conventional" chondrosarcoma, there are some less frequent variants such as clear-cell CHSs, mesenchymal CHSs and dedifferentiated CHSs, which all have very unique biological behavior and pathogenesis. Currently, the only effective therapy is a surgical excision, which can be problematic in large tumors, tumors with sensitive surrounding structures, or when a significant loss of limb functionality is anticipated [3].

In this case report, we are presenting a lower extremity reoperation for a local recurrence of a chondrosarcoma that encapsulated crural arteries. Based on the preoperative evaluation of the tumor and its surrounding structures, the patient underwent a wide tumor resection with crural arteries reconstruction after which the patient retained full limb functionality.

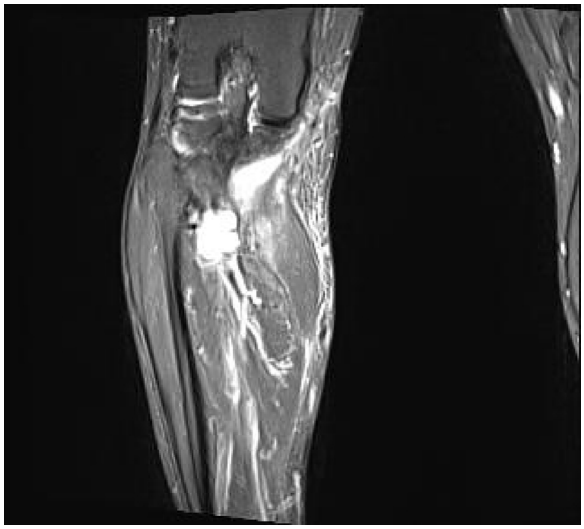

Fig. 1 – Longitudinal cross section of the right calf with tumor infiltration of crural arteries.

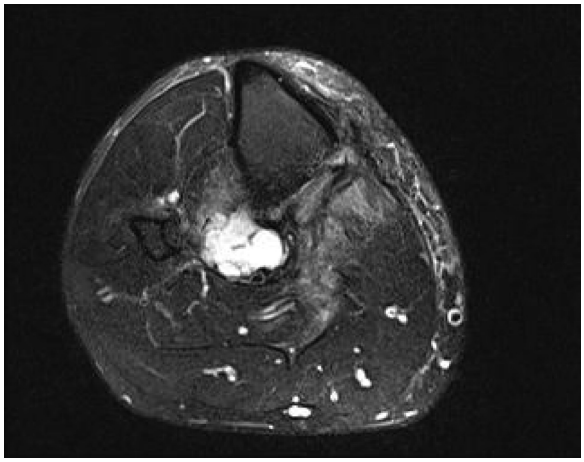

Fig. 2 – Cross section of the right calf: tumors anatomical localization to the surrounding structures.

Case presentation

We are presenting a case of a 35-year-old Caucasian male patient with reoccurrence of tibial chondrosarcoma of the right lower extremity diagnosed and resected 3 years ago by an orthopedic surgeon at a different medical center. Besides the tumor, the patient's medical history was negative for any medical conditions. The patient was undergoing periodic MRI and CT check-ups after the initial surgery. The patient started to notice occasional limb swelling, intermittent pain and a hard palpable mass on the right calf prior to the last check-up. Physical examination of the patient confirmed swelling and a palpable mass on the right calf. CT-angiography was indicated and confirmed a tumor localization just under the tuberosity of tibia with the anterior border reaching the tibialis anterior muscle, the posterior border reaching the tibialis posterior muscle, the later border formed by the tibia, and the medial border formed by the fibula. The tumor's size based on the CT examination was 8 cm × 4 cm × 5 cm (Figs. 1 and 2). In addition, the CT-angiography revealed the encapsulation of the anterior tibial artery and the fibular artery by the tumor. One week after hospitalization the patient was treated with malawer limb salvage surgery under general anesthesia. Due to the encapsulation of crural arteries, an orthopedic surgeon with the cooperation of a vascular surgeon performed the tumor resection. The great saphenous vein from the thigh of the contralateral extremity was harvested as a suitable vascular graft for the resected crural arteries. After the graft harvest, a 35 cm longitudinal incision on the right calf was performed. The gastrocnemius muscle and soleus muscle were dissected in order to gain access to the tumor. The tumor was widely adherent to the surrounding structures. The tibialis anterior muscle, tibialis posterior muscle, and the tibia were partially resected based on the principle of wide resection. The tibial nerve was carefully dissected and preserved (Fig. 3). The tumor was extirpated together with