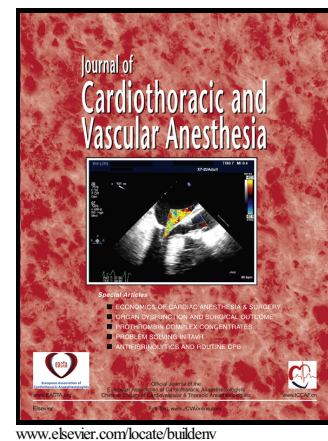


# Author's Accepted Manuscript

## Left Pulmonary Artery Stenting Causing Ipsilateral Pulmonary Complication

Madan Mohan Maddali, Sandip Waman Junghare, Kamalakannan Nadarajan, Pranav Subbaraya Kandachar, Salim Nasser Al-Maskari, John Valliattu



PII: S1053-0770(16)30138-0  
DOI: <http://dx.doi.org/10.1053/j.jvca.2016.05.016>  
Reference: YJCAN3687

To appear in: *Journal of Cardiothoracic and Vascular Anesthesia*

Received date: 1 May 2016

Cite this article as: Madan Mohan Maddali, Sandip Waman Junghare, Kamalakannan Nadarajan, Pranav Subbaraya Kandachar, Salim Nasser Al-Maskari and John Valliattu, Left Pulmonary Artery Stenting Causing Ipsilateral Pulmonary Complication, *Journal of Cardiothoracic and Vascular Anesthesia*, <http://dx.doi.org/10.1053/j.jvca.2016.05.016>

This is a PDF file of an unedited manuscript that has been accepted for publication. As a service to our customers we are providing this early version of the manuscript. The manuscript will undergo copyediting, typesetting, and review of the resulting galley proof before it is published in its final citable form. Please note that during the production process errors may be discovered which could affect the content, and all legal disclaimers that apply to the journal pertain.

**Left Pulmonary Artery Stenting Causing Ipsilateral Pulmonary Complication****[Running title: bronchial compression, pulmonary artery stent]****By**

Dr. Madan Mohan Maddali, MD  
 Senior Consultant,  
 Department of Cardiac Anesthesia,  
 National Heart Center  
 Royal Hospital, Muscat, Oman.

**&**

Dr. Sandip Waman Junghare, M.D.  
 Specialist in Cardiac Anesthesia,  
 National Heart Center  
 Royal Hospital, Muscat, Sultanate of Oman

**&**

Dr. Kamalakannan Nadarajan, MD.  
 Specialist in Cardiac Anesthesia  
 National Heart Center  
 Royal Hospital, Muscat, Oman

**&**

Dr. Pranav Subbaraya Kandachar, MCh  
 Senior Specialist in Cardiothoracic surgery,  
 National Heart Center  
 Royal Hospital, Muscat, Oman

**&**

Dr Salim Nasser Al-Maskari, FRCPC  
 Senior Consultant in Pediatric Cardiology,  
 National Heart Center,  
 Royal Hospital, Muscat, Oman  
 Sultanate of Oman

**&**

Dr. John Valliattu, FRCS  
 Senior Consultant in Cardiothoracic surgery,  
 National Heart Center,  
 Royal Hospital, Muscat, Oman

**Work attribution:** Departments of Cardiac Anesthesia and Cardiothoracic Surgery, National Heart Center, Royal Hospital, Muscat, Sultanate of Oman.

**Declaration:** The authors affirm that no potential conflict of interests exist and there was no funding

**Address for correspondence:**

Dr. Madan Mohan Maddali,  
 Senior Consultant in Cardiac Anesthesia,  
 National Heart Center, Royal Hospital,  
 P.B.No: 1331, P.C: 111,  
 Seeb, Muscat, Sultanate of Oman.  
 Mobile: 00 968 99437287; e-mail: madanmaddali@hotmail.com

Download English Version:

<https://daneshyari.com/en/article/5582389>

Download Persian Version:

<https://daneshyari.com/article/5582389>

[Daneshyari.com](https://daneshyari.com)