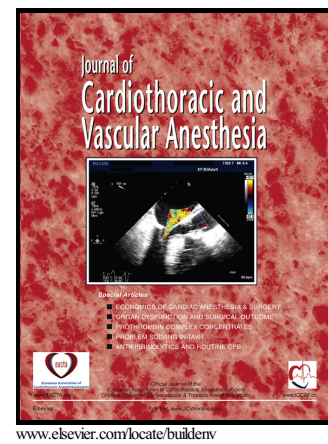


Follow-up Electrocardiograms in a Patient with
Incarcerated Bowel-Triggered Takotsubo
Syndrome Complicated by Cardiogenic Shock

John E. Madias



PII: S1053-0770(16)30433-5
DOI: <http://dx.doi.org/10.1053/j.jvca.2016.09.025>
Reference: YJCAN3851

To appear in: *Journal of Cardiothoracic and Vascular Anesthesia*

Cite this article as: John E. Madias, Follow-up Electrocardiograms in a Patient with Incarcerated Bowel-Triggered Takotsubo Syndrome Complicated by Cardiogenic Shock, *Journal of Cardiothoracic and Vascular Anesthesia*, <http://dx.doi.org/10.1053/j.jvca.2016.09.025>

This is a PDF file of an unedited manuscript that has been accepted for publication. As a service to our customers we are providing this early version of the manuscript. The manuscript will undergo copyediting, typesetting, and review of the resulting galley proof before it is published in its final citable form. Please note that during the production process errors may be discovered which could affect the content, and all legal disclaimers that apply to the journal pertain.

Follow-up Electrocardiograms in a Patient with Incarcerated Bowel-Triggered Takotsubo Syndrome Complicated by Cardiogenic Shock

John E. Madias, MD, FACC, FAHA

Running Title: Electrocardiogram and takotsubo syndrome

From the Icahn School of Medicine at Mount Sinai, New York, NY, and the Division of Cardiology, Elmhurst Hospital Center, Elmhurst, NY

Correspondence to John E. Madias, MD,

Division of Cardiology, Elmhurst Hospital Center,

79-01 Broadway, Elmhurst, NY 11373,

Tel: (718) 334-5005; Fax: (718) 334-5990;

e-mail: madiasj@nychhc.org

Conflicts of interest

None.

Acknowledgements

No funding has been received for this work.

Download English Version:

<https://daneshyari.com/en/article/5582475>

Download Persian Version:

<https://daneshyari.com/article/5582475>

[Daneshyari.com](https://daneshyari.com)