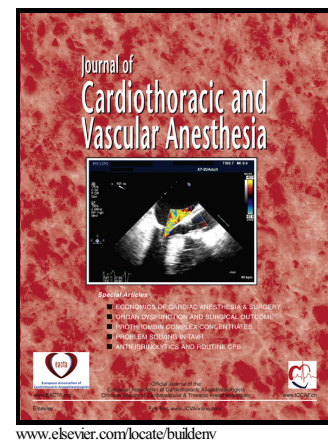


# Author's Accepted Manuscript

Response: Electrocardiographic markers in patients with takotsubo cardiomyopathy

Robert J.H. Miller, Eric Campbell, Alex Gregory, Sarah G. Weeks



PII: S1053-0770(16)30431-1  
DOI: <http://dx.doi.org/10.1053/j.jvca.2016.09.023>  
Reference: YJCAN3849

To appear in: *Journal of Cardiothoracic and Vascular Anesthesia*

Cite this article as: Robert J.H. Miller, Eric Campbell, Alex Gregory and Sarah G. Weeks, Response: Electrocardiographic markers in patients with takotsubo cardiomyopathy, *Journal of Cardiothoracic and Vascular Anesthesia*, <http://dx.doi.org/10.1053/j.jvca.2016.09.023>

This is a PDF file of an unedited manuscript that has been accepted for publication. As a service to our customers we are providing this early version of the manuscript. The manuscript will undergo copyediting, typesetting, and review of the resulting galley proof before it is published in its final citable form. Please note that during the production process errors may be discovered which could affect the content, and all legal disclaimers that apply to the journal pertain.

## Response: Electrocardiographic Markers in Patients with Takotsubo Cardiomyopathy

Robert J H Miller MD<sup>a</sup>, Eric Campbell BSc<sup>b</sup>, Alex Gregory MD<sup>c</sup>, Sarah G Weeks MD<sup>d\*</sup>

### Address:

- a. University of Calgary, Department of Cardiac Sciences. Libin Cardiovascular Institute of Alberta. C818, 1403 29 Street NW, Calgary, Alberta, Canada, T2N 2T9.
- b. University of Calgary, Department of Medicine. G701, 3330 Hospital Drive NW, Calgary, Alberta, Canada, T2N 4N1
- c. University of Calgary, Department of Anesthesiology. 1403 29 Street NW, Calgary, Alberta, Canada, T2N 2T9.
- d. University of Calgary, Department of Cardiac Sciences. Libin Cardiovascular Institute of Alberta. C854, 1403 29 Street NW, Calgary, Alberta, Canada, T2N 2T9.

**Email:** robert.miller@albertahealthservices.ca; ejcampbe@ucalgary.ca;  
alexander.gregory@albertahealthservices.ca; sgweeks@ucalgary.ca

Conflicts of Interest: None

Corresponding Author:  
Dr. Sarah Weeks  
1-403-944-2480  
C854, 1403 29 Street NW  
Calgary, Alberta, Canada  
T2N 2T9

Dear Editor:

We thank Dr. Madias for his inquiry regarding our manuscript. As he noted, our case demonstrates many of the dynamic electrocardiographic (ECG) changes commonly seen in patients with Takotsubo Cardiomyopathy (TCM).<sup>1,2</sup> The admission ECG, Figure 1A, shows anterior ST-segment elevation and low-voltage QRS complexes in the limb leads and lead V6. There was minor progression in QRS voltages at 24 and 48 hours, panels B and C, with normal

Download English Version:

<https://daneshyari.com/en/article/5582476>

Download Persian Version:

<https://daneshyari.com/article/5582476>

[Daneshyari.com](https://daneshyari.com)