

Available online at [www.sciencedirect.com](http://www.sciencedirect.com)

ScienceDirect

journal homepage: [www.elsevier.com/locate/ihj](http://www.elsevier.com/locate/ihj)

## Case Report

# High degree atrioventricular block with ventricular asystole in a case of dengue fever

Anender Kaur Dhariwal<sup>a,\*</sup>, Prakash S. Sanzgiri<sup>b</sup>, Vasant Nagvekar<sup>c</sup>

<sup>a</sup>DNB Cardiology Trainee, Lilavati Hospital & Research Centre, Bandra, Mumbai, India

<sup>b</sup>Consultant Cardiologist, Lilavati Hospital & Research Centre, Bandra, Mumbai, India

<sup>c</sup>Consultant Infectious Diseases, Lilavati Hospital & Research Centre, Bandra, Mumbai, India

## ARTICLE INFO

## Article history:

Received 14 December 2015

Accepted 22 March 2016

Available online xxx

## Keywords:

Atrioventricular block

Dengue

Asystole

Bradyarrhythmias

## ABSTRACT

Cardiac rhythm abnormalities have been uncommonly observed in dengue fever and most of them have been reported in children. We discuss a 30-year-old female with dengue fever, who presented with repeated symptomatic episodes of high degree atrioventricular block with ventricular asystole, which responded to intravenous atropine and oral orciprenaline without recurrence on 6 months follow-up.

© 2016 Cardiological Society of India. Published by Elsevier, a division of Reed Elsevier India, Pvt. Ltd. This is an open access article under the CC BY-NC-ND license (<http://creativecommons.org/licenses/by-nc-nd/4.0/>).

## 1. Introduction

Dengue fever is an important emerging infectious disease, especially in South-East Asia region. Though shock and intravascular hypovolemia is the most documented cardiovascular complication associated with dengue, various specific cardiac manifestations such as myocarditis, myocardial dysfunction, and arrhythmias have also been less commonly described.<sup>1</sup> Majority of the cardiac rhythm abnormalities in dengue fever have been reported in children with only a few recent case reports from adults.<sup>2-5</sup> We report a case of transient symptomatic episodes of high degree atrioventricular (AV) block with ventricular asystole in an adult with dengue fever.

## 2. Case report

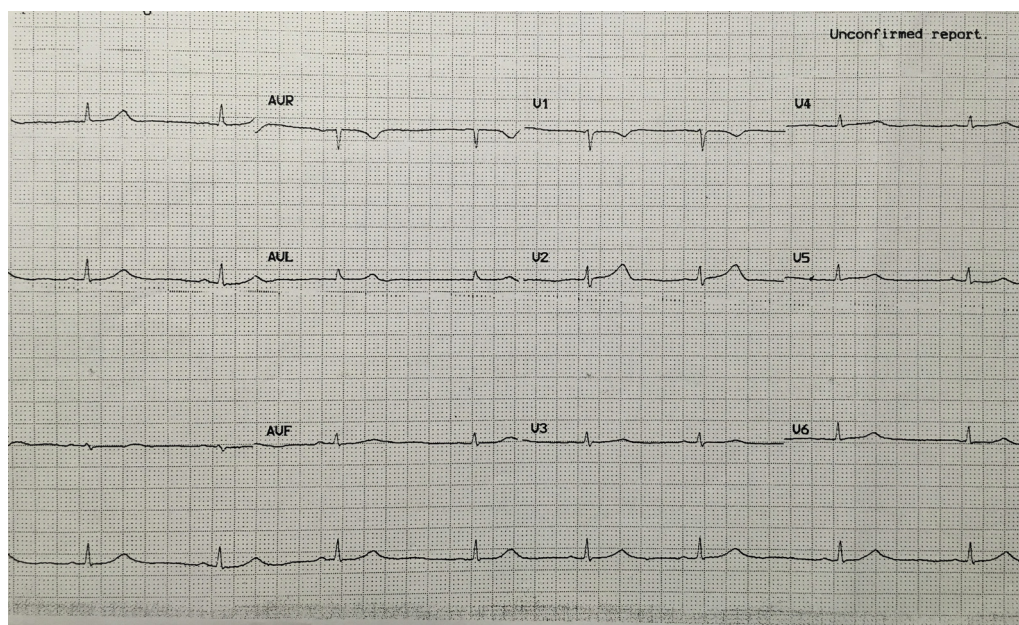
A 30-year-old female was admitted in ICU with complaints of fever with chills since 2 weeks, one episode of seizure 2 days prior and vomiting since 1 day before admission. The seizure was described as jerky movements of all four limbs associated with unconsciousness and fall, lasting for 10–15 s and with immediate recovery without any post-ictal drowsiness/bowel-bladder incontinence. There was no past history of arrhythmia, cardiac disease, or seizures. On examination patient was afebrile, clinically stable with relative bradycardia with pulse rate of 58/min regular, BP of 100/60 mmHg; systemic examination was normal. ECG on admission showed sinus bradycardia (Fig. 1). On investigations, patient had pancytopenia

\* Corresponding author.

E-mail address: [aninder.k@gmail.com](mailto:aninder.k@gmail.com) (A.K. Dhariwal).

<http://dx.doi.org/10.1016/j.ihj.2016.03.023>

0019-4832/© 2016 Cardiological Society of India. Published by Elsevier, a division of Reed Elsevier India, Pvt. Ltd. This is an open access article under the CC BY-NC-ND license (<http://creativecommons.org/licenses/by-nc-nd/4.0/>).



**Fig. 1 – ECG on admission showing sinus bradycardia.**

with Hb – 7.6 g%, Hct – 24.2, WBC count – 2200/mm<sup>3</sup>, platelet count – 64,000/mm<sup>3</sup>. CT brain – normal. Liver enzymes were raised (SGOT – 306 IU/L, SGPT – 138 IU/L). Patient was started on intravenous antibiotics and supportive treatment. Patient was worked up for pancytopenia. In view of history of 2-week fever with pancytopenia on admission our differential diagnoses were (1) toxemia with enteric fever, (2) hemophagocytic lymphohistiocytosis (HLH) secondary to viral infection, (3) connective tissue disorder, and (4) hematological disorder. Patient was investigated for these and was found to have elevated serum ferritin, serum triglycerides, and occasional hemophagocytes on bone marrow aspirate. Dengue IgM titres and NS1 antigen were positive and ultrasonogram showed mild hepatomegaly with pseudothickening of gall bladder, mild ascites, and mild right sided pleural effusion, suggestive of Dengue fever. Hence a diagnosis of HLH as post-sequelae to dengue fever was made and the patient was given intravenous gamma globulins as part of treatment of HLH. Patient was afebrile throughout the hospital stay. On day 4 of admission patient had 1 episode of vomiting followed by high degree AV block with ventricular asystole on the cardiac monitor, lasting for 11 s which responded to IV atropine, after which the patient had persistent sinus bradycardia with pulse rate remaining 50/min (Fig. 2). On the same day patient had a similar repeat episode of giddiness and vomiting associated with high degree AV block with ventricular asystole, while at rest which responded to IV atropine. Temporary transvenous pacing could not be done because of low platelet counts. Serum potassium, calcium and magnesium, thyroid profile, and 2D-ECHO were normal. In the presence of rhythm disturbances, the patient was further investigated for underlying myocarditis. The creatinine phosphokinase (CPK) and lactate dehydrogenase levels were slightly raised, however Troponin-T and CPK-MB levels were normal, with Troponin-T hs – 0.012 ng/ml (normal range <0.100 ng/ml) and CPK-MB – 1.47 ng/ml (normal range up

to 2.88 ng/ml). She was hemodynamically stable with persistent sinus bradycardia (heart rate – 48 to 60/minute). She was started on tablet orciprenaline (10 mg) qds (to accelerate the sinus rate) and was counseled about the SOS need for temporary cardiac pacing. On day 6 again patient had similar episode of high degree AV block with ventricular asystole associated with syncope lasting for a few seconds and which responded to IV atropine. On day 7, the heart rate improved and was remaining between 70 and 75 beats/min. Orciprenaline was continued, there were no further episodes of AV block or syncope and heart rate remained between 70 and 90/minute. The patient was discharged on day 10 on orciprenaline, which was continued for 1 month. On follow-up after 1 month, heart rate was normal and the patient had no history of any further syncopal episodes, ECG was normal, orciprenaline was stopped and she was asked to follow-up. On close follow-up of 6 months, there was no recurrence of the bradyarrhythmia on monitoring with external loop recorder for 7 days.

### 3. Discussion

Dengue is an important infectious disease and a major cause of morbidity and mortality in the South East Asia region. Hemorrhage and shock are the most common causes of death. Cardiac manifestations of dengue fever, though rare, should be known to physicians as they could influence the outcome of the disease.<sup>3</sup>

ECG alterations reported in dengue are often transient and nonspecific, including sinus bradycardia, atrioventricular block, T wave, and ST-segment abnormalities.<sup>1,6</sup> They are now known to occur during any phase of the disease, being observed in 30–44% of hospitalized dengue patients.<sup>1</sup> The association between dengue and bradyarrhythmias was highlighted in a study from Singapore.<sup>1</sup>

Download English Version:

<https://daneshyari.com/en/article/5603852>

Download Persian Version:

<https://daneshyari.com/article/5603852>

[Daneshyari.com](https://daneshyari.com)