

## Accepted Manuscript

Difference in Clinical Presentations and Related Angiographic Findings among Early, Late, and Very Late Sirolimus-Eluting Stent Failure Requiring Target Lesion Revascularization

Shunsuke Kubo, Masanobu Ohya, Akimune Kuwayama, Takenobu Shimada, Katsuya Miura, Hidewo Amano, Yusuke Hyodo, Suguru Otsuru, Seiji Habara, Takeshi Tada, Hiroyuki Tanaka, Yasushi Fuku, Tsuyoshi Goto, Kazushige Kadota

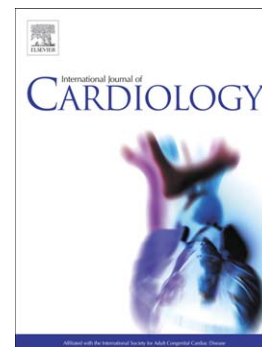
PII: S0167-5273(16)34883-5  
DOI: doi:[10.1016/j.ijcard.2017.05.052](https://doi.org/10.1016/j.ijcard.2017.05.052)  
Reference: IJCA 25010

To appear in: *International Journal of Cardiology*

Received date: 28 December 2016  
Revised date: 7 March 2017  
Accepted date: 11 May 2017

Please cite this article as: Kubo Shunsuke, Ohya Masanobu, Kuwayama Akimune, Shimada Takenobu, Miura Katsuya, Amano Hidewo, Hyodo Yusuke, Otsuru Suguru, Habara Seiji, Tada Takeshi, Tanaka Hiroyuki, Fuku Yasushi, Goto Tsuyoshi, Kadota Kazushige, Difference in Clinical Presentations and Related Angiographic Findings among Early, Late, and Very Late Sirolimus-Eluting Stent Failure Requiring Target Lesion Revascularization, *International Journal of Cardiology* (2017), doi:[10.1016/j.ijcard.2017.05.052](https://doi.org/10.1016/j.ijcard.2017.05.052)

This is a PDF file of an unedited manuscript that has been accepted for publication. As a service to our customers we are providing this early version of the manuscript. The manuscript will undergo copyediting, typesetting, and review of the resulting proof before it is published in its final form. Please note that during the production process errors may be discovered which could affect the content, and all legal disclaimers that apply to the journal pertain.



**Difference in Clinical Presentations and Related Angiographic Findings among Early, Late, and Very Late Sirolimus-Eluting Stent Failure Requiring Target Lesion Revascularization**

**Author's name:** Shunsuke Kubo, MD, Masanobu Ohya, MD, Akimune Kuwayama, MD, Takenobu Shimada, MD, Katsuya Miura, MD, Hidewo Amano, MD, Yusuke Hyodo, MD, Suguru Otsuru, MD, Seiji Habara, MD, Takeshi Tada, MD, PhD, Hiroyuki Tanaka, MD, Yasushi Fuku, MD, Tsuyoshi Goto, MD, Kazushige Kadota, MD, PhD

**Institution:** Department of Cardiology, Kurashiki Central Hospital, Kurashiki, Japan

**Grant support:** None

**Conflict of interest:** None of the authors have any conflicts of interest.

**Address for correspondence:** Shunsuke Kubo, MD

Mailing address: Shunsuke Kubo, Department of Cardiology, Kurashiki Central Hospital, 1-1-1 Miwa, Kurashiki 710-8602, Japan

Phone: 81-86-422-0210, Fax: +81-86-434-4507, E-mail: daba-kuboshun101@hotmail.co.jp

**Keywords:** Angiography, Sirolimus-Eluting Stent, Stent Edge, Long-Term Follow-Up, Acute Coronary Syndrome

Download English Version:

<https://daneshyari.com/en/article/5604235>

Download Persian Version:

<https://daneshyari.com/article/5604235>

[Daneshyari.com](https://daneshyari.com)