



Contents lists available at ScienceDirect

Journal of Arrhythmia

journal homepage: www.elsevier.com/locate/joa

CrossMark

Case Report

Adaptive cardiac resynchronization therapy for dilated cardiomyopathy with functional mitral regurgitation

Yoshiki Nagata, MD, PhD*, Yoichiro Nakagawa, MD, Yusuke Takeda, MD, Kenji Emoto, MD, Masaki Kinoshita, MD, Akio Chikata, MD, Michiro Maruyama, MD, PhD, Kazuo Usuda, MD, PhD

Division of Cardiology, Department of Internal Medicine, Toyama Prefectural Central Hospital, 2-2-78 Nishinagae, Toyama, Toyama Prefecture 930-8550, Japan

ARTICLE INFO

Article history:

Received 17 December 2016

Received in revised form

29 March 2017

Accepted 11 April 2017

Keywords:

Adaptive cardiac resynchronization therapy

Functional mitral regurgitation

Dilated cardiomyopathy

Left ventricular pacing

ABSTRACT

We report the case of a man in his 60s who had dilated cardiomyopathy with severe functional mitral regurgitation. Four years after a cardiac resynchronization therapy (CRT) device with an implantable cardioverter defibrillator was implanted, this device was replaced with an adaptive CRT device because of battery consumption. Seven months after replacement of this device, the left ventricular pacing to right ventricular activation and the atrioventricular delay from automatic adjustments contributed to less functional mitral regurgitation. The findings from our case suggest that optimal CRT, by measuring intracardiac conduction parameters, is effective for functional mitral regurgitation.

© 2017 Japanese Heart Rhythm Society. Published by Elsevier B.V. This is an open access article under the CC BY-NC-ND license (<http://creativecommons.org/licenses/by-nc-nd/4.0/>).

1. Introduction

Mitral regurgitation (MR) frequently develops in patients with left ventricular systolic dysfunction. Cardiac resynchronization therapy (CRT) often improves functional MR in patients with ventricular dyssynchrony. CRT produces a significant reduction, in left ventricular volume and in MR, and improves long-term benefits [1]. Benefits of CRT can be maximized through optimization of pacing parameters [2,3]. The adaptive CRT algorithm is a novel pacing algorithm for providing optimal CRT by measuring intracardiac conduction parameters [4]. In adaptive CRT, intracardiac timing events are constantly measured and pacing is altered in response to the factors of intrinsic conduction, determination of the best pacing (left ventricular-only or bi-ventricular), and optimization of atrioventricular and ventriculo-ventricular timing, in that sequence.

We report a case of heart failure in which functional MR was improved after an upgrade of a standard CRT device to an adaptive CRT.

2. Case report

A man in his 60s with idiopathic dilated cardiomyopathy and functional MR showed cardiomegaly on a chest X-ray (Fig. 1A) and left bundle branch block (QRS duration of 182 ms) on an electrocardiogram (Fig. 2). Echocardiography showed a dilated left ventricle, diffuse hypokinesis with mechanical dyssynchrony (ejection fraction of 21.6%), and severe MR (Fig. 3, Table 1). A CRT device with an implantable cardioverter defibrillator (CRT-D) (Consulta CRT-D; Medtronic Inc., Minneapolis, MN, USA) had been implanted in 2009. This device had a dual-coil implantable cardioverter defibrillator lead positioned at the apical right ventricular septum and a bipolar pacing lead positioned on the posterior-lateral vein via the coronary sinus. Atrioventricular delay with atrial pacing was 130 ms and atrioventricular delay with sinus rhythm was 100 ms. At a subsequent follow-up of the implant, the bi-ventricular pacing rate was between 91.1% and 99.9%. After implantation of the CRT-D, the QRS duration was shortened to 132 ms (Fig. 2) and the ejection fraction improved to 27.0% (Table 1). His heart failure was improved (Fig. 1B), but severe MR was still present (Fig. 3, Video 1). Four years after CRT-D implantation, he was repeatedly admitted to the hospital because of worsening heart failure and ventricular fibrillation (Vf). The OptiVol fluid index frequently increased (Fig. 4). In February 2014, a Vf storm suddenly occurred and multiple defibrillator shocks were provided 32 times. Treatment with a CRT-D succeeded in saving his life, but the battery needed to be replaced constantly. Elective replacement of the CRT-D device was performed when his condition improved. The leads performed well and were regularly

* Corresponding author. Fax: +81 76 422 0667.

E-mail addresses: drnagata@nsknet.or.jp (Y. Nagata), yoichiro.n.99@gmail.com (Y. Nakagawa), yusuketakeda8@gmail.com (Y. Takeda), k7en3mj3t13@gmail.com (K. Emoto), mkmk14700@gmail.com (M. Kinoshita), akio.chikata@gmail.com (A. Chikata), maruyama@tch.pref.toyama.jp (M. Maruyama), usudak@tch.pref.toyama.jp (K. Usuda).

<http://dx.doi.org/10.1016/j.joa.2017.04.003>

1880-4276/© 2017 Japanese Heart Rhythm Society. Published by Elsevier B.V. This is an open access article under the CC BY-NC-ND license (<http://creativecommons.org/licenses/by-nc-nd/4.0/>).

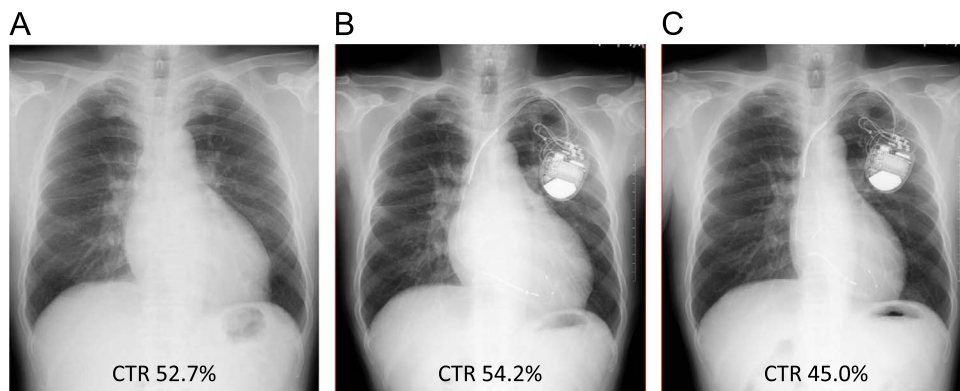


Fig. 1. Chest X-ray. A: Before CRT. B: Four years after standard CRT. C: Nine months after adaptive CRT. CRT: cardiac resynchronization therapy.

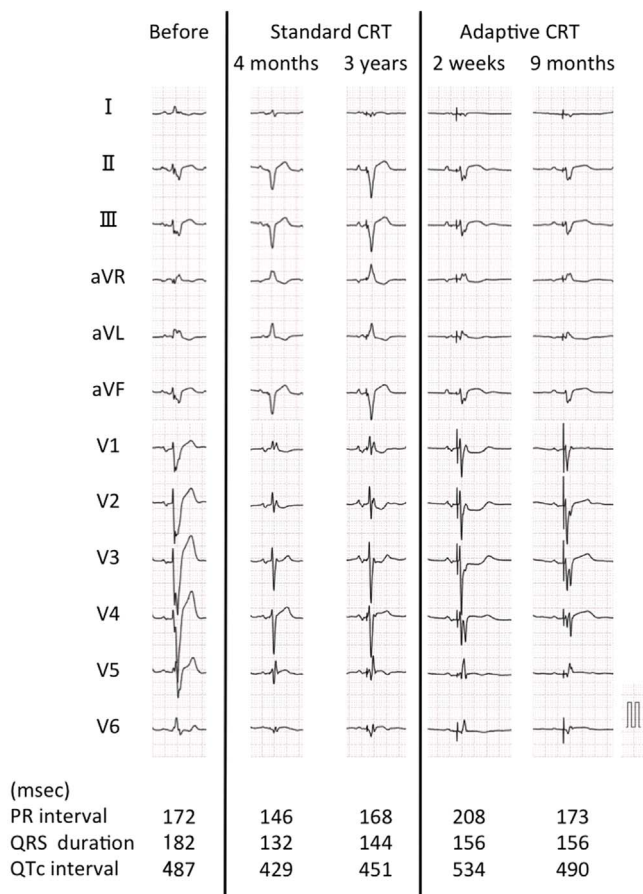


Fig. 2. Twelve-lead electrocardiogram. CRT: cardiac resynchronization therapy.

connected to the adaptive CRT-D device (VIVA XT CRT-D; Medtronic Inc.). He was taking trichlormethiazide 1 mg, furosemide 80 mg, eplerenone 50 mg, carvedilol 7.5 mg, pimobendan 5 mg, digoxin 0.125 mg, and mexiletine 200 mg daily. After the Vf storm, the antiarrhythmic drug was changed from mexiletine to sotalol 120 mg daily, because he had a history of an amiodarone-induced liver injury.

Supplementary material related to this article can be found online at: <http://dx.doi.org/10.1016/j.joa.2017.04.003>.

Seven months after introducing adaptive CRT, the patient's cardiomegaly dramatically improved (Fig. 1C). Adaptive CRT adjusted the PR interval. An electrocardiogram showed a change to

the QRS complex and a slightly widened QRS duration (Fig. 2). Echocardiography showed less MR and a reduction in left atrial volume (Fig. 3, Video 2). Transmitral flow showed a severe diastolic dysfunction pattern before CRT implantation and during standard CRT (Fig. 3). This pattern changed to mild diastolic dysfunction during adaptive CRT. The brain natriuretic peptide level decreased from 359.7 to 30.3 pg/mL. Fig. 4 shows a record of pacing parameters and the OptiVol fluid index. Atrioventricular delay fluctuated between 100 and 140 ms. The bi-ventricular pacing rate was between 94.2% and 97.2%, involving 77% (57–94%) of left ventricular pacing. After adaptive CRT, the OptiVol fluid index decreased. When increasing the OptiVol fluid index during adaptive CRT, the left ventricular pacing rate was increased to > 90%. Use of the adaptive CRT algorithm led to a reduced number of hospital readmissions for heart failure.

Supplementary material related to this article can be found online at: <http://dx.doi.org/10.1016/j.joa.2017.04.003>.

3. Discussion

Despite the fact that our patient responded to CRT after the first operation, an upgrade to adaptive CRT was more effective for treating heart failure. Optimization of atrioventricular timing and right ventricular fusion to left ventricular pacing reduced functional MR and left atrial volume. Adjusting the left ventricular pacing rate and atrioventricular timing contributed to an improvement in heart failure.

Functional MR in left ventricular systolic dysfunction results from an imbalance between the closing and the tethering forces that act on the mitral valve leaflets. This mitral valve closing force is determined by the systolic left ventricular-left atrial pressure difference (transmitral pressure gradient). CRT improves left ventricular contractility, and the transmitral pressure gradient rises faster and to a higher maximal value, which is also reached earlier [5]. Mitral inflow is dependent on the timing of the left atrial and left ventricular systole. A delay in interatrial conduction affects optimal timing of ventricular pacing [2]. Left-ventricular pacing with optimized atrioventricular timing might provide greater benefit for ejection fraction and MR compared with bi-ventricular pacing [6]. In our case, the adaptive CRT algorithm resulted in a 77% reduction in the percentage of right ventricular pacing and dynamic atrioventricular optimization. These effects immediately changed mitral inflow and improved left atrial and ventricular dilatation after 9 months. Functional MR is reduced by the immediate effect of resynchronization and improvement in left ventricular contraction (synchronized mechanical activation), and the delayed effects of favorable changes in the mitral valve

Download English Version:

<https://daneshyari.com/en/article/5613820>

Download Persian Version:

<https://daneshyari.com/article/5613820>

[Daneshyari.com](https://daneshyari.com)