



## Case Report

## Coronary vasospasm complicating cannabinoid hyperemesis syndrome

Sophie Pierard (MD PhD)<sup>a</sup>, Philippe Hantson (MD PhD)<sup>b,c,\*</sup><sup>a</sup> Department of Cardiovascular Intensive Care, Université Catholique de Louvain, Brussels, Belgium<sup>b</sup> Department of Intensive Care, Cliniques St-Luc, Université Catholique de Louvain, Brussels, Belgium<sup>c</sup> Louvain Centre for Toxicology and Applied Pharmacology, Université Catholique de Louvain, Brussels, Belgium

## ARTICLE INFO

## Article history:

Received 5 August 2016

Received in revised form 30 November 2016

Accepted 2 December 2016

## Keywords:

Cannabis

Cannabinoid hyperemesis syndrome

Acute coronary syndrome

Vasospasm

## ABSTRACT

Cannabinoid hyperemesis syndrome (CHS) is a clinical condition that was first described in 2004. The syndrome may occasionally be observed in long-term cannabis users and is characterized by a set of features: severe cyclic nausea and vomiting, recurrent epigastric or periumbilical pain, relief of symptoms with hot baths, and cannabis use cessation. The pathophysiology is not fully understood but is probably related to Cannabinoid-1 (CB-1) receptors dysregulation. On the other hand, there is also growing epidemiological evidence that cannabis smoking may trigger acute coronary syndrome (ACS) in young men. We describe the case of 41-year-old man with a long history of cannabis smoking who not only complained of recurrent epigastric but also of retrosternal pain. He had undergone several negative radiological or endoscopic investigations. During the last episode, electrocardiographic and echocardiographic changes were consistent with takotsubo cardiomyopathy. However, the patient was readmitted very soon with a ST-elevation myocardial infarction related to coronary vasospasm. While the link between CHS and ACS is not established, CHS patients with atypical pain should be investigated carefully to exclude any serious cardiac event.

<Learning objective: Cannabinoid hyperemesis syndrome is a rare medical entity than can be observed in some long-term heavy cannabis users. While most patients usually complain of recurrent epigastric or periumbilical pain with negative investigations, the possibility of some serious cardiac event should not be neglected as cannabis seems also able to trigger coronary vasospasm in patients presenting with atypical pain or electrocardiographic changes.>

© 2016 Japanese College of Cardiology. Published by Elsevier Ltd. All rights reserved.

## Introduction

Cannabis use in the world is widespread. In France, more than 1.5 million people regularly use cannabis (at least 10 times a month) [1]. In comparison to this large use, complications are rare and remain debated as the only etiologic proof is the closed relationship between timing of cannabis use and onset of symptoms. Among the multiple complications, myocardial infarction is one of the most feared. Several mechanisms are suspected: 1 – coronary vasospasm, 2 – misbalance between oxygen consumption and delivery due to activation of sympathetic system (type 2 myocardial infarction), or 3 – atherosclerotic plaque disruption (type 1 myocardial infarction) [2,3].

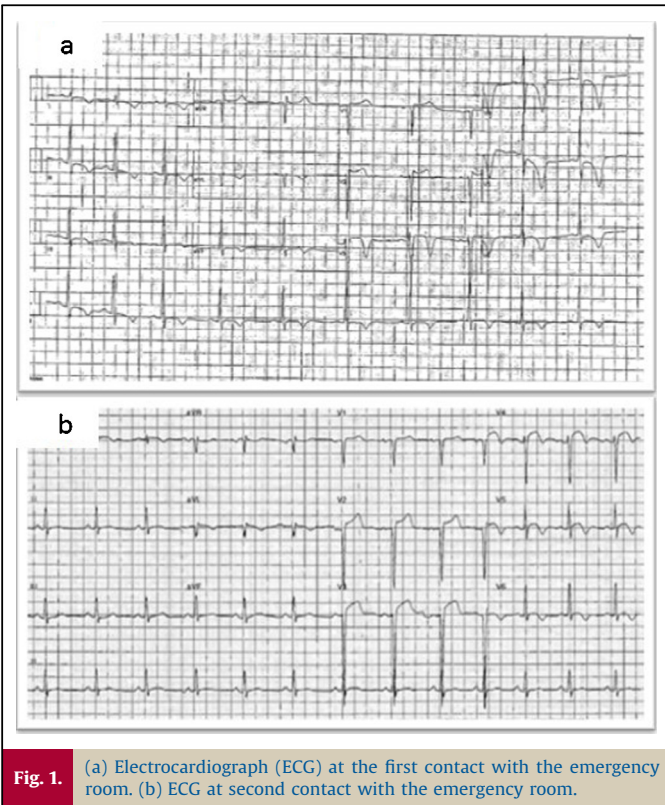
We report the case of a patient who experienced a ST-elevation myocardial infarction due to coronary vasospasm in a temporal relationship with cannabis use. To our knowledge, this is the first case described to date of a cannabis-induced coronary vasospasm concomitant to cannabinoid hyperemesis syndrome (CHS).

## Case report

A 41-year-old man with a 20-year history of chronic nicotine and cannabis smoking (more than 1 g daily) was admitted to the emergency room for retrosternal constrictive chest and epigastric pain. Since 2–3 weeks, the patient experienced similar pain after having used cannabis. The patient denied having used other medication or drugs or alcohol. According to him, pain was relieved only by hot showers. One week before, he had been admitted to another hospital for similar symptoms occurring several times a day, either at rest or after meals and mild physical effort. The electrocardiogram (ECG) at this time showed negative T waves in

\* Corresponding author at: Department of Intensive Care, Cliniques St-Luc, Avenue Hippocrate, 10, 1200 Brussels, Belgium. Fax: +32 27648928.

E-mail address: [philippe.hantson@uclouvain.be](mailto:philippe.hantson@uclouvain.be) (P. Hantson).



**Fig. 1.** (a) Electrocardiograph (ECG) at the first contact with the emergency room. (b) ECG at second contact with the emergency room.

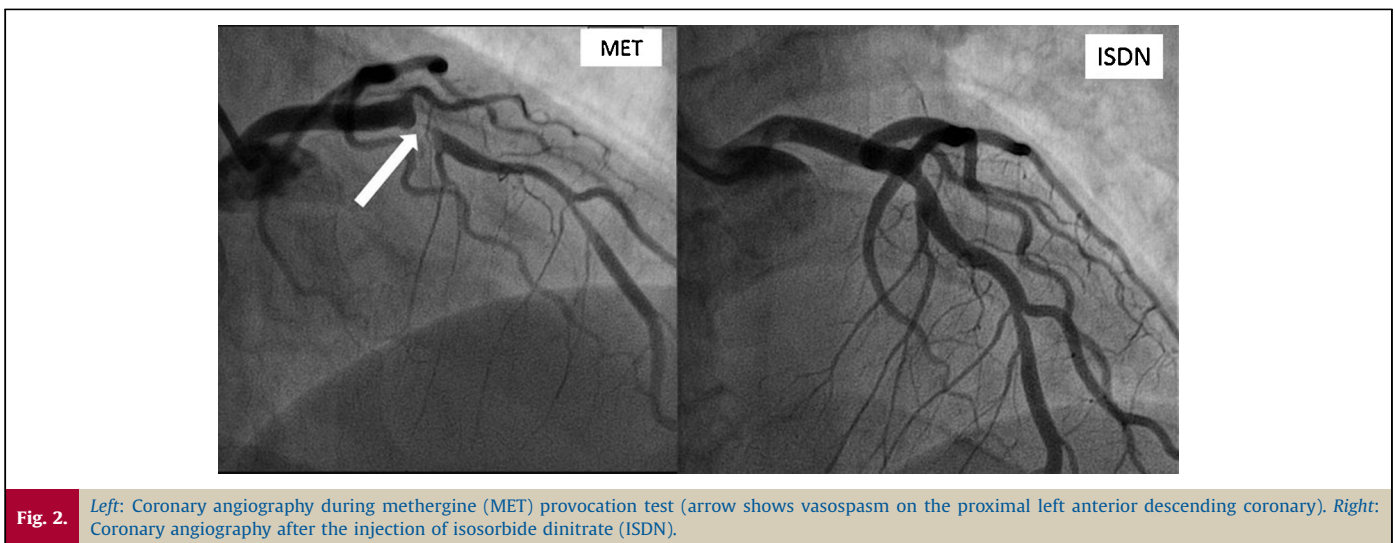
the inferior and antero-lateral leads evolving to ST segment elevation in the same territories during painful episodes (Fig. 1a). Coronary angiography was performed and showed a 40% stenosis on the proximal part of the left anterior descending (LAD) artery. The peak serum troponin T HS concentration was 86 pg/ml during the hospitalization. Echocardiography showed large akinetic apical segments and an impaired left ventricular function, with a calculated ejected fraction of 37%. Takotsubo stress cardiomyopathy was concluded and the patient was discharged with angiotensin-converting enzyme inhibitors, beta-blockers, and calcium channel blockers as medications. As he had a history of pancreatitis, abdominal computed tomography (CT) scan, gastric endoscopy, and abdominal echography were realized and were all negative.

Less than 24 h later, the patient was readmitted for similar symptoms. ECG revealed >2 mm ST segment elevation in V2–V4 precordial leads with presence of Q waves and negative T waves in V5–V6 (Fig. 1b). On admission, the troponin T serum level was 7628 pg/ml and CK 5489 U/l. Toxicological urine analysis was positive for cannabis, and further analysis of the personal cannabis sample provided by the patient excluded the presence of any other toxic substance. Echocardiography showed a septal, anterior, and apical akinesia with severely impaired left ventricular function. Coronary angiography was repeated immediately and was unchanged. During an intracoronary ergonovine provocation test, a reversible subocclusion of the middle and distal part of the LAD coronary artery reproduced the patient's typical complaints (Fig. 2). Molsidomine, diltiazem, and clopidogrel were added to the previous treatment. Cardiac magnetic resonance imaging (MRI) was performed and revealed a marked ischemic transmural necrosis in the apical, anterior, and septal territory (Fig. 3). At 1-year follow-up, the patient remained asymptomatic and has fully stopped cannabis use and pain never relapsed.

### Discussion

Young adults with a long history of cannabis use may present with unusual clinical manifestations. Among them, the CHS is characterized by recurrent episodes of nausea, vomiting, and abdominal pain leading to frequent visits to the emergency department. In nearly all cases, several years of cannabis use elapse before onset of symptoms [4]. In the present observation, the patient mainly complained from abdominal and retrosternal pain, without frank hyperemesis. He underwent a lot of investigations during the last months (endoscopy, abdominal CT scan, and echography) without any conclusive findings. Interestingly, he also made the experience that hot showers effectively alleviated his pain, a common observation among patients presenting with this syndrome. The precise mechanism by which hot showers improve abdominal pain is not clear. As the CB-1 receptor is near the thermoregulatory center of the hypothalamus, chronic CB-1 hypothalamic stimulation might be counteracted by warm bathing [5]. Another proposed mechanism is a “cutaneous steal syndrome” with redistribution of blood flow from the vasodilated splanchnic circulation to muscle [6].

Other clinical manifestations presenting in cannabis users are cardiovascular problems such as myocardial infarction. Our patient presented with ST elevation myocardial infarction acute coronary syndrome (ACS). Coronary angiography supported a vasospastic



**Fig. 2.** Left: Coronary angiography during methergine (MET) provocation test (arrow shows vasospasm on the proximal left anterior descending coronary). Right: Coronary angiography after the injection of isosorbide dinitrate (ISDN).

Download English Version:

<https://daneshyari.com/en/article/5614953>

Download Persian Version:

<https://daneshyari.com/article/5614953>

[Daneshyari.com](https://daneshyari.com)