

Leg symptoms associated with sacroiliac joint disorder and related pain



Eiichi Murakami^{a,*}, Toshimi Aizawa^b, Daisuke Kurosawa^a, Kyoko Noguchi^a

^a Department of Orthopaedic Surgery, JCHO Sendai Hospital, Japan

^b Department of Orthopaedic Surgery, Tohoku University School of Medicine, Japan

ARTICLE INFO

Keywords:

Sacroiliac joint
Leg symptoms
Pain
Numbness
Posterior sacroiliac ligament

ABSTRACT

Objective: The symptoms of sacroiliac joint (SIJ) disorders are usually detected in the buttock and groin, and occasionally referred to the thigh and leg. However, lumbar disorders also cause symptoms in these same body regions. The presence of a characteristic, symptomatic pattern in the legs would be useful for diagnosing SIJ disorders. This study aimed to identify specific leg symptoms in patients with SIJ pain originating from the posterior sacroiliac ligament and determine the rate of occurrence of these symptoms.

Patients and methods: The source population consisted of 365 consecutive patients from February 2005 to December 2007. One hundred patients were diagnosed with SIJ pain by a periarticular SIJ injection (42 males and 58 females, average age 46 years, age range, 18–75 years). A leg symptom map was made by subtracting the symptoms after a periarticular SIJ injection from the initial symptoms, and evaluating the rate of each individual symptom by area.

Results: Ninety-four patients reported pain at or around the posterior-superior iliac spine (PSIS). Leg symptoms comprised pain and a numbness/tingling sensation; $\geq 60\%$ of the patients had these symptoms. Pain was mainly detected in the back, buttock, groin, and thigh areas, while numbness/tingling was mainly detected in the lateral to posterior thigh and back of the calf.

Conclusions: Leg symptoms associated with SIJ pain originating from the posterior sacroiliac ligament include both pain and numbness, which do not usually correspond to the dermatome. These leg symptoms in addition to pain around the PSIS may indicate SIJ disorders.

1. Introduction

Neurogenic or referred symptoms in the leg or legs usually originate from lumbar disorders, and the area and pattern of these symptoms are specific to the underlying pathology and involved neural tissues. For example, lumbar vertebra (L)5 root impairment secondary to lumbar disc herniation typically causes lateral thigh and leg pain on the involved side, particularly after lifting, twisting, or moving a heavy weight [1], while cauda equina syndrome secondary to lumbar spinal canal stenosis commonly results in bilateral posterior leg numbness during walking or standing. Therefore, the symptomatic pattern in the leg or legs may be a good indicator of the underlying lumbar pathology.

Recently, the sacroiliac joint (SIJ) is being increasingly recognized as a cause of lower back pain [2–4]. Pain originating from the SIJ can also spread to the abdominal and groin area, leg(s), and even foot [3,5–8]. Because symptoms of disorders in the SIJ and lumbar region affect the same body areas (the back, buttocks, and legs) it is occasionally very difficult to distinguish whether the symptoms are originating from the SIJ or lumbar region [3,6,7,9]. Additionally, SIJ

pain cannot be diagnosed by imaging studies [10,11]. As such, the presence of a characteristic symptomatic pattern in the leg(s) would be useful for diagnosing SIJ disorders. However, such symptoms have not been analyzed in detail.

Moreover, the SIJ is regarded as a complex structure, consisting of the anterior articular compartment and posterior ligamentous compartment (such as the posterior sacroiliac ligament) [12], and each compartment is potentially a source of SIJ pain [13–15]. In our previous study [16], a periarticular SIJ injection was more effective than an intraarticular SIJ injection for patients with pain over the SIJ area from probable SIJ disorders. We concluded that the SIJ pain originated from both the intraarticular and periarticular regions, but more frequently from the periarticular region. Therefore, it is important to detect leg symptoms accompanying SIJ pain originating from the posterior sacroiliac ligament; this may cause the majority of SIJ pain. Until now, several studies reported leg symptoms originating from the articular compartment detected by intraarticular SIJ injection [3,6,17]. However, there are few reports about leg symptoms from the posterior sacroiliac ligament detected by the periarticular SIJ injection [8]. The

* Corresponding author at: Department of Orthopaedic Surgery, JCHO Sendai Hospital, 3-16-1 Tsutsumi-machi, Aoba-ku, Sendai 981-8501, Japan.
E-mail address: murakami@sendai-shaho.com (E. Murakami).

purpose of this study was to identify specific leg symptoms in patients with SIJ disorder and related pain originating from the posterior sacroiliac ligament and determine the rate of occurrence of these symptoms.

2. Materials and methods

2.1. Patient collection

Our institutional review board approved this study, and informed consent was obtained from all patients before their participation.

In accordance with our previous study [4], patients under 16 years or more than 75 years old were excluded from this study. The source population consisted of 365 consecutive patients from our outpatient clinic having symptoms from their back to leg(s). Among these 365 patients, 184 were included in this study because they met the following criteria: 1) the presence of low back and/or buttock pain at only one site; 2) positive findings on at least one of the following three provocation tests for the SIJ pain, including Gaenslen's test [18], Patrick's test [19], SIJ shear test [12] and 3) no findings suspicious of infectious or inflammatory arthritis of the SIJ on laboratory investigation and plain radiographs, or of vascular diseases in the legs. Out of the 184 patients, 38 with findings of lumbosacral nerve root compression on magnetic resonance imaging and/or with positive straight leg raising test, abnormal knee jerk and/or ankle jerk were excluded.

For the remaining 146 patients, we first injected 1 mL of 2% lidocaine into the painful side of the paravertebral muscle around the facet joint at the L4/5 level to know whether the patient would have a placebo response. Then, we performed an injection of a local anesthetic on the posterior sacroiliac ligamentous region, a periarticular SIJ injection as done in our previous study [4,8] (Fig. 1). We defined a positive placebo response as $\geq 50\%$ pain relief after an injection to investigate placebo response, and an effective SIJ injection as $\geq 70\%$ decrease in pain as assessed by a visual analogue scale or pain relief scale at 15–30 min after the injection [4,8]. One hundred patients were definitely diagnosed with SIJ pain originating from the posterior sacroiliac ligament, excluding 20 patients who showed a positive placebo response and 26 patients with non-effective periarticular SIJ injection. These 100 patients were the subjects of this study. The patients were comprised of 42 males and 58 females, and the average age at the first visit to our hospital was 46 years (range, 18–75 years).

2.2. Evaluation of leg symptoms

The leg symptoms of all patients were retrospectively analyzed from their medical charts. At the initial evaluation, we asked the patients about the areas in which they felt symptoms in their buttock and legs and recorded the individual symptoms on diagrams of the lower half of the body. Next, 0.5–1.0 mL of a mixture of 2% lidocaine and contrast medium (1:1 mixture ratio) was injected into one or more sections where pain was reproduced by needle insertion, as in our previous study [8]. After achieving a $\geq 70\%$ decrease in pain by the periarticular SIJ injection, we again asked the patients about the symptomatic areas in which they felt no improvement after the injection and recorded this information on the diagrams. Finally, we subtracted the final symptoms from the initial symptoms and made a leg symptom map representing the rate of each individual symptom by area.

3. Results

Ninety-four patients (94%) complained of pain at or around the posterior-superior iliac spine (PSIS). Leg symptoms comprised pain and a numbness/tingling sensation; $\geq 60\%$ of the patients had these symptoms. Pain was reported in 64 patients, and a sensation of numbness/tingling was reported in 52 patients. A leg pain map is shown in Fig. 2; this map was created by subtracting the pain that

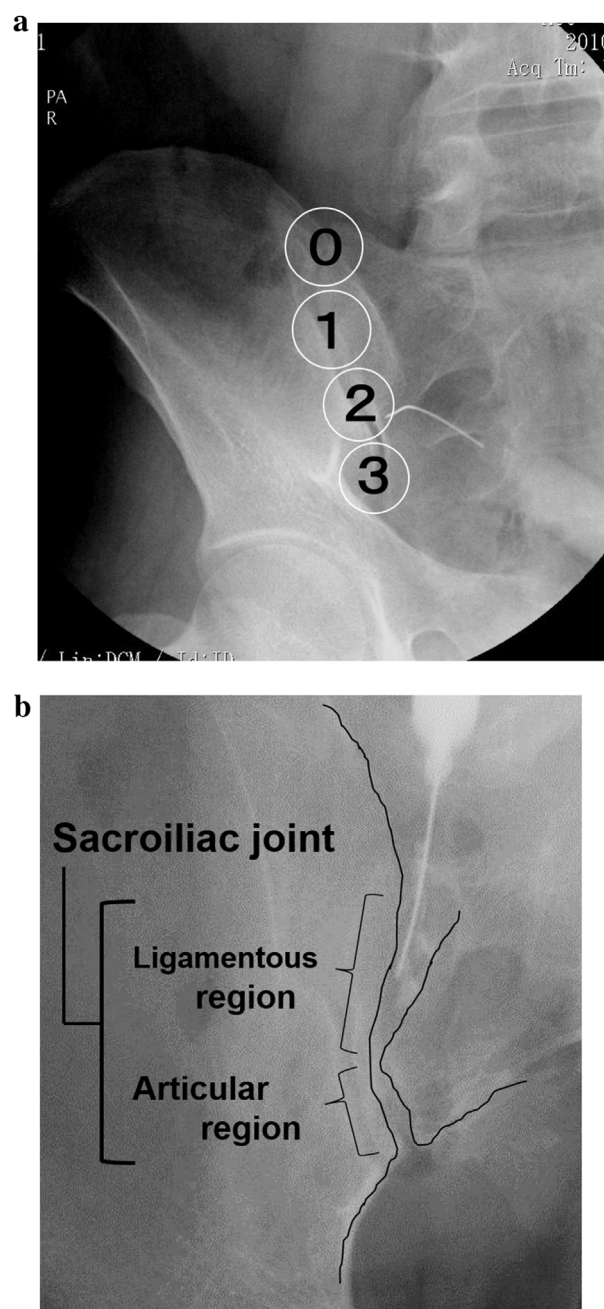


Fig. 1. (a) Fluoroscopy-guided periarticular sacroiliac joint injection. Posterior sacroiliac ligamentous region is divided 4 sections (0, 1, 2, 3). The needle is inserted into each section. A mixture of 2% lidocaine and contrast medium is injected into one or more sections with a positive pain provocation by needle insertion. (b) Inlet view of sacroiliac joint under fluoroscopy. Contrast medium is injected on the posterior sacroiliac ligamentous region in Section 2.

remained after the periarticular SIJ injection from the initial pain. The leg pain was reported in the posterolateral thigh in 36 patients (36%), posteromedial thigh in 28 patients (28%), from the hypogastric to inguinal area (groin pain) in 23 patients (23%), and at the ischial tuberosity in 6 patients (6%). Only 3% of the patients complained of lateral ankle pain.

The numbness/tingling map is shown in Fig. 3. The most frequently affected areas were the posterolateral thigh in 30 patients (30%), the back of the calf in 12 patients (12%), and the anterolateral thigh in 10 patients (10%). No patients complained of a numbness/tingling sensa-

Download English Version:

<https://daneshyari.com/en/article/5627139>

Download Persian Version:

<https://daneshyari.com/article/5627139>

[Daneshyari.com](https://daneshyari.com)