

Accepted Manuscript

Clinical Features, Surgical Treatment, and Long-Term Outcome in Elderly Patients with Moyamoya Disease

Peicong Ge, Qian Zhang, Xun Ye, Xingju Liu, Xiaofeng Deng, Rong Wang, Yan Zhang, Dong Zhang, Jizong Zhao

PII: S1878-8750(17)30078-5

DOI: [10.1016/j.wneu.2017.01.055](https://doi.org/10.1016/j.wneu.2017.01.055)

Reference: WNEU 5152

To appear in: *World Neurosurgery*

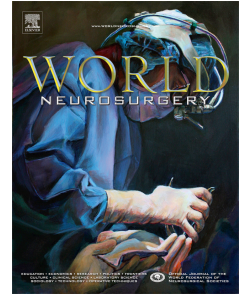
Received Date: 14 November 2016

Revised Date: 12 January 2017

Accepted Date: 16 January 2017

Please cite this article as: Ge P, Zhang Q, Ye X, Liu X, Deng X, Wang R, Zhang Y, Zhang D, Zhao J, Clinical Features, Surgical Treatment, and Long-Term Outcome in Elderly Patients with Moyamoya Disease, *World Neurosurgery* (2017), doi: 10.1016/j.wneu.2017.01.055.

This is a PDF file of an unedited manuscript that has been accepted for publication. As a service to our customers we are providing this early version of the manuscript. The manuscript will undergo copyediting, typesetting, and review of the resulting proof before it is published in its final form. Please note that during the production process errors may be discovered which could affect the content, and all legal disclaimers that apply to the journal pertain.



Clinical Features, Surgical Treatment, and Long-Term Outcome in Elderly Patients with Moyamoya Disease.

Peicong Ge,^{1,4} Qian Zhang,^{1,4} Xun Ye,^{1,4} Xingju Liu,^{1,4} Xiaofeng Deng,^{1,4} Rong Wang,^{1,4} Yan Zhang,^{1,4} Dong Zhang,^{1,4} Jizong Zhao,^{1,4}

From the ¹Department of Neurosurgery, Beijing Tiantan Hospital, Capital Medical University, Beijing; ²China National Clinical Research Center for Neurological Diseases, Beijing; ³Center of Stroke, Beijing Institute for Brain Disorders, Beijing; ⁴Beijing Key Laboratory of Translational Medicine for Cerebrovascular Disease, Beijing; Beijing, China 6 Tiantanxili, DongCheng District, Beijing 100050 China, Tel: +86-10-67096523.

Corresponding author:

Name: Jizong Zhao

Telephone number: +86-010-67096523 Fax: 010-65113440

E-mail: zhaojz205@yahoo.com

Key words: Elderly Moyamoya Disease; Clinical features; Cerebral revascularization; Outcome

Abbreviations and Acronyms

CT: Computed tomography

EDAS: encephaloduroarteriosynangiosis

MMD: moyamoya disease

MR: Magnetic resonance

mRS: modified Rankin scale

PCA: Posterior cerebral artery

STA-MCA: superficial temporal artery to the middle cerebral artery

TIA: Transient Ischemic Attack

HR-MRI: High resolution magnetic resonance imaging

Download English Version:

<https://daneshyari.com/en/article/5634525>

Download Persian Version:

<https://daneshyari.com/article/5634525>

[Daneshyari.com](https://daneshyari.com)