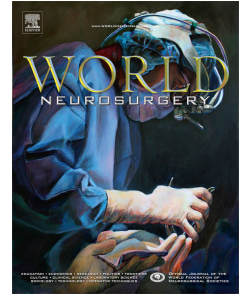


# Accepted Manuscript

Aggressive Pituitary Adenomas: The Dark Side of the Moon

Stefano M. Priola, M.D., Felice Esposito, M.D., Ph.D., Salvatore Cannavò, M.D., Alfredo Conti, M.D., Ph.D., Rosaria V. Abbritti, M.D., Valeria Barresi, M.D., Sergio Baldari, M.D., Francesco Ferraù, M.D., Ph.D., Antonino Germanò, M.D., Francesco Tomasello, M.D., Filippo F. Angileri, M.D., Ph.D.



PII: S1878-8750(16)30945-7

DOI: [10.1016/j.wneu.2016.09.092](https://doi.org/10.1016/j.wneu.2016.09.092)

Reference: WNEU 4632

To appear in: *World Neurosurgery*

Received Date: 6 June 2016

Revised Date: 18 September 2016

Accepted Date: 23 September 2016

Please cite this article as: Priola SM, Esposito F, Cannavò S, Conti A, Abbritti RV, Barresi V, Baldari S, Ferraù F, Germanò A, Tomasello F, Angileri FF, Aggressive Pituitary Adenomas: The Dark Side of the Moon, *World Neurosurgery* (2016), doi: 10.1016/j.wneu.2016.09.092.

This is a PDF file of an unedited manuscript that has been accepted for publication. As a service to our customers we are providing this early version of the manuscript. The manuscript will undergo copyediting, typesetting, and review of the resulting proof before it is published in its final form. Please note that during the production process errors may be discovered which could affect the content, and all legal disclaimers that apply to the journal pertain.

# Aggressive Pituitary Adenomas: The Dark Side of the Moon

Stefano M. Priola<sup>1</sup>, M.D.; Felice Esposito<sup>1</sup>, M.D., Ph.D.; Salvatore Cannavò<sup>2</sup>, M.D.;  
Alfredo Conti<sup>1</sup>, M.D., Ph.D.; Rosaria V. Abbritti<sup>1</sup>, M.D.; Valeria Barresi<sup>3</sup>, M.D.;  
Sergio Baldari<sup>4</sup>, M.D.; Francesco Ferrau<sup>2</sup>, M.D., Ph.D.; Antonino Germanò<sup>1</sup>, M.D.;  
Francesco Tomasello<sup>1</sup>, M.D.; Filippo F. Angileri<sup>1</sup>, M.D., Ph.D.

<sup>1</sup>*Department of Biomedical and Dental Sciences, and Morpho-Functional Imaging;  
Division of Neurosurgery, University of Messina, ITALY*

<sup>1</sup>*Department of Clinical and Experimental Medicine; Division of Endocrinology,  
University of Messina, ITALY*

<sup>3</sup>*Department of Human Pathology “Gaetano Barresi”, Division of Pathology,  
University of Messina, ITALY*

<sup>4</sup>*Department of Biomedical and Dental Sciences, and Morpho-Functional Imaging;  
Division of Nuclear Medicine, University of Messina, ITALY*

Corresponding Author:

**Felice Esposito**, M.D., Ph.D.

Biomedical and Dental Sciences, and Morpho-Functional Imaging

Division of Neurosurgery University of Messina

Via Consolare Valeria 1

98125 Messina, ITALY

Tel. +39 090 221.3849

Fax +39 081 1885.1043

Email: felice.esposito@unime.it

Download English Version:

<https://daneshyari.com/en/article/5634707>

Download Persian Version:

<https://daneshyari.com/article/5634707>

[Daneshyari.com](https://daneshyari.com)