

Detection of Apical Root Cracks Using Spectral Domain and Swept-source Optical Coherence Tomography

Bruna Paloma de Oliveira, DDS, MSc,* Andréa Cruz Câmara, DDS, MSc, PhD,*
Daniel Amancio Duarte, MSc,[†] Anderson Stevens Leonidas Gomes, MSc, PhD,[‡]
Richard John Heck, MSc, PhD,[§] Antonio Celso Dantas Antonino, MSc, PhD,[†]
and Carlos Menezes Aguiar, DDS, MSc, PhD*

Abstract

Introduction: This study aimed to evaluate the ability of 2 optical coherence tomographic (OCT) systems to detect apical dentinal microcracks. **Methods:** Twenty extracted human single-rooted mandibular incisors were selected. After root canal preparation with an R40 Reciproc file (VDW, Munich, Germany), the specimens presenting apical microcracks were identified using micro-computed tomographic (micro-CT) scanning as the gold standard. Then, the apical portions of the roots were imaged with spectral domain OCT (SD-OCT) and swept-source OCT systems, and the resulting images were blindly evaluated by 3 independent examiners to detect microcracks. The diagnostic performance of each OCT device was calculated, and statistical analysis was performed. **Results:** Based on the micro-CT images, 12 (60%) roots presented dentinal microcracks in the apical region. The images generated by the OCT systems were able to show microcrack lines at the same location as the corresponding micro-CT cross sections. Although the diagnostic performance of the SD-OCT device was superior, there were no statistically significant differences between the 2 OCT devices ($P > .05$). Inter-examiner agreement was substantial to almost perfect for the SD-OCT system and moderate to almost perfect for the swept-source OCT system, whereas intra-examiner agreement was substantial to almost perfect for both OCT devices. **Conclusions:** The detection ability verified for both OCT systems renders them promising tools for the diagnosis of apical microcracks. (*J Endod* 2017; ■:1–4)

Key Words

Dentinal crack, diagnosis, micro-computed tomography, optical coherence tomography, Reciproc, root canal

Dentinal cracks are a specific condition that may influence the long-term survival of the affected tooth (1). Clinically, microorganisms may proliferate in crack lines, leading to the establishment of biofilm

on the root surface (2). Additionally, vertical root fractures may occur because of microcrack propagation (3). Thus, the early diagnosis of dentinal microcracks is fundamental to prevent complications (4).

However, cracked teeth are considered a diagnostic challenge to clinicians because of the variable signs and symptoms presented along with the difficulty of locating the crack lines (1, 5). The current available methods to diagnose cracked teeth include radiography, cone-beam computed tomographic imaging, transillumination, periodontal probing, the bite test, staining with methylene blue, surgical exploration, and operative microscope examination. Nevertheless, all of these are limited in providing a definitive diagnosis (6, 7). Thus, a crucial goal in endodontic research is to seek a more reliable method to diagnose dentinal microcracks.

Optical coherence tomographic (OCT) imaging is a noninvasive imaging method that provides high-resolution cross-sectional images of internal biological tissues (8). This technology works in a similar way to ultrasound but uses light instead of high-frequency sound (9) and is currently used in several clinical applications such as ophthalmology (10), cardiology (11), and dermatology (12). In dentistry, OCT imaging has been proposed as a powerful tool to evaluate caries (13), dental materials (14), periodontal structures (15), and oral cancer (16). Its application in the field of endodontics has also been studied, showing its ability to assess root canal anatomy and uncleaned areas after canal preparation (17).

Some studies have analyzed the use of OCT imaging for the diagnosis of root fractures (18, 19), suggesting the possibility of applying this technology in clinical practice. However, the evidence remains insufficient. Therefore, the purpose of the present study was to evaluate the ability of 2 OCT systems to detect dentinal microcracks in the apical portion of extracted human teeth.

Significance

The current available methods to diagnose cracked teeth are limited in providing a definitive diagnosis. This study showed that both OCT systems tested have the potential to become powerful tools for the diagnosis of dentinal microcracks.

From the *Department of Prosthodontics and Oral and Maxillofacial Surgery, Dental School, [†]Department of Nuclear Energy, and [‡]Department of Physics, Federal University of Pernambuco, Recife, Pernambuco, Brazil; and [§]Department of Land Resource Science, University of Guelph, Guelph, Ontario, Canada.

Address requests for reprints to Dr Brunna Paloma de Oliveira, Av Prof Moraes Rego s/n, Cidade Universitária, Recife, PE, Brazil 50670901.

E-mail address: bruna_paloma@msn.com

0099-2399/\$ - see front matter

Copyright © 2017 American Association of Endodontists.

<http://dx.doi.org/10.1016/j.joen.2017.01.019>

Basic Research—Technology

Materials and Methods

Sample Selection and Preparation

After approval from the ethics committee (Federal University of Pernambuco, Recife, Pernambuco, Brazil; protocol no. 1.575.380), 20 extracted human single-rooted mandibular incisors with no open apices, previous endodontic treatment, dental calculus, hypercementosis, internal/external resorption, or root caries were selected. The specimens were extracted for reasons not related to this study and stored in purified filtered water until use.

Initially, the crowns of the teeth were removed using a low-speed saw (Isomet; Buehler Ltd, Lake Bluff, IL) under water cooling. The working length was determined by introducing a size 10 K-file (Dentsply Maillefer, Ballaigues, Switzerland) into the canal until it reached the apical foramen. Root canals were then prepared using a Reciproc R40 (40/0.06) (VDW, Munich, Germany) file. The instrument was used in a reciprocating slow in-and-out pecking motion until the working length was reached. After 3 pecking motions, the flutes of the instrument were cleaned, and the canals were irrigated. Each canal was irrigated using a syringe and a 30-G needle with a total of 15 mL 1% sodium hypochlorite. The final irrigation was performed using 5 mL distilled water. Each instrument was used to prepare 4 canals only and was operated with a low-torque motor (X-Smart Plus, Dentsply Maillefer) set at the Reciproc program. A single operator completed all preparations.

Micro-computed Tomographic Scanning as the Gold Standard

After biomechanical preparation, the specimens presenting dentinal microcracks in the apical portion of the roots were identified by 2 observers using micro-computed tomographic (micro-CT) scanning (XTH225ST; Nikon, Tokyo, Japan) as the gold standard. Exposure parameters were set at an isotropic resolution of 9 μm , voltage of 49 kV, and current of 139 μA (20). Each root was mounted on the computer-controlled rotary stage of the micro-CT system so that the X-ray beam was perpendicular to the long axis of the root. Scanning was performed with a 360° rotation around the vertical axis with a rotation step of 0.12°. To reduce ring artifacts and minimize the beam hardening effect, an air calibration of the detector was performed before the scans. Images of each specimen were reconstructed with CT Pro 3D v.XT3.1.3 software (Nikon Metrology NV, Tring, UK). Then, VGStudio MAX v.2.2

software (Volume Graphics, Heidelberg, Germany) was used to smooth images by Gaussian filtering application and to provide cross sections of the internal structure of the roots.

Scanning with the OCT Systems

Subsequently, the apical portion of the roots was scanned using 2 OCT systems: spectral domain OCT (SD-OCT) (Callisto, Thorlabs, Newton, NJ) and swept-source OCT (SS-OCT) (OCS1300SS, Thorlabs).

For image generation, the OCT devices produce an interference pattern by splitting the beam of light source into 2 paths: the reference arm and the sample arm. After scanning the area of interest, the back-scattered light from the sample is recombined with light from the reference arm, digitized, and then analyzed in the Fourier domain to provide 2- and 3-dimensional images (21). In this study, the scanning light beam of the OCT systems was oriented parallel to the long axis of the teeth above the root apex.

The SD-OCT system uses a superluminescent diode with a central wavelength of 930 nm as a light source at a 1.2-kHz axial scan rate, 100-nm spectral bandwidth, and a maximum output power of 5 mW. Images generated by this system present a lateral resolution of 8 μm and an axial resolution of 7 μm in air, which is equal to 5.3 μm in tissue. Two frames are captured per second, and the maximum image depth is approximately 1.7 mm.

The SS-OCT system incorporates a tunable laser as a light source that repetitively sweeps the central wavelength of 1325 nm at a 16-kHz axial scan rate, >100-nm spectral bandwidth, and an average output power \approx 10 mW. Regarding imaging capability, this system captures 25 frames per second, with a lateral resolution of 25 μm and an axial resolution of 12 μm in air, which is equal to 9 μm in tissue. The maximum image depth is approximately 3 mm.

Image processing software (ImageJ, v.1.48; National Institutes of Health, Bethesda, MD) was used to generate cross-sectional images of the roots.

Evaluation of Microcracks

Three independent examiners blindly evaluated the OCT cross-sectional images ($N = 10,880$) obtained from the 1.6-mm apical portion of the roots. The examiners were endodontic specialists previously trained with OCT images generated from teeth that were not included in the study sample. Each examiner scored the presence or absence of microcracks in the teeth according to a 5-point scale as

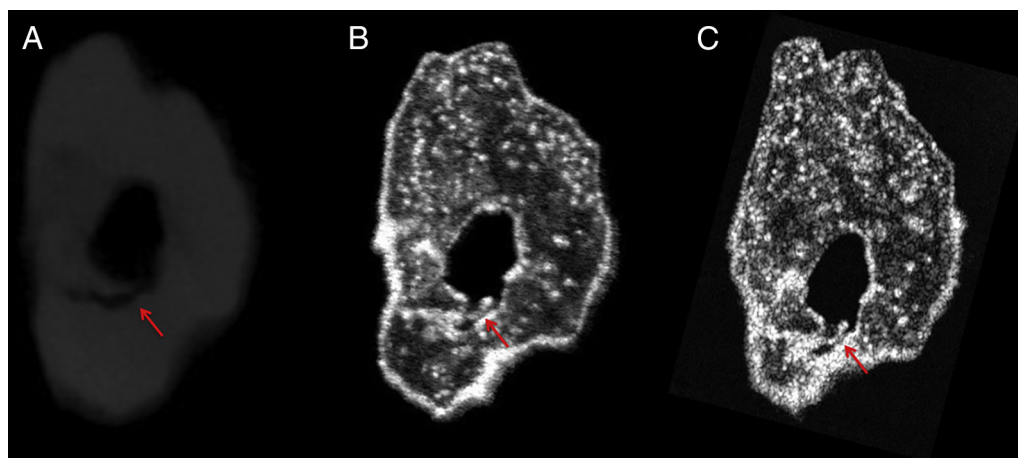


Figure 1. Representative cross-sectional images obtained from a mandibular incisor through (A) micro-CT, (B) SD-OCT, and (C) SS-OCT imaging. The crack line is indicated by the arrows.

Download English Version:

<https://daneshyari.com/en/article/5640797>

Download Persian Version:

<https://daneshyari.com/article/5640797>

[Daneshyari.com](https://daneshyari.com)