Second-generation Platelet Concentrate (Platelet-rich Fibrin) as a Scaffold in Regenerative Endodontics: A Case Series

Hengameh Bakhtiar, DDs, MSc, DoIBoE, Shahram Esmaeili, MD,* Setareh Fakhr Tabatabayi, DDS,* Mohammad Reza Ellini, BC Bio,* Mohammad Hossein Nekoofar, DDs, MSc, DoIBoE, PhD,†‡ and Paul M.H. Dummer, BDS, MScD, PhD, DDSc, FDSRCS(Ed), FHEA‡*

Abstract

Introduction: The purpose of this case series was to report the clinical and radiographic results of a pulp regenerative procedure using platelet-rich fibrin (PRF), a second-generation platelet concentrate, in immature teeth with necrotic pulps. **Methods:** Root canal revascularization using PRF was performed on 4 immature teeth with necrotic pulps. After access cavity preparation, the root canals were irrigated with low concentration sodium hypochlorite solution (1.5% sodium hypochlorite [20 mL/canal, 5 minutes]) and then irrigated with saline (20 mL/canal, 5 minutes). Equal proportions (167 mg) of ciprofloxacin, metronidazole, and cefaclor were mixed and diluted to a final concentration of 1 g/mL. Finally, the canal was sealed with 3–4 mm of a temporary restorative material, and patients were dismissed for 2 to 3 weeks. At the second appointment, 9 mL of the patient's whole blood was obtained and centrifuged to prepare a PRF clot. Canals were irrigated with 17% EDTA, and a sharp spreader was inserted beyond the apex. Then, the PRF clot was placed inside the root canals, and Biodentine (Septodont, Saint-Maur, France) was placed directly over the PRF. The teeth were restored permanently with glass ionomer cement and composite resin. **Results:** Clinical examinations revealed that all cases were asymptomatic at the recall appointments at 1, 3, 6, 12, and 18 months. Radiographs revealed resolution of the periapical lesions, further root development, and apical closure in all cases. **Conclusions:** On the basis of the short-term results up to 12 months, PRF clots acted as successful scaffolds for the regeneration of pulpal contents in immature teeth with necrotic pulps. *(J Endod 2016;■:1–8)*

Key Words

Open apex, platelet-rich fibrin, regenerative endodontics, revascularization, second-generation platelet concentrate

Significance

Endodontic treatment of immature teeth with necrotic pulps is challenging. Platelet-rich fibrin blood clots are suggested as a feasible alternative for regenerative endodontic protocols.

Endodontic treatment of immature teeth with necrotic pulps is challenging because of the thin dentinal walls of the roots and their susceptibility to fracture (1). Historically, calcium hydroxide was used for apexification of such teeth, but long-term calcium hydroxide treatment may disrupt the links between collagen fibers and hydroxyapatite crystals, which results in reduced micro-hardness and increased susceptibility to fracture (2–5). To overcome the drawbacks of calcium hydroxide apexification, 1-step apical closure techniques using mineral trioxide aggregate (MTA) were introduced (2). However, in this technique the root length and thickness of dentinal walls remains unchanged (6). Regenerative procedures are a feasible option for treatment of immature teeth with necrotic pulps especially since further development of the root apex and increased thickness of root walls are expected (7). In the past two decades, several reports have described clinical and radiographic evidence of successful regenerative procedures for treatment of such teeth (8). Induced bleeding and blood clots are integral parts of these procedures as they provide an appropriate scaffold and sufficient stem cells (9, 10). Platelet-rich plasma (PRP) has also been recommended as a potential scaffold for regenerative endodontic treatments (11, 12).

It has been shown that stimulated platelets release secretory granules that contain a variety of growth factors (13). PRP releases growth factors rapidly within 7 to 14 hours, which then declines (13). A second-generation platelet concentrate, platelet-rich fibrin (PRF), was developed by Choukroun et al (14). PRF has high concentrations of fibrin clots; no supplementary thrombin is needed during its preparation. PRF is formed during a gradual polymerization protocol that incorporates a higher concentration of cytokines into fibrins (13). Therefore, growth factors meshed in these fibrins are released more slowly between 7 and 14 days (13). In this case series, a regenerative procedure using PRF was performed on 4 immature single-rooted teeth

From the *Dental Material Research Center, Tehran Dental Branch, Islamic Azad University, Tehran, Iran; †Department of Endodontics, School of Dentistry, Tehran University of Medical Sciences, Tehran, Iran; and ‡Endodontology Research Group, School of Dentistry, College of Biomedical and Life Sciences, Cardiff University, Cardiff, UK.

Address requests for reprints to Dr Mohammad Hossein Nekoofar, School of Dentistry, Cardiff University, Cardiff CF10 3XQ, UK. E-mail address: Nekoofarmh@cardiff.ac.uk

0099-2399/$ - see front matter

Copyright © 2016 American Association of Endodontists.

http://dx.doi.org/10.1016/j.joen.2016.10.016

with pulp necrosis and then evaluated clinically and radiographically for up to 12 months.

Case Reports

Case Report 1

A 9-year-old female presenting with an acute apical abscess with a history of avulsion of an immature maxillary left central incisor was referred to a private endodontic practice. The first practitioner had provided a nonrigid splint for 10 days and performed a pulpectomy using nonsetting calcium hydroxide paste as a medicament. The patient had a normal medical history. The tooth was not discolored; periodontal probing depths of the maxillary incisors were within the normal limit, and was between 3 and 4 mm. Additionally, the tooth was not responsive to cold and electric pulp tests.

Radiographic examination revealed an immature root with an open apex but no evidence of periapical rarefaction (Fig. 1*A*). Regenerative endodontic treatment was initiated after obtaining consent from parents.

After obtaining profound anesthesia with 2% lidocaine with 1:80,000 epinephrine (Darupakhsh, Tehran, Iran), the tooth was isolated with a rubber dam and the access cavity modified. The working length of each canal was determined using an electronic root canal length measurement device (Root ZX; J Morita MFQ, Kyoto, Japan) confirmed by taking a digital periapical radiograph (Soredex, Tuusula, Finland). The root canal was irrigated copiously with 20 mL 1.5% sodium hypochlorite (NaOCl) solution for 5 minutes with a 23-G side-opened needle (Optimus, São Paulo, SP, Brazil) followed by 20 mL normal saline for 5 minutes (15). A limited amount of filing with #40 H-files (Mani; Utsunomiya, Tochigi, Japan) was performed in order to disrupt the biofilm and roughen the dentinal walls without widening the canal. The canal was then dried with paper points. The internal walls of the pulp chamber were sealed with a dentin-bonding agent (3M ESPE Dental Products, St Paul, MN) to minimize the risk of staining. Then,

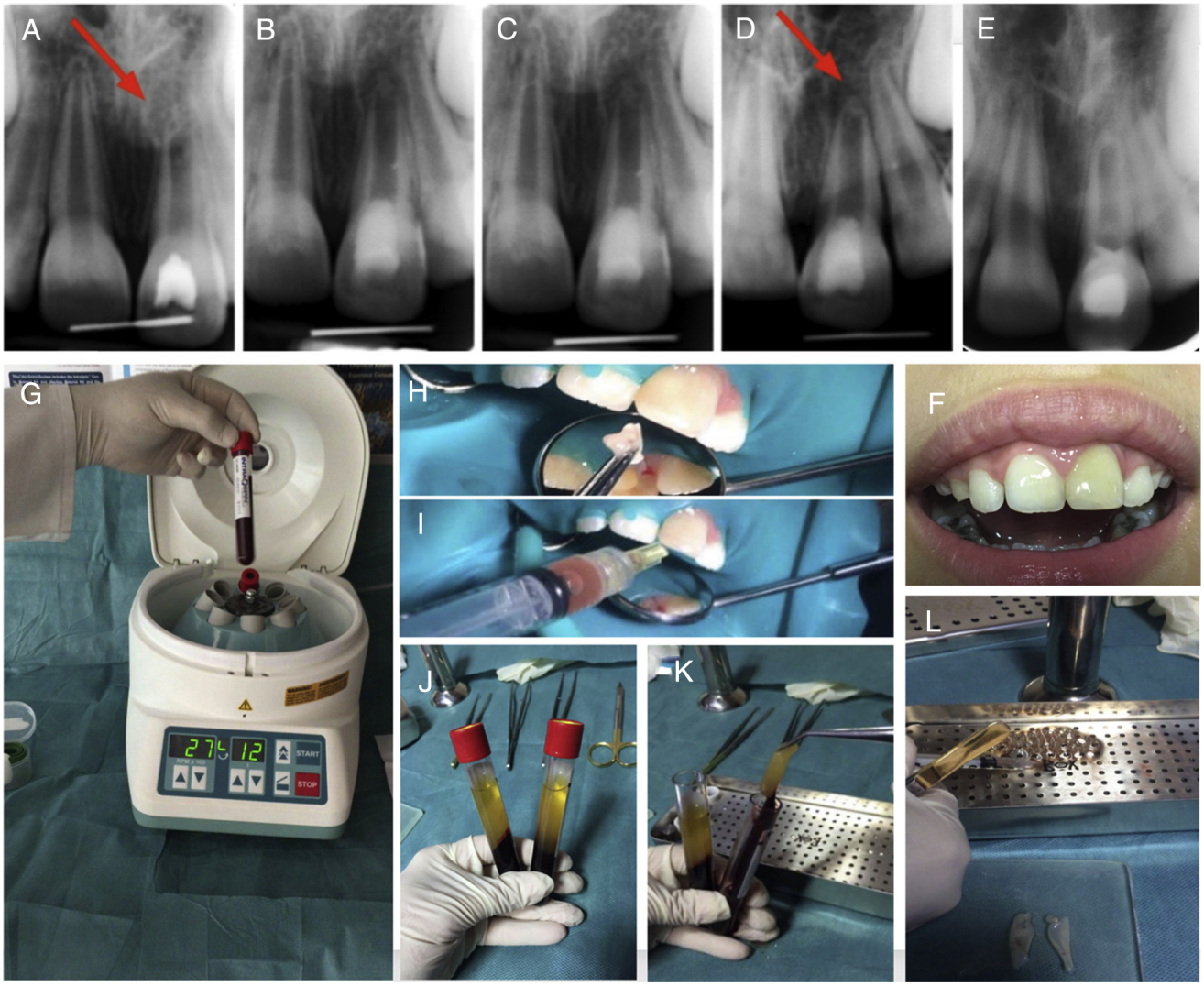

Figure 1. (*A*) A 9-year-old girl with a history of avulsion of the left maxillary central incisor with a periapical abscess and a necrotic tooth with an open apex (*red arrow*). Radiographs taken at the (*B*) 1-month, (*C*) 3-month, and (*D*) 6-month follow-ups revealed signs of appreciable complete apical closure after 6 months (*red arrow*). (*E*) The 18-month follow-up indicated further apical closure. (*F*) Minimal discoloration after 18 months was noticeable. (*G*) The sterile tubes were centrifuged at 2700 rpm for 12 minutes. (*H*) The small pieces of PRF clot were placed in the root canal. (*I*) The root canal was irrigated with the liquid in which the PRF clot was floated. (*J* and *K*) Three parts were formed in tubes, and the intermediate layer of PRF clot was collected. (*L*) The PRF clot was rolled over on itself on the glass slab. The small piece of wire placed in the radiographs are intended for measurement software calibrations.

Download English Version:

https://daneshyari.com/en/article/5640956

Download Persian Version:

https://daneshyari.com/article/5640956

Daneshyari.com