

Available online at www.sciencedirect.com

ScienceDirect

journal homepage: www.elsevier.com/locate/jobcr

Case Report

Periosteum as a lateral pedicle graft for the treatment of single tooth root recession: A novel approach



Avadhesh Kumar^{a,*}, Shalini Kaushal^b, Neelu Verma^c, Deepti Chandra^d

^a Reader, Department of Periodontology, Career Post Graduate Institute of Dental Sciences & Hospital, Lucknow, U.P., India

^b Associate Professor, Department of Periodontology, Faculty of Dental Sciences, K.G. Medical University, Lucknow, U.P., India

^c Senior Lecturer, Department of Periodontology, Career Post Graduate Institute of Dental Sciences & Hospital, Lucknow, U.P., India

^d PG Student, Department of Periodontology, Career Post Graduate Institute of Dental Sciences & Hospital, Lucknow, U.P., India

ARTICLE INFO

Article history:

Received 25 September 2015

Accepted 4 December 2015

Available online 13 January 2016

Keywords:

Gingival recession

Periosteum

Lateral pedicle graft

ABSTRACT

The treatment of gingival recession defects is indicated for esthetic and functional reasons to reduce root sensitivity, to remove muscle pull, to create or augment keratinized tissue, and to prevent disease progression. The presence of sufficient amount of periosteum adjacent to gingival recession defects makes it a suitable graft. The adult human periosteum is a highly vascular connective tissue with immense regenerative potential. It contains fibroblasts, osteogenic progenitor cells, and stem cells as a result of which it has the ability to differentiate into fibroblast, osteoblast, chondrocytes, adipocytes, and skeletal myocytes. The tissue provided by these cells includes cementum with periodontal ligament fibers and bone. Therefore, in the present case, periosteum has been used as a lateral pedicle graft for the coverage of the single tooth gingival recession (mandibular central incisor). The procedure is justified by the evidence that periosteum is capable of proliferation and osteogenesis after injury.

© 2015 Craniofacial Research Foundation. All rights reserved.

Key messages:

- Periosteum can be used as an autogenous graft to cover the gingival recession which is capable of proliferation and osteogenesis after injury.

1. Introduction

By definition, exposure of the tooth by apical migration of gingiva is called gingival recession or atrophy which may be physiologic or pathologic. However, the concept of physiologic recession is not accepted at present. Gingival recession is a

* Corresponding author.

E-mail address: davadhesh_2007@yahoo.co.in (A. Kumar).

<http://dx.doi.org/10.1016/j.jobcr.2015.12.003>

2212-4268/© 2015 Craniofacial Research Foundation. All rights reserved.

common finding and its prevalence, extent, and severity increases with age and more prevalent in males. Gingival recession leads to exposed root surface which are susceptible to caries, sensitive to thermal stimuli, and also abrasion and erosion of cementum occur. Hyperemia of pulp and associated symptoms may be present.

Multiple techniques have been developed to achieve predictable root coverage.¹ Gingival augmentation procedure can be performed either apical to recession or coronal to recession through multiple procedures. The objective of developing a new technique is to increase the predictability and to reduce patient discomfort including number of surgical sites and also trying to provide highest level of patient satisfaction in terms of esthetics, color, and blending of grafted tissue.² A graft with its own blood supply, which can be harvested from the adjacent area of the recession defect and have the potential for promoting the regeneration of the lost periodontal tissue, may be the most suitable graft for the root coverage. The periosteum is a highly vascularized structure and is known to contain fibroblast and their progenitor cells and stem cells. In all the age groups, cells of periosteum has the ability to differentiate into fibroblast, osteoblast, chondrocytes, adipocytes, and skeletal myocytes and therefore may lead to the production of cementum with periodontal ligament fibers and bone.³ In consideration with the above feature of periosteum in the present case, periosteum has been used as a lateral pedicle graft for single tooth gingival recession coverage.

2. Case history

A 22-year-old male patient reported to the department of Periodontology with the complaint of visibility of root of the lower front teeth and bleeding from gums since 5 months. After thoroughly reviewing the patient clinical history, taking out a detailed examination and on the basis of X-ray findings, a diagnosis of chronic generalized gingivitis with localized periodontitis in the region of mandibular incisors was made. Gingival recession (Miller's class III) with respect to left mandibular central incisor was observed (Figs. 1 and 2). It was decided to carry out surgical procedure for the management of gingival recession.

Initial therapy included patient education and motivation for the maintenance of good oral hygiene and thorough scaling and root planing. A complete blood profile was done in which

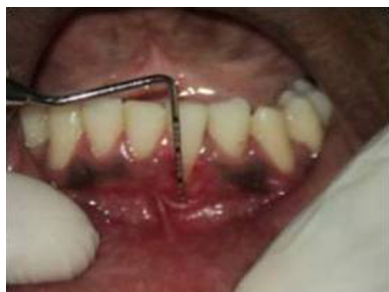

Fig. 1 – Preoperative.

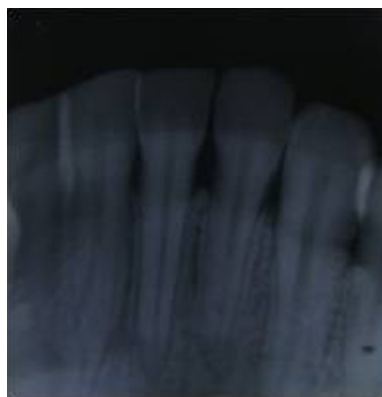


Fig. 2 – IOPA X-ray.

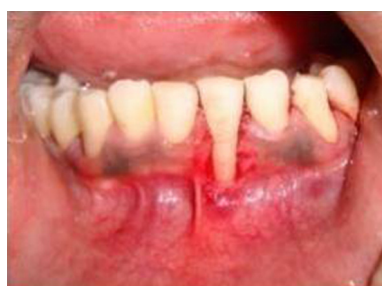

Fig. 3 – Recipient bed.

all parameters were in normal range. The patient was recalled after two weeks for surgery.

3. Surgical method

The entire procedure was explained to the patient and his family in advance. A written consent was obtained. On the day of surgery, the patient was made comfortably seated on the dental chair. Part preparation was done using 5% povidone iodine solution. After giving local anesthesia, the exposed root surface was thoroughly planed to remove any deposits on the surface. Recipient bed was prepared by removing 1 mm of gingival collar of tissues around the recession area with the help of no. 15 blade (Fig. 3). Two vertical releasing incisions were made mesial and distal to left mandibular lateral incisor (periosteum donor site) to designate the width of the flap. A partial thickness flap was reflected beyond the mucogingival junction (Fig. 4). A blunt dissection was performed below the partial thickness flap to reflect the periosteum and overlying connective tissue from bone (Fig. 5). The periosteum was shifted laterally on the left mandibular central incisor (recipient site) and after stabilizing the autogenous periosteal pedicle graft, sutures were placed (Fig. 6). The partial thickness flap was placed back at its original position and sutured (Fig. 7). The surgical area was covered with periodontal dressing (Fig. 8). Post-surgical instructions were given to the patient. The patient was advised not to brush the operated area and rinse the oral cavity with 10 ml aqueous 0.2% chlorhexidine

Download English Version:

<https://daneshyari.com/en/article/5641353>

Download Persian Version:

<https://daneshyari.com/article/5641353>

[Daneshyari.com](https://daneshyari.com)