Opening a Window into Living Tissue

Histopathologic Features of Confocal Microscopic Findings in Skin Tumors

Juliana Casagrande Tavoloni Braga, MD, PhD[a],
Raquel de Paula Ramos Castro, MD[a],
Tatiana Cristina Moraes Pinto Blumetti, MD[a],
Fernanda Berti Rocha Mendes, MD[a],
Juliana Arêas de Souza Lima Beltrame Ferreira, MD[a],
Gisele Gargantini Rezze, MD, PhD[b,*]

KEYWORDS

• Reflectance confocal microscopy • Histopathology • Skin tumors • Melanoma • Melanocytic nevi • Actinic keratosis • Squamous cell carcinoma • Basal cell carcinoma

KEY POINTS

- Several histopathologic features of skin tumors can be characterized individually through reflectance confocal microscopy (RCM) examination.
- As a result, RCM has significant correlation with histopathologic final diagnosis.
- RCM can improve noninvasive in vivo diagnosis of skin tumors and prevent biopsy of benign lesions.

INTRODUCTION

The knowledge of histopathology and in vivo reflectance confocal microscopy (RCM) correlation has several potential applications.[1,2] First, it enables the skin tissue evaluation of specific sites for a punch biopsy, improving its diagnostic accuracy and reducing the need of repetitive investigation in heterogeneous lesions. Second, it may differentiate skin tumors and reassure confidence in clinical diagnosis of doubtful lesions.[3,4]

Notably, RCM evaluation of a given lesion is made in sections parallel to skin (en face), where each section is at a different skin depth.[1] Oppositely, conventional histopathology sections are made perpendicular to the skin, and each section shows different depths of a given lesion.[1] This technical difference makes the histopathology-RCM correlation challenging for the general pathologist/dermatologist, who is used to studying the skin according to perpendicular sections.[1] Braga and colleagues[5] described the value of transverse histologic sections as a tool to better understand the structures observed in dermoscopy and RCM.

In this article, the most common skin tumors observed in clinical practice as seen on RCM are described.

Disclosure Statement: All authors have seen and agree with the contents of the article and there is no financial interest to report.

[a] Cutaneous Oncology Department, AC Camargo Cancer Center, Rua Prof. Antônio Prudente, 211-Liberdade, Sao Paulo, Sao Paulo 01509-010, Brazil; [b] DermaImage associates, Avenida General Furtado do Nascimento, 740, cj. 24. São Paulo, SP 05465-070, Brazil
* Corresponding author.
E-mail address: ggrezze@hotmail.com

Dermatol Clin 34 (2016) 377–394
http://dx.doi.org/10.1016/j.det.2016.05.002
0733-8635/16/$ – see front matter © 2016 Elsevier Inc. All rights reserved.

Table 1
Reflectance confocal microscopy features for nevi and correlation with histopathology

RCM	Histopathology
Ring pattern	Junctional nevus: individual melanocytes at the DEJ, elongated papillae, and lentiginous pattern
Meshwork and junctional thickening (enlargement of the junctional space)	Junctional nevus: junctional nests located at the tips of epidermal ridges
Meshwork and junctional thickening with junctional and dermal nests	Compound nevus: nests at the DEJ and papillary dermis (more superficial)
Meshwork with junctional and dermal nests, predominantly with clod pattern	Compound nevus: nests at the DEJ, papillary dermis, and reticular dermis (deeper)
Dense or dense and sparse nests	Dermal nevus: nevus cells nests at the dermis

CONFOCAL MICROSCOPY CORRELATION IN MELANOCYTIC SKIN TUMORS

Melanocytic nevi are seen in histopathology as a benign proliferation of nevus cells with monomorphic pattern.[6–8] When the proliferation occurs initially at the epidermis, more precisely at the dermal-epidermal junction (DEJ), it is known as junctional nevi.[6–8] On the other hand, when the nevus cells are located at the dermis, the lesion is classified as dermal nevus.[6–8] Finally, when it is located in both compartments (epidermis and dermis), it is named compound nevus.[6–8]

Junctional Nevi

Junctional nevi can be seen in RCM with 2 patterns: ringed and/or meshwork[8–11] (**Table 1**).

The ringed pattern is the most commonly observed. It presents as edged papillae with intense bright basal keratinocytes surrounding a dark center. In histopathology, it corresponds to a lentiginous proliferation of single melanocytes at the DEJ[8–11] (see **Table 1**; **Fig. 1**).

In the meshwork pattern, a proliferation of nevus cells organized in nests is seen at the interpapillary space by histopathology and, consequently, by RCM as well[8–11] (see **Table 1**; **Fig. 2**).

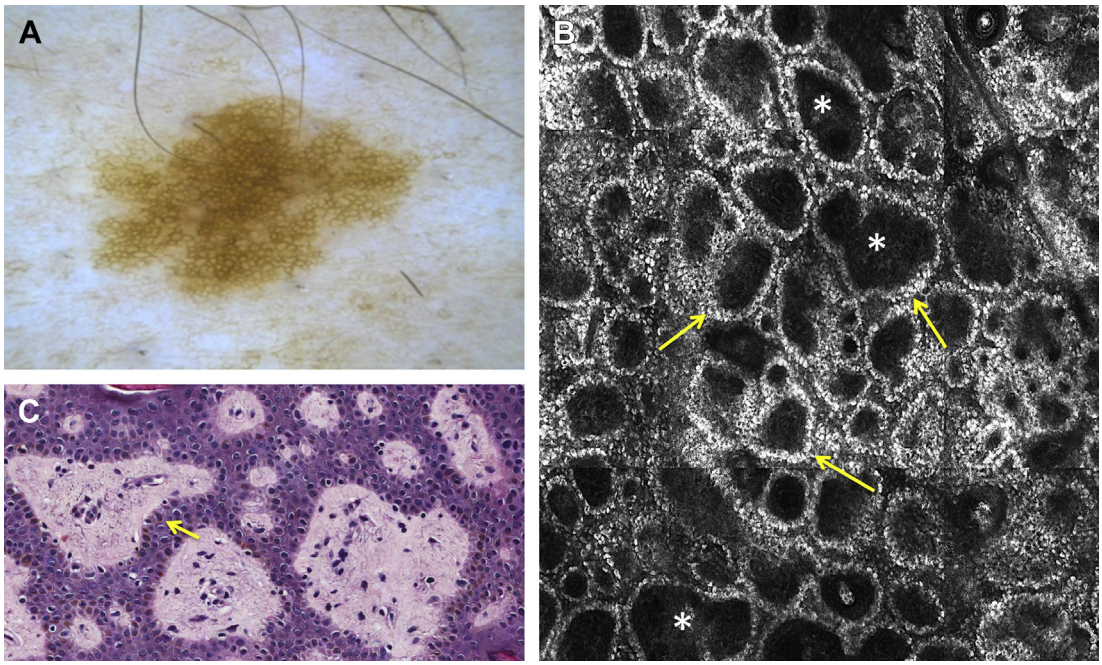

Fig. 1. Junctional nevus. (*A*) Dermatoscopy shows typical network. (*B*) RCM mosaic image (1 × 1.25 mm) at the level of the DEJ shows ringed pattern: rings of bright polygonal cells (*arrows*) surrounding roundish to oval dark areas corresponding to dermal papillae at DEJ (*asterisks*). (*C*) Histopathologic transverse section shows isolated melanocytes arranged around the dermal papillae (*arrow*) (H&E, original magnification × 100).

Download English Version:

https://daneshyari.com/en/article/5645839

Download Persian Version:

https://daneshyari.com/article/5645839

Daneshyari.com