Injury, Int. J. Care Injured 47 (2016) 2507–2511

Contents lists available at ScienceDirect

Injury

journal homepage: www.elsevier.com/locate/injury

Original article

3D surgical printing and pre contoured plates for acetabular fractures

Francisco Chana-Rodríguez, Ph.D., M.D., Dr[a,*], Rubén Pérez Mañanes, Ph.D., M.D.[a], José Rojo-Manaute, Ph.D., M.D.[b], Pablo Gil, M.D.[a], José María Martínez-Gómiz, M.D.[c], Javier Vaquero-Martín, Ph.D., M.D.[a]

[a] From the Department of Traumatology and Orthopaedic Surgery, General University Hospital Gregorio Marañón, C/Doctor Esquerdo, 46, 28007, Madrid, Spain
[b] From the Department of Traumatology and Orthopaedic Surgery, Medcare Orthopaedics and Spine Hospital, Dubai, United Arab Emirates
[c] From the Department of Traumatology and Orthopaedic Surgery, University Hospital Infanta Leonor, Madrid, Spain

ARTICLE INFO

Article history:
Accepted 28 August 2016

Keywords:
Rapid prototyping
3D printing
Preoperative planning
Acetabular fractures
Models
Contour
Plates

ABSTRACT

We describe the methodical and possibilities of 3D surgical printing in preoperative planning of acetabular fractures showing a case of a 45-year-old with an associated transverse fracture of the left acetabulum with posterior wall fracture, with multiple fragments, and posterior ipsilateral hip dislocation, defending the do it your-self mode.

© 2016 Elsevier Ltd. All rights reserved.

Introduction

The anatomy of the pelvis and acetabulum has been extensively studied, however the correct identification of the various fracture patterns of this structure remains difficult for orthopedic surgeons. When faced with a broken pelvis, choosing a correct surgical approach and obtaining an anatomic reduction of the bone fragments are key elements, especially when the acetabulum is affected.

Preoperative planning is essential to achieve a good result. Preoperative 3D modeling allows more effective diagnosis and simulates the surgical procedure [1]. In recent years, advances in three-dimensional reconstruction of radiological studies have provided the tools for allowing virtual surgical planning [2].

The technology of three-dimensional printing, also known as “additive manufacturing” and “rapid prototyping” has been available for the past 30 years, providing multiple applications in clinical practice for highlighting the preoperative planning, teaching or communicating with patients. Rapid Prototyping (RP) is a term referring to a series of addition-technologies based on the construction of a physical model, layer by layer, as a replica of a virtual model [3]. The RP models obtained are accurate reproductions of the virtual model obtained by Computed Tomography (CT), reaching submillimetric accuracy [4]. These models facilitate the diagnosis, improve interobserver agreement when classifying a fracture [5] and provide tactile feedback for allowing preoperative planning of the surgical approach on the virtual model (including the reproduction of the design and size of the hardware that would be used for osteosynthesis during surgery) [6]. This technology is an example of WYSIWYG (what you see is what you get).

The cost of RP is one of the potential disadvantages and is determined by the amount of material used, the cost of the 3D printer and the cost of software licenses [7]. The cost of printing a model is between 500 and 900 euros [8]. The manufacturing cost must be added to this cost; however, thanks to the marketing of 3D printers for home use, this technology is now available to everyone, making it economically affordable (i.e. autonomous). Nowadays, in a true do it yourself (DIY) style, accurate reproductions can be obtained at a minimum cost using “open-source” tools.

Our goal for this study was to show a new methodology for applying 3D technology thru a DIY processing in the field of orthopedic surgery, analyzing advantages and potential drawbacks. We describe the DIY process thru a clinical case that underwent surgical treatment at our Department.

* Correspondence to: Hospital General Universitario Gregorio Marañón, C/de la Cañada, N°4, 6°A, 28030, Madrid, Spain.
E-mail address: chanaphd@yahoo.es (F. Chana-Rodríguez).

http://dx.doi.org/10.1016/j.injury.2016.08.027
0020-1383/© 2016 Elsevier Ltd. All rights reserved.

Materials and methods

We report the case of a 45-year-old who was transferred to our emergency department from another hospital after suffering a car accident a few hours before, with the diagnosis of a fracture-dislocation of the left acetabulum. On examination, the affected leg showed apparent shortening and internal rotation upon inspection with functional impairment but without neurovascular compromise.

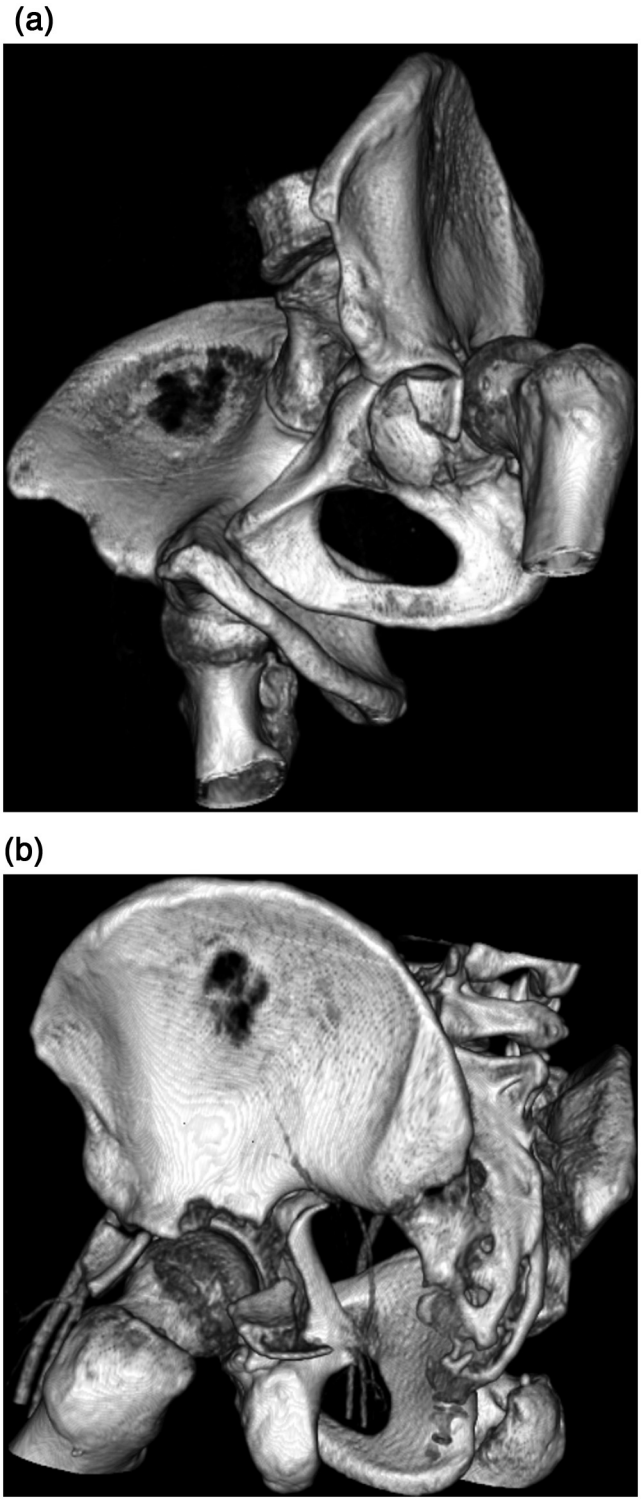

Fig. 1. a. CT scan image after 3D volumetric rendering at the admission showing transverse fracture of the left acetabulum with posterior wall fracture and posterior ipsilateral hip dislocation. b. CT scan image after close reduction.

CT scan investigation showed an associated transverse fracture of the left acetabulum with posterior wall fracture, with multiple fragments, and posterior ipsilateral hip dislocation [9] (Fig. 1a). On arrival, we conducted an emergent closed reduction under sedation, after which the joint was stable. Once stabilized, a new CT scan was requested for assessing joint congruency and the absence of intra-articular incarcerated fragments. The images revealed fragments displacement that indicated an open reduction and internal fixation (Fig. 1b).

The preoperative planning was performed by pre-molding synthesis plates on a 3D printed mold obtained from the CT scan. The process began with the analysis of the DICOM study of the standard multislice CT (Philips Brilliance 64, 0.625 mm slice thickness) performed to the patient at the time of admission.

The study was imported into the radiological postprocessing software GNU open-source OsiriX, using a Macintosh personal computer (Apple Computers, Cupertino, CA). After segmentation for subtracting the sacrum and both femurs, 3D surface rendering was applied to the healthy hemipelvis under specular mode (inversion of the X axis) to obtain the isosurface that was then exported as a 3D object in STL format. Following other author's recommendations [10], the inspection and correction of the 3D surface were performed using MeshLab V1.3.3.®.

The mold impression was made with the DaVinci 1.0 printer model (XYZ Printing) under FDM technology (Fused Deposition Modeling), with a retail price of 390 euros. White thermoplastic 1.75 mm diameter ABS (acrylonitrile butadiene styrene) was used. The standard configuration (0.3 mm, 10% normal speed) was applied. The program Meshmixer 2.4.® was used for facilitating proper printing, for achieving optimal positioning on the printing tray and for designing supports that increased stability during printing. In this case, for not altering the anatomy of the model, the fracture was represented directly on the model with indelible ink without fracturing the material.

After obtaining the printed hemipelvis (Fig. 2a), we proceeded with the implant size selection (pelvic Matta system, Stryker®) that matched the characteristics of the fracture and the approach to be performed. Plate pre contouring was performed using the templates available on the instrument set, adapting their shape to the anatomical contours. These templates were contoured over the plastic model for then reproducing these plate models in the final plates with the aid of standard plate-benders during 25 min. A MPS curved plate of 8 holes was used for the posterior wall and a MPS straight plate of 8 holes for the posterior column (Fig. 2b). The consistency of the printed model allowed the use of surgical instruments directly on it. After verifying the suitability of these plates, in relation to size and anatomical adaptation to the chosen position, they were labeled and prepared for sterilization thru standard circuits.

The time spent for post-processing the image for obtaining the STL file was 18 min. The inspection and repair of the virtual model, its positioning and software editing as well as the slicing and calculations of the G-code with the instructions per layer (where, when and how fast the plastic would be deposited) took 24 min. The time for printing this configuration was 11 h.

The plastic consumption for printing the model was 295 g of ABS, which corresponded to the 260 g hemipelvis and 35 g of disposable material used in the media. The price of a 600 g cartridge is 24 euros, so we printed our model for less than 12 euros.

On the following day after contouring the plates, a Kocher-Langenbeck approach was performed in our patient for proceeding with an open reduction of the fracture and a synthesis with interfragmentary screws and the pre contoured plates [11]. No

Download English Version:

https://daneshyari.com/en/article/5652946

Download Persian Version:

https://daneshyari.com/article/5652946

Daneshyari.com