



<http://dx.doi.org/10.1016/j.jemermed.2016.10.011>

## **Clinical Communications: Pediatric**

### **DISK BATTERY INGESTION IN A TODDLER: LESS THAN MEETS THE EYE**

Ian Schreiner, MD and William Bonadio, MD

Maimonides Medical Center, Brooklyn, New York

Reprint Address: William Bonadio, MD, Maimonides Medical Center, 113 Columbia Heights, Brooklyn, NY 11201

**□ Abstract—Background:** Pediatric foreign-body ingestions are commonly managed by emergency physicians. Risk assessment and specific intervention are dependent on the nature and location of the foreign body. Radiographic evaluation is usually necessary to help define the clinical situation. **Case Report:** We present an interesting case of presumed ingestion of several disk batteries by a toddler with an unexpected outcome, reviewing aspects of this clinical problem and highlighting potential pitfalls in medical decision making. **Why Should an Emergency Physician Be Aware of This?:** Pediatric foreign-body ingestions are commonly managed in the emergency department, and timely and accurate intervention is dependent on correct defining and localization of the foreign body. This case illustrates potential pitfalls in this evaluation. © 2016 Elsevier Inc. All rights reserved.

**□ Keywords—**disk battery ingestion; caustic ingestion; esophageal foreign body

#### **INTRODUCTION**

Foreign-body ingestion is commonly encountered by emergency physicians who care for children. Most ingestions are innocuous and commonly self-resolve; an exception to this is the ingestion of a disk battery (DB), which can cause serious tissue injury due to its caustic properties. The timely and accurate localization of an ingested DB, and its extraction when lodged in nasal/otic/esophageal lumens, is essential to maximizing clinical outcome.

#### **CASE REPORT**

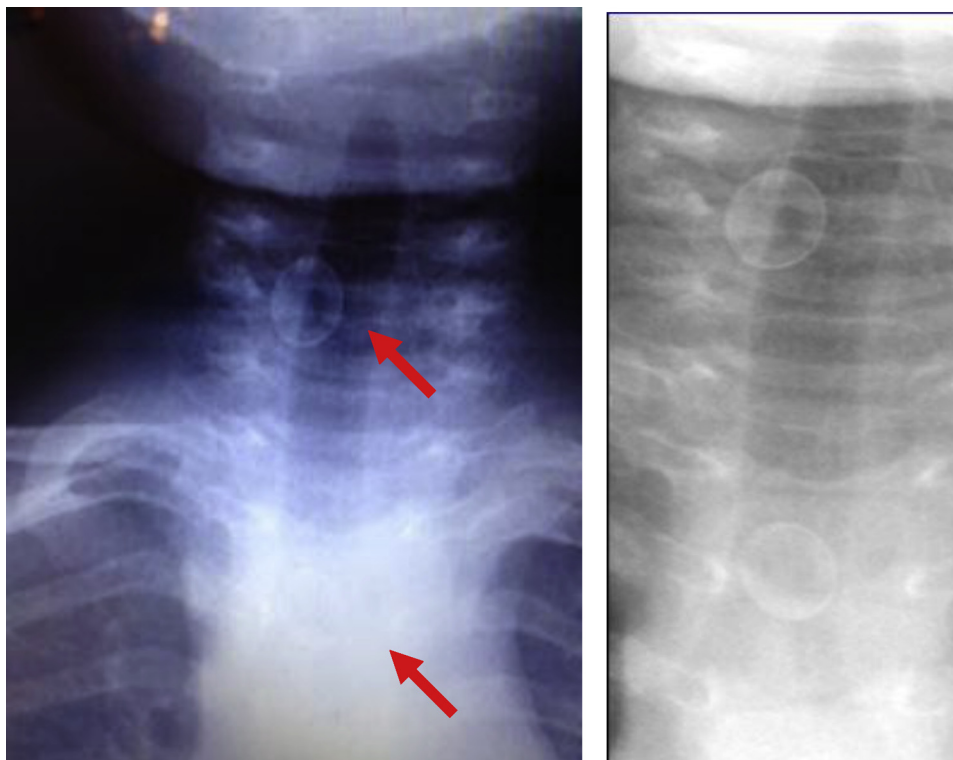
A 15-month-old female presented to the emergency department (ED) with caretaker suspicion of DB ingestion. The parents reportedly witnessed the child playing with several DBs, which were loose on the floor; they saw the patient ingest one, possibly two; and then swallow. After a brief period of gagging, there were no symptoms noted afterward.

They were transported by Emergency Medical Services to the ED within the hour. At triage, vital signs were within normal limits and physical examination was unremarkable, revealing no sign of drooling, dysphagia, stridor, oral burns, respiratory distress/cough, wheezing, or any discomfort. There was no foreign body visualized in either the oral cavity or nasal/external otic canals. An anteroposterior (AP) neck/chest x-ray (CXR) study was expeditiously obtained minutes after triage, which revealed the presence of several round-shaped, metallic-density, foreign objects in the midline of the lower neck/upper thoracic region ([Figure 1](#)); their shape, the circumferential increased metallic density at the perimeter (“double-rim” sign), and anatomic location indicated that these were multiple ingested DBs lodged in the esophagus.

A STAT consultation was initiated with both pediatric ear, nose, and throat (ENT) and anesthesia in anticipation of requisite immediate foreign-body extraction in the operating room. After carefully reviewing the radiographs, an astute ENT resident noted that the presumed foreign bodies were of lesser radiodensity

RECEIVED: 16 June 2016; FINAL SUBMISSION RECEIVED: 2 September 2016;

ACCEPTED: 3 October 2016



**Figure 1. Two double-density radiopaque circular metallic objects (arrows).**

than would be expected of a DB. Upon further questioning, the radiology technician who performed the imaging recalled that the patient was not completely disrobed before performing the study. Inspection of the patient's shirt revealed the presence of buttons (Figure 2).

All upper body clothing was removed, and repeat AP CXR was performed, including neck, thorax, and abdomen, and showed no radiopaque objects present above the diaphragm (Figure 3); it did, however, reveal a single round-shaped, metallic-density, foreign body actually consistent with a DB present in the lower intestine. The patient was discharged from the ED with expectant management and close follow-up.

## DISCUSSION

DBs are relatively small, coin-shaped batteries used to power watches, calculators, toys, and hearing aids. Although accounting for only about 2% of all foreign-body ingestions, there were nearly 6,000 DB exposures resulting in ED evaluation in 2009 (1,2). Up to 90% of patients are asymptomatic (2). Ingestion has been associated with serious complications, and even fatal outcomes, when lodged for a period of time in the lumen of an orifice (nasal, otic, esophageal) (2,3).

DBs are produced in a variety of sizes; although most cases of esophageal injury are associated with cell

diameter  $\geq 20$  mm, DB size cannot be used to universally predict risk for injury (2). Also, even a spent cell can still maintain considerable residual voltage (2). DBs



**Figure 2. Buttons on patient's shirt; size relative to U.S. nickel coin.**

Download English Version:

<https://daneshyari.com/en/article/5653576>

Download Persian Version:

<https://daneshyari.com/article/5653576>

[Daneshyari.com](https://daneshyari.com)