

Case report

Multiorgan *Echinococcus* infection: Treatment of an immigrant in the United States



Kevin J. Zhang^{a,*}, Michael Schaldenbrand^b, Fuad Turfah^b

^a Wayne State University School of Medicine, 540 E. Canfield St, Detroit, MI 48201, United States

^b Beaumont Hospital, 18101 Oakwood Blvd, Dearborn, MI 48124, United States

ARTICLE INFO

Keywords:

Surgical management
Immigrant

ABSTRACT

We discuss the clinical presentation and management of a 36-year-old woman presenting with a 12-year history of recurrent hydatid disease, a disease caused by *Echinococcus granulosus* and other *Echinococcal* species, which is rarely seen in the contiguous United States. She has had multiple procedures since her diagnosis in 2005 and is still closely being followed for possible disease recurrence.

Introduction

Echinococcus is a parasite non-endemic to the United States. It is a difficult infection to manage and treat due to its potential for extensive involvement and high rate of recurrence. This is further complicated by physicians' lack of familiarity with hydatid disease, making it difficult for patients to receive proper and quality management of their disease.

Case report

The patient was born in Iraq with a history of traveling to Syria, Saudi Arabia, Turkey, and Mali. The exact origin of her infection has not been established. She recalls commonly coming in contact and playing with dogs as a child in Iraq and recounts her complete immersion into the lifestyle of the natives of Mali, including consuming their food and drink, which may have been a risk factor for her condition.

The diagnosis was made in 2005 after arriving to the emergency department at Oakwood Hospital in Dearborn, MI due to gradually progressive dyspnea and pleuritic chest pain. On arrival, her oxygen saturation was alarmingly low. Chest radiographs revealed a large right pleural effusion with atelectasis. Hydatid cysts were found in her liver and spleen on CT scan. CT scan demonstrated no hydatid cysts in the chest, so CT-guided thoracentesis was indicated at this time. Thoracocentesis revealed eosinophilic exudative fluid with no evidence of hydatid disease in the chest. The pleural effusion was determined to be sympathetic to diaphragmatic irritation from liver involvement. It was determined that the patient's infection was due to *E. granulosus* after she was found to have an elevated *Echinococcus* titer. The patient began a six-month course of 400 mg albendazole twice daily, which she

took regularly. She declined surgery at that point.

In 2006, the patient did not have significant improvement and was recommended surgery again, but she declined. Within a year, she presented to the ED complaining of severe abdominal pain due to hydatid cyst rupture, confirmed by CT. CT also revealed extensive hydatid disease in the omentum, spleen, liver, and retroperitoneum. Due to the severity of the hydatid disease (Fig. 1A), she agreed to surgery at this time. A surgeon from Lebanon with experience with hydatid disease performed the surgery. Over 100 cysts were discovered within the abdomen. Omentectomy was performed, splenic cysts were aspirated and injected with 5% saline, and multiple cysts in the liver were drained and partially excised. There were also retroperitoneal hydatid cysts on the right that were excised. She was placed on the same regimen of 400 mg albendazole twice daily for 60 days postoperatively.

On CT, it was found that her hydatid cysts had recurred in the spleen (Fig. 1B) and pelvis seven years later during a follow-up appointment. The surgeon once again attempted to preserve the spleen by aspirating the cysts and injecting hypertonic saline again. At this time, pelvic cyst removal and splenic cyst drainage was performed. Within the year, the patient's hydatid cysts recurred in the pelvis, spleen, and diaphragm. She was recommended to consult a gynecologist oncologist due to pelvic involvement of cysts who recommended a total hysterectomy and bilateral salpingo-oophorectomy (TAH-BSO) (he informed her that he was unfamiliar with the disease). She returned to her previous surgeon and was told that a TAH-BSO may be unnecessary. At this time, the patient underwent a laparotomy with lysis of adhesions with splenectomy and drainage of multiple perisplenic, pelvic, and diaphragmatic cysts in addition to a partial gastrectomy due to extensive involvement. The patient was given appropriate vaccinations and prophylactic penicillin.

* Corresponding author. Present address: 4500 Cass Ave, Detroit, MI 48201, United States.

E-mail addresses: kezhang@med.wayne.edu (K.J. Zhang), Michael.Schaldenbrand@beaumont.org (M. Schaldenbrand), fturfah@aol.com (F. Turfah).

<http://dx.doi.org/10.1016/j.idcr.2017.05.011>

Received 31 March 2017; Received in revised form 22 May 2017; Accepted 23 May 2017

2214-2509/ © 2017 The Authors. Published by Elsevier Ltd. This is an open access article under the CC BY-NC-ND license (<http://creativecommons.org/licenses/by-nc-nd/4.0/>).

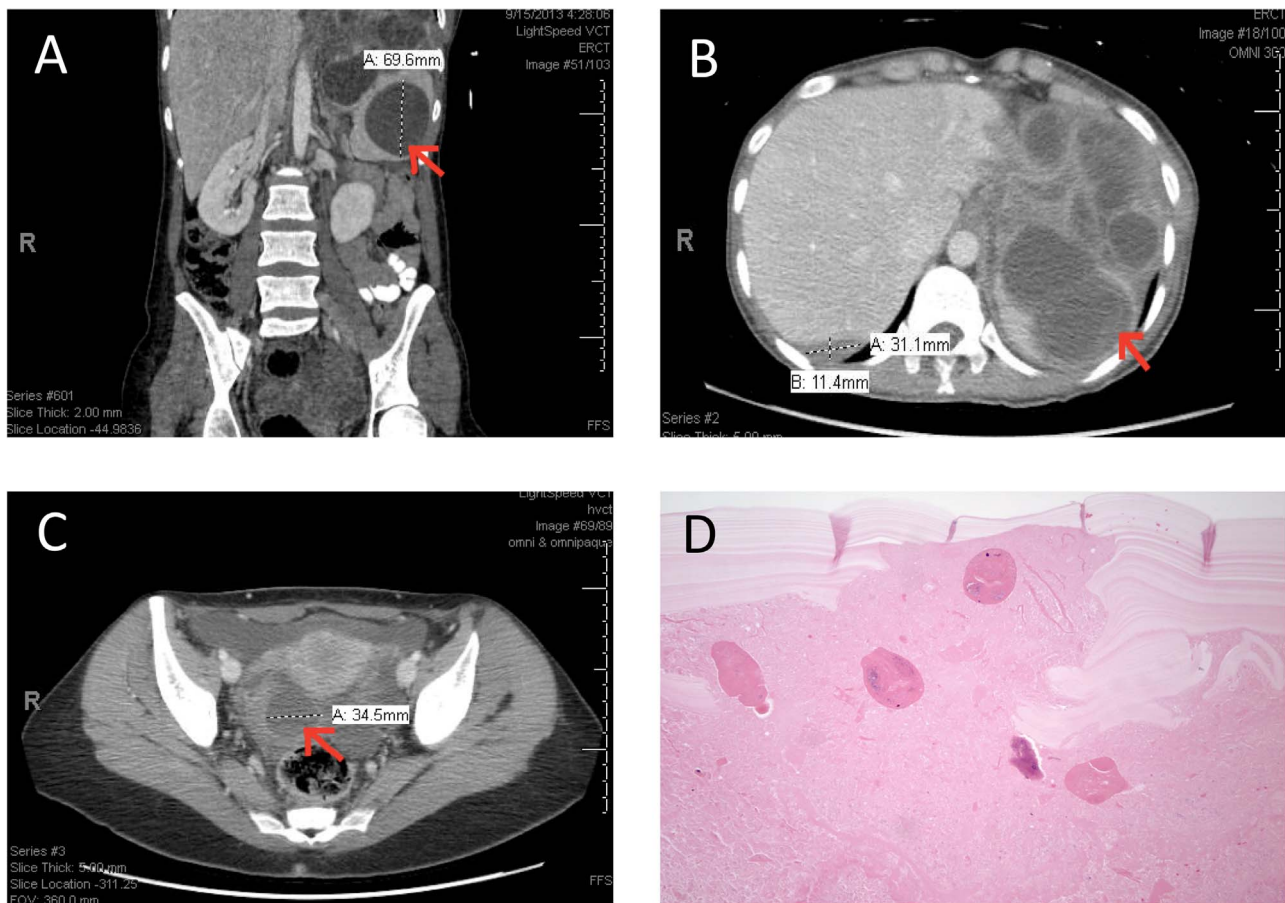


Fig. 1. Radiographic and pathologic findings of *Echinococcus granulosus*.

Panel A – Coronal CT demonstrating splenic hydatid cysts.

Panel B – Transverse CT demonstrating splenic hydatid cysts.

Panel C – Transverse CT demonstrating right ovarian hydatid cyst.

Panel D – H & E stain of pelvic cyst biopsy at 100× demonstrating the laminated membranes and scolices.

She developed cholecystitis in 2014 in addition to recurrence of the pelvic, gastric, hepatic, and diaphragmatic hydatid cysts found on CT after she presented with elevated antibody titers for echinococcosis on follow-up. She underwent an exploratory laparotomy, excision of pelvic and gastrohepatic cysts, drainage and excision of hepatic and diaphragmatic cysts, and appendectomy. In 2015, she was found to have rising antibody titers and another recurrence of hydatid disease limited to the pelvis with a 12 cm adnexal cyst (Fig. 1C). Interventional Radiology (IR) was consulted and they evaluated the patient but ultimately declined to intervene due to unfamiliarity with the disease and concern about spillage of hydatid cysts contents into the peritoneal cavity. In addition, she consulted many gynecologists to perform surgery on her but they declined as well due to unfamiliarity with the disease.

In 2016, her previous surgeon and a gynecological oncologist decided to perform a combined surgery for exploratory laparotomy with possible TAH-BSO for the recurrence discovered in 2015. The patient was given a perioperative regimen of albendazole. At laparotomy, there was no recurrence of the cysts in the abdomen. She was found to have multiple large simple pelvic cysts that were not related to hydatid disease. A small hydatid cyst on the right ovary was drained and removed. A TAH-BSO was deemed unnecessary. Pathology noted that these cysts consisted of clots with surrounding fibrosis and lymphocytosis, suggesting that these cysts were the result of a focal inflammatory reaction (related to prior hydatid disease) as opposed to being hydatid cysts. This pathological finding was in contrast to her prior confirmed hydatid cysts that were described as having broad cystic palisading granulomas with an eosinophilic avascular refractive

laminated membrane, occasionally surrounded by multinucleated giant cells (Fig. 1D). In addition, brood capsules and protoscolices were appreciated in the right ovary. The patient has recovered well and continues to be followed disease free as of February 2017.

Discussion

Echinococcus granulosus and its related species are a genus of zoonotic cestodes that cause cystic and alveolar echinococcosis. Their definitive hosts are carnivores, most commonly dogs. Definitive hosts are those species that can facilitate the growth of these parasites up to their mature form. Their intermediate hosts are typically domestic animals such a pig, goat, and sheep; humans are incidental hosts (Fig. 2). Intermediates hosts differ from definitive hosts in that the parasite cannot fulfill its entire life cycle and can only create cysts and eggs in these species. Typical infection occurs through ingestion of meats, fruits, or vegetables contaminated by feces of infected foxes or other canines [1]. Once eggs hatch and release oncospheres in the gastrointestinal tract, these *Echinococcus* oncospheres can penetrate the mucosa and spread through the circulatory system to organs such as the liver (60%), lungs (20%), spleen (3%), kidneys (4%), central nervous system (3%), and bone (2%) [2,3].

Upon reaching these organs, oncospheres develop into cysts containing protoscolices. This is *Echinococcus's* larval stage and may develop into adult worms in the intestines of definitive hosts. Cysts are slow growing, so the disease is typically diagnosed in adults presenting with symptoms from mass effect. Cysts possess an outer cuticular layer

Download English Version:

<https://daneshyari.com/en/article/5672227>

Download Persian Version:

<https://daneshyari.com/article/5672227>

[Daneshyari.com](https://daneshyari.com)