




Taibah University
Journal of Taibah University Medical Sciences

www.sciencedirect.com



Case Report

Unusual pattern of mandibular fracture displacement in a child: A case report



Shadia A. Elsayed, PhD

Department of Oral and Maxillofacial Surgery, College of Dentistry, Taibah University, Almadinah Almunawwarah, KSA

Received 25 September 2016; revised 7 December 2016; accepted 14 December 2016; Available online 8 February 2017

المخلص

إن غالبية كسور الفك السفلي عند الأطفال هي من نوع كسر الغصن التضفير مع وجود إزاحة بسيطة. نقوم هنا بتسجيل حالة كسر لقمي وإكليلاني للفك السفلي مع إزاحة شديدة، مع عرض مقدماتها السريرية وعلاماتها الإشعاعية والجراحية. أزيحت اللقمة والإكليلاني اليمين إلى الناحية الوحشية حتى استقرا بالكامل فوق الجانب الوحشي للفوس الوجني، مع إزاحة جزء من الإكليلاني إلى الناحية الإنسية. كان هناك تجمع دموي كبير في جدار البلعوم الوحشي امتد إلى الأسفل حتى الحد الأسفل للفك السفلية، مع إصابة شديدة للنسج الرخوة في المنطقة تحت الفك السفلي. ندرة مثل هذه الإصابة في الأطفال في منطقة الرأس والرقبة ومعالجتها تجعل هذه الحالة أكثر إثارة للاهتمام لجراحي الوجه والفكين.

الكلمات المفتاحية: اللقمة؛ تجمع دموي؛ الفك السفلي؛ طب أسنان الأطفال؛ إصابات الرأس والرقبة

Abstract

Most mandibular fractures in children are greenstick-type fractures with minimal displacement. We report a case of a severely displaced condylar and coronoid mandibular fracture along with its clinical presentation and radiological and surgical features. The right condyle and coronoid were laterally displaced, riding completely over the lateral surface of zygomatic arch with a coronoid fragment displaced medially. There was a large haematoma collection in the lateral pharyngeal wall extending downward to the inferior border of the mandible with severe soft tissue injury at the submandibular region. The rarity of such paediatric trauma in the head and neck

region and the management of such an injury make this case more interesting for maxillofacial surgeons.

Keywords: Condyle; Haematoma; Head and neck injury; Mandible; Paediatric dentistry

© 2017 The Author.

Production and hosting by Elsevier Ltd on behalf of Taibah University. This is an open access article under the CC BY-NC-ND license (<http://creativecommons.org/licenses/by-nc-nd/4.0/>).

Introduction

Unintentional injury may be more catastrophic than any other trauma, especially at a young age. A science of prophylaxis to prevent such injury is very important to prevent death among children and adolescents. The predominant mechanism of injury varies by age, with falls being most common in young children, pedestrian injuries in toddlers and elementary school-age children, and motor vehicle trauma in adolescents. Mortality rates of trauma, including all types, are higher in rural areas than in cities. The reasons for this may include longer wait times from injury to definitive care, in-hospital delays to definitive treatment, less time for injury prevention education in schools and primary care offices, and socioeconomic and ethnic factors. Other associations have been identified that increase susceptibility to trauma, such as children with behavioural disorders and negligence of parents or inadequate parental supervision.¹

Complete dislocation of the mandibular condyle from the fossa is classified into four types: anterior, posterior, lateral, and superior dislocation.¹ All types except for anterior dislocation are rare, according to Chaithanya 2013.¹ Superolateral dislocation of the intact mandibular condyle occurs very rarely.² Allen and Young³ classified lateral

Corresponding address: Taibah University, Almadinah Almunawwarah, KSA.

E-mail: shadiaelsayed25@gmail.com

Peer review under responsibility of Taibah University.



Production and hosting by Elsevier

dislocations into type I (lateral subluxation) and type II (complete dislocation), in which the condyle is forced laterally and then superiorly. Satoh et al.⁴ classified complete lateral dislocations of the condyle as the following types: type IIA, in which the condyle is not hooked above the zygomatic arch; type IIB, in which the condyle is hooked above the zygomatic arch; and type IIC, in which the condyle is lodged inside the zygomatic arch, which is fractured. There are a few reports of this kind of dislocation in adults.^{5,6} We report a case of superolateral unilateral complete dislocation of condyle and part of the coronoid with no fracture of the zygomatic arch, in a 6-year-old child, which may be very rare.

Case report

A six-year-old male was admitted to the emergency room of Al-Zahraa University Hospital, Cairo, Egypt in October of 2015. The patient was fully conscious, with a GCS score of 15, no evidence of any brain injury and a complete ability to maintain his airway. His parents had created a compression bandage with a large gauze pack on the right side of the child's face. Upon inspection, the wound was present at the right submandibular area and the cut was sharp and deep, reaching to the bony angled area of the mandible. The large blood vessels in this region appeared cut and compressed with no active bleeding. There was an extraoral swelling on the right side of the face extending to the level of the lateral orbital margin and downwards to the mandibular angle region. A large haematoma had collected at the medial part of the mandible, appearing from the cut wound as large soft black space. History from the parents revealed that the child had fallen down some newly formed granite steps and severe bleeding had started. An extraoral OPG radiograph revealed a suspected fracture on the anterior mandible and coronoid process of the right mandible. To confirm this diagnosis, a CT maxillofacial was requested. The CT revealed an anterior symphyseal non-displaced mandibular fracture and a vertical sagittal fracture of the coronoid process, which was displaced medially, and the whole ramus-condyle and coronoid were displaced laterally and riding on the lateral surface of the right zygomatic arch, which appeared clinically by palpation as a hard projection of the condyle on the substance of the cheek (Figures 1,2). Emergency intervention was conducted to reduce the segment, evacuate the haematoma and suture the wound.

The anaesthesiologist wanted to intubate the child nasally, as is usual in maxillofacial trauma cases, but a quick decision was made to intubate orally due to impaired visibility caused by excessive bleeding, which had just been revealed due to the lateral pharyngeal wall cut.

Extraorally, the condyle and ramus were palpably projecting under the skin of the right cheek. Many attempts to depress the ramus and condyle below the zygomatic arch via a closed reduction were made but with no results, even with the help of an angle pull with bone-clamping forceps made directly through the open access offered by the submandibular wound. Therefore, a decision was made to open the temporomandibular joint area with a preauricular incision and dissection until the condyle was reached, with a direct open reduction to the whole segment below the arch. In this

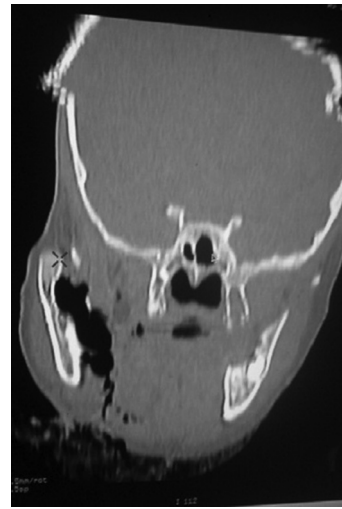


Figure 1: Preoperative coronal cut CT showing medial large haematoma extending from the submandibular lacerated wound upwards to the level of the coronoid.

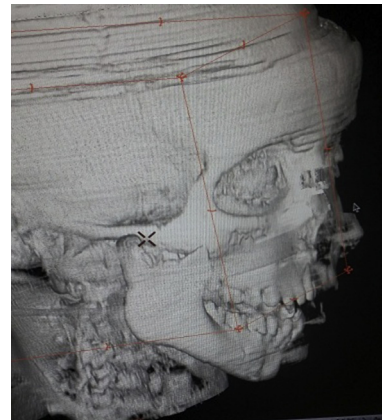


Figure 2: Preoperative 3 D CT photograph showing displaced ramal condyle and coronoid laterally overriding the right zygomatic arch.

instance, the extraoral bulging of the cheek disappeared immediately after reduction.

Before closure of the lacerated submandibular wound, evacuation of a large black blood clot medial to the ramus was performed and the area was vigorously irrigated with saline wash, with compression of the tissues to prevent further accumulation of blood.

The postoperative mouth opening was within the normal range and a physiotherapy follow-up was conducted immediately after the operation.

Discussion

Young children are more susceptible to trauma, especially boys, who are more likely to be affected than girls due to their rapid and uncontrolled play patterns. Thus, fall injury is the most seen aetiology in our emergency paediatric trauma centres.⁷

Shock can occur rapidly from blood loss caused by severe external wounds, especially in children. In this case, the

Download English Version:

<https://daneshyari.com/en/article/5680180>

Download Persian Version:

<https://daneshyari.com/article/5680180>

[Daneshyari.com](https://daneshyari.com)