

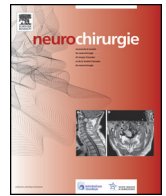


Disponible en ligne sur

ScienceDirect  
www.sciencedirect.com

Elsevier Masson France

EM|consulte  
www.em-consulte.com



Original article

## Surgical resection of incidental diffuse gliomas involving eloquent brain areas. Rationale, functional, epileptological and oncological outcomes

G.L.O. Lima<sup>a,b,c</sup>, E. Dezamis<sup>b,c</sup>, R. Corns<sup>d</sup>, O. Rigaux-Viode<sup>b,c</sup>, S. Moritz-Gasser<sup>g</sup>,  
A. Roux<sup>b,c</sup>, H. Duffau<sup>e,f,g,1</sup>, J. Pallud<sup>b,c,e,\*,1</sup>

<sup>a</sup> Department of Neurosurgery, Onofre Lopes University Hospital, Rio Grande do Norte Federal University, Natal, RN, Brazil

<sup>b</sup> Department of Neurosurgery, Sainte-Anne Hospital, 1, rue Cabanis, 75674 Paris cedex 14, France

<sup>c</sup> Paris Descartes University, Sorbonne Paris Cité, Paris, France

<sup>d</sup> Department of Neurosurgery, Leeds General Infirmary, Leeds, United Kingdom

<sup>e</sup> Réseau d'étude des gliomes (REG), Croland, France

<sup>f</sup> Department of Neurosurgery, Gui de Chaumié Hospital, Montpellier University Medical Center, Montpellier, France

<sup>g</sup> Inserm U1051, Institute for Neuroscience of Montpellier, Montpellier, France

### ARTICLE INFO

#### Article history:

Received 7 May 2016

Received in revised form 22 July 2016

Accepted 22 August 2016

Available online xxx

#### Keywords:

Awake craniotomy

Diffuse low-grade glioma

Incidental

Outcomes

Surgery

### ABSTRACT

**Objective.** – Incidentally discovered diffuse low-grade gliomas progress in a fashion similar to their symptomatic counterparts. Their early detection allows more effective pre-emptive and individualized oncological treatment. We assessed the safety and efficacy of maximal safe resection according to functional boundaries for incidental diffuse low-grade gliomas in eloquent areas.

**Material and methods.** – Two-centre retrospective series of adult patients with incidental diffuse low-grade gliomas located within/close to eloquent areas in the dominant hemisphere, treated with maximal surgical resection according to functional boundaries under intraoperative functional cortico-subcortical monitoring under awake conditions, and with a minimal follow-up of 24 months.

**Results.** – The series included 19 patients (8 men, 11 women) with no preoperative neurological deficit but with a radiologically enlarged glioma. No intraoperative seizure, postoperative infection, haematoma or wound-healing problem was observed. In the immediate postsurgical period, a transient neurological worsening occurred in 10 patients. The resection (mean rate 96.4%; range, 82.4–100) was supratotal in 5 cases, total in 5 cases, subtotal in 7 cases, and partial in 2 cases. Six months after surgery, all patients recovered after functional rehabilitation, with no permanent neurological deficit, Karnofsky Performance Status was 100 (except for one patient who received early postoperative radiotherapy) and no seizures were observed. The survival without progression requiring oncological treatment was significantly longer in patients with a total/supratotal resection than in patients with a partial/subtotal resection.

**Conclusions.** – These results suggest the reproducibility, safety, and effectiveness of an early maximal functionally based resection within cortico-subcortical functional boundaries for incidental diffuse low-grade gliomas in adults in centres hyperspecialized in surgical neuro-oncology.

© 2016 Elsevier Masson SAS. All rights reserved.

## 1. Introduction

World Health Organization (WHO) grade II glioma (diffuse low-grade glioma [DLGG]) is a heterogeneous group of brain tumours

characterized by slow and continuous growth [1–3], with a preferential migration along white matter tracts [4,5] and by an evolution towards a higher grade of malignancy [3,6]. Due to their constant evolution, an active therapeutic attitude is now recommended, with early surgery as the first therapy [6–8]. Intraoperative mapping, with maximal safe resection according to functional boundaries, is associated with a longer overall survival while minimizing morbidity and maintaining quality of life [6,9–12]. The management of DLGG is switching towards a personalized and long-term multistage approach. Each case is individually

\* Corresponding author. Department of Neurosurgery, Sainte-Anne Hospital, 1, rue Cabanis, 75674 Paris cedex 14, France.

E-mail address: johanpallud@hotmail.com (J. Pallud).

<sup>1</sup> These authors participated equally in this work.

tailored based on clinical, radiological, and histomolecular factors, thus supporting personalized, functional, and preventive neuro-oncology [8].

The natural history of DLGG development can be summarized in four stages [13–15]:

- the biological birth without any symptom and below the detection limit of routine MRI; this is the occult stage;
- at some point, the glioma becomes visible on MRI, yet the patient remains asymptomatic; this is the clinically silent stage;
- the glioma elicits clinical symptoms, most commonly epileptic seizures; this is the symptomatic stage;
- at some point in time, the glioma progresses from its rather indolent behaviour to that of a higher grade glioma, ultimately killing the patient due to brain invasion and spread; this is the malignant transformation.

The “clinically silent” period has recently been estimated to last approximately 14 years [14]. When symptomatic, DLGG are usually revealed by inaugural seizures in young adults with no or mild neurological and neuropsychological deficits [7,16]. However, the long period of evolution while asymptomatic but detectable on MRI explains why DLGG can be incidentally discovered on MRI in up to 0.3% of the healthy population [17–19]. This corresponds to 3% of diagnosed primary brain tumours in clinical practice [20]. This early detection represents an opportunity to apply preventive oncological treatment with a maximal chance of efficacy [8,17]. This type of approach has to be supported by evidence of radiological progression of the incidentally discovered DLGG. Previous studies have shown that incidental DLGG are progressive tumours with:

- a constant rate of growth similar to that of symptomatic DLGG;
- insidious but objective neuropsychological impairments [21];
- a natural tendency towards becoming a symptomatic DLGG;
- histopathological and molecular findings similar to those of symptomatic DLGG;
- a risk of malignant transformation [17,22–27].

In addition, the glioma can be discovered late in its natural history, as either a secondary anaplastic glioma or a secondary glioblastoma, after the malignant but silent transformation of the DLGG [28]. All these observations support the benefits of early intervention for incidental DLGG. However, the management of incidental DLGG involving eloquent brain areas is ill defined and requires further investigation [26,29]. Here we report a two-centre study aiming at assessing the safety and efficacy of early and preventive intervention for incidental DLGG with maximal surgical resection according to functional boundaries under intraoperative functional cortico-subcortical monitoring under awake conditions. Specifically, we assessed the postoperative outcomes, the oncological control, and functional status (including epileptic seizure control, neuropsychological assessments, ability to work).

## 2. Methods

### 2.1. Data source

This prospective study examined a consecutive series of 19 patients who underwent maximal functional-based surgical resection at two different neurosurgical institutions (Centre 1: Gui de Chauliac University Hospital of Montpellier, France, between December 1998 and December 2010, France; Centre 2: Sainte-Anne Hospital Center–University Paris Descartes, France, between January 2010 and December 2013) for an incidental DLGG located

within or near eloquent brain areas. All surgery was performed by the same neurosurgeons at each institution.

Inclusion criteria were:

- adult patients older than 18 at the time of radiological diagnosis;
- incidental DLGG defined as a previously undetected and incidental tumour at the time of imaging diagnosis that was an unexpected discovery and unrelated to the purpose of the MRI examination [17];
- glioma location within or close to eloquent areas in the dominant hemisphere [30];
- maximal surgical resection according to functional boundaries under intraoperative functional cortico-subcortical monitoring under awake conditions using the asleep-awake-asleep protocol previously described [31–33];
- minimum postoperative follow-up of 24 months.

### 2.2. Evaluation methods

Data on the following parameters were collected: gender, age at radiological diagnosis, reason for initial investigation, tumour location, time interval between radiological diagnosis and surgery, preoperative tumour volume and surgically resected volume (evaluated on pre- and postoperative MRI using Fluid Attenuated Inversion Recovery [FLAIR] sequence), histopathological diagnosis according to the WHO classification version 2007 [34], postoperative oncological treatment, duration of follow-up, malignant transformation, and survival. In addition, the patients' neurological status and language functions were evaluated pre- and postoperatively at six months after surgery. Handedness was assessed using the standardized Edinburgh inventory. Language evaluation was performed using the Boston Diagnostic Aphasia Examination and a test of picture naming (DO80 test). Finally, the patients' functional status was evaluated by means of the Karnofsky Performance Status (KPS) [16] before and after the surgery.

### 2.3. Magnetic resonance imaging evaluation

The tumour volume was calculated using region of interest measurements of abnormal signal on FLAIR or T2-weighted sequences, as previously described [35]. Postoperatively, the volume of the residual tumour (if any) was calculated using the same method on an MRI obtained at 3 months after surgery. In all cases, at least two MRIs at a 3-month interval were performed before surgery, to estimate the rate of radiological growth, using the method described above [35]. The extent of resection was defined as “total” when no residual abnormal signal was present on FLAIR or T2-weighted sequence, as “supratotal” when a margin of parenchyma was removed around the preoperative FLAIR or T2-weighted sequence signal abnormality, with a larger volume of surgical cavity as compared with the presurgical tumour volume, as previously described [33], and as “subtotal” when the postoperative residual signal was less than 10 cm<sup>3</sup> [36]. All other cases were considered a partial resection.

### 2.4. Surgical procedure

In all cases, intraoperative functional cortical and subcortical direct electrostimulation mapping was performed using the “asleep-awake-asleep” protocol in the two institutions, as previously reported [26,32,37]. Cerebral sulci and gyri were first identified using intraoperative ultrasonography. Functional mapping used a bipolar electrode (5-mm space between tips; Centre 1, Nimbus, Newmedic, Hemodia; Centre 2, Osiris NeuroStimulator, Inomed, Madison WI) delivering a biphasic current (pulse frequency 60 Hz; pulse phase duration 1 ms). The entire exposed

Download English Version:

<https://daneshyari.com/en/article/5681685>

Download Persian Version:

<https://daneshyari.com/article/5681685>

[Daneshyari.com](https://daneshyari.com)