



Contents lists available at ScienceDirect

## Gynecology and Minimally Invasive Therapy

journal homepage: [www.e-gmit.com](http://www.e-gmit.com)

## Original article

## Feasibility of reduced port surgery applying Higuchi's transverse incision



Kazu Ueda <sup>a</sup>, Yoko Nagayoshi <sup>a</sup>, Ayako Kawabata <sup>a</sup>, Takafumi Kuroda <sup>a</sup>, Yasushi Iida <sup>a</sup>, Motoaki Saitou <sup>a</sup>, Nozomu Yanaihara <sup>a</sup>, Kouhei Sugimoto <sup>a</sup>, Masaru Sakamoto <sup>b</sup>, Aikou Okamoto <sup>a,\*</sup>

<sup>a</sup> Department of Obstetrics and Gynecology, The Jikei University School of Medicine, Tokyo, Japan

<sup>b</sup> Department of Gynecology, Sasaki Foundation Kyoundo Hospital, Tokyo, Japan

## ARTICLE INFO

## Article history:

Received 15 January 2016

Received in revised form

4 May 2016

Accepted 9 May 2016

Available online 15 June 2016

## Keywords:

laparoscopically assisted myomectomy

power morcellator

reduced port surgery

## ABSTRACT

**Objective:** Higuchi's transverse incision is made at a lower position than the Pfannenstiel transverse incision and is superior in terms of cosmetic outcomes. The purpose of this study was to examine the safety and efficacy of novel forms of reduced port surgery for ovarian cysts and uterine fibroids applying Higuchi's transverse incision.

**Methods:** In 33 patients with ovarian cysts who underwent low-position single-incision laparoscopic surgery (L-SILS)-modified single-port laparoscopy placed in the 2–3-cm Higuchi's incision above the pubis, patient's characteristics and perioperative outcomes were compared with those of patients who underwent multiport laparoscopy ( $n = 53$ ). In addition, 18 patients with uterine fibroids who underwent dual-port laparoscopically assisted myomectomy without using power morcellators and conventional four-port laparoscopically assisted myomectomy were investigated.

**Results:** There were no significant differences between L-SILS and multiport laparoscopy in tumor diameter, bleeding, hospital stay, or postoperative pain. However, the L-SILS group demonstrated significantly shorter operative and pneumoperitoneum times ( $p < 0.01$  and  $p < 0.01$ ). In comparison with cases of uterine fibroids, no significant differences were found in maximum fibroid diameter, operative time, pneumoperitoneum time, or bleeding. However, the dual-port laparoscopically assisted myomectomy group demonstrated a significantly shorter length of hospital stay than the conventional laparoscopically assisted myomectomy group ( $p < 0.05$ ).

**Conclusion:** We reported novel forms of reduced port surgery applying Higuchi's transverse incision. It was suggested that these procedures are relatively simple, but ensure the same safety and efficacy as conventional methods. We intend to increase the number of cases and examine safety, efficacy, and patient satisfaction for these procedures.

Copyright © 2016, The Asia-Pacific Association for Gynecologic Endoscopy and Minimally Invasive Therapy. Published by Elsevier Taiwan LLC. This is an open access article under the CC BY-NC-ND license (<http://creativecommons.org/licenses/by-nc-nd/4.0/>).

## Introduction

Compared with laparotomy, laparoscopic surgery results in fewer perioperative complications, less postoperative pain, shorter hospitalization, and faster recovery.<sup>1</sup> Furthermore, as the evolution

of energy devices and other medical equipment has led to improved safety and shorter operative times, reduced port surgery (RPS) such as single-port laparoscopy and microlaparoscopy have been developed; these RPS techniques are less invasive and yield superior cosmetic outcomes compared with conventional surgery, and multiple studies have reported their utility.<sup>2,3</sup>

In gynecology, single-port laparoscopy is typically performed with an umbilical approach, the utility of which has been reported by several studies.<sup>4–7</sup> However, the surgery is difficult to perform,<sup>8,9</sup> and a number of studies have reported postoperative complications such as umbilical hernias and refractory infections.<sup>10–12</sup>

Conflicts of interest: The authors have no conflicts of interest relevant to this article.

\* Corresponding author. Department of Obstetrics and Gynecology, The Jikei University School of Medicine, 3-25-8 Nishi-Shimbashi, Minato-ku, Tokyo 105-8461, Japan.

E-mail address: [aikou7000@gmail.com](mailto:aikou7000@gmail.com) (A. Okamoto).

<http://dx.doi.org/10.1016/j.jgmit.2016.05.003>

2213–3070/Copyright © 2016, The Asia-Pacific Association for Gynecologic Endoscopy and Minimally Invasive Therapy. Published by Elsevier Taiwan LLC. This is an open access article under the CC BY-NC-ND license (<http://creativecommons.org/licenses/by-nc-nd/4.0/>).

In addition, in April 2014, the United States Food and Drug Administration issued a warning regarding the safety of power morcellators typically used in laparoscopy for uterine fibroids, thus posing problems for the surgical procedure and fibroid removal.<sup>13,14</sup>

Higuchi's transverse incision is made at a lower position than the conventional Pfannenstiel transverse incision and is superior in terms of cosmetic outcomes. We perform Higuchi's transverse incision as a standard approach in laparotomy for benign tumors (except for giant tumors) and for cesarean sections.

In the present study, we applied Higuchi's transverse incision in RPS; here, we discuss new surgical procedures with the objective of further improving cosmetic outcomes. We report our introduction of two new operative procedures: low-position single-incision laparoscopic surgery (L-SILS), which does not involve the umbilicus, for ovarian cysts, and dual-port laparoscopically assisted myomectomy (2P-LAM), which does not use a power morcellator, for uterine fibroids.

## Methods

### Higuchi's transverse incision

First, we will describe Higuchi's transverse incision.

- (1) Skin incision: The incision is made at a low position, 1.5 cm above the pubis. The wound is covered by the pubic hair and thus has a superior cosmetic outcome. This incision also enables easier surgeries on the bladder, cervix, and elsewhere in the pelvis.
- (2) Blunt dissection of subcutaneous adipose tissue: The extensive use of blunt dissection of subcutaneous adipose tissue makes it possible to avoid abdominal wall blood vessel injury.
- (3) T incision of the rectus abdominis fascia: After bluntly extending the rectus abdominis fascia incision from 2–3 cm cranial to the skin incision line in a transverse direction to the lateral margin of the rectus abdominis, a longitudinal incision is made toward the area directly above the pubic symphysis. The opening of a T incision in the rectus abdominis fascia ensures a sufficient visual field.
- (4) Longitudinal incision of the peritoneum: Treatment of the peritoneum while confirming the bladder makes it possible to avoid bladder injury. The skin, fascia, and peritoneum

incision sites do not coincide, thus making it possible to prevent an abdominal incisional hernia.

### L-SILS for ovarian cysts

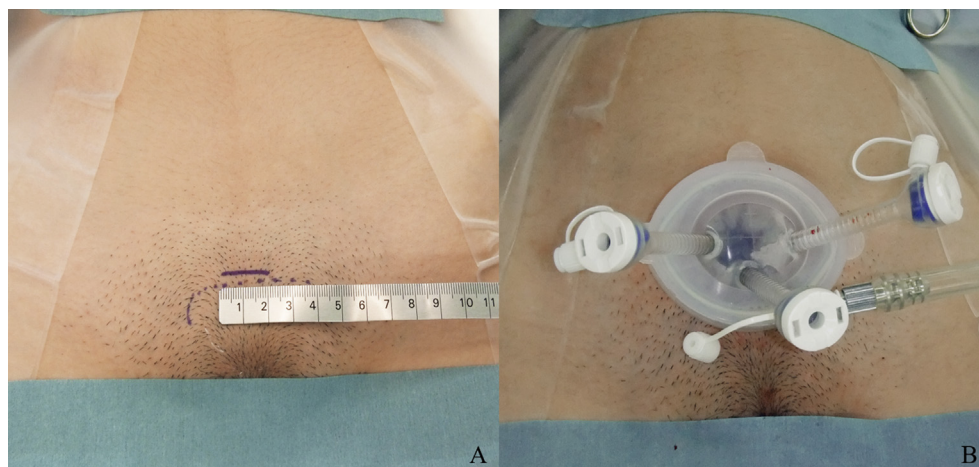
- (1) A platform is placed in the 2–3 cm Higuchi's transverse incision superior margin on the pubis (Figure 1A).
- (2) A Lap Protector and an EZ access (Hakko Medical, Nagano, Japan) are used with the platform. Three Versaport trocars (Medtronic, Minneapolis, MN, USA) are attached to the EZ access (Figure 1B).
- (3) A 5-mm flexible videoscope (Olympus, Tokyo, Japan) is used to observe the tumor site, tumor size, and possible presence of adhesions following pneumoperitoneum.
- (4) Following fine-needle aspiration of ovarian cyst fluid, the cyst is resected extracorporeally.

### The 2P-LAM procedure for uterine fibroids

- (1) A camera port is inserted through the umbilicus using the optical method. A 5-mm flexible videoscope (Olympus, Tokyo, Japan) is used to observe the possible presence of intra-abdominal adhesions.
- (2) A platform is placed in the 3-cm Higuchi's transverse incision above the pubis.
- (3) A Lap Protector and an EZ access (Hakko Medical, Nagano, Japan) are used with the platform. Two Versaport trocars (Medtronic, Minneapolis, MN, USA) are attached to the EZ access (Figure 2A).
- (4) The fibroid is enucleated intra-abdominally, and the wound in the uterus is sutured under direct observation. The absence of remaining fibroids is confirmed by palpation.
- (5) The enucleated fibroid is collected into an isolation bag, morcellated with a scalpel in the bag under direct observation, and removed from the abdominal cavity via the Higuchi's transverse incision without using power morcellators (Figure 2B).

## Results

We began performing cystectomy by L-SILS for ovarian cysts in March 2014. A breakdown of cases is shown in Table 1. Initially, the



**Figure 1.** L-SILS applying Higuchi's transverse incision. (A) The skin incision made at the superior margin on the pubis. (B) The platform is placed in the 2–3-cm Higuchi's transverse incision. Three trocars are attached to the EZ access. L-SILS = low-position single-incision laparoscopic surgery.

Download English Version:

<https://daneshyari.com/en/article/5695978>

Download Persian Version:

<https://daneshyari.com/article/5695978>

[Daneshyari.com](https://daneshyari.com)