




Contents lists available at ScienceDirect

Gynecology and Minimally Invasive Therapy

journal homepage: www.e-gmit.com

Case report

“Contain before transection, contain before manual morcellation” with a tissue pouch in laparoendoscopic single-site subtotal hysterectomy

Meng-Yu Wu ^a, Dah-Ching Ding ^{b, c}, Tang-Yuan Chu ^{b, c}, Mun-Kun Hong ^{b, c, *}^a School of Medicine, Tzu Chi University, Hualien, Taiwan^b Department of Obstetrics and Gynecology, Buddhist Tzu Chi General Hospital, Hualien, Taiwan^c Institute of Medical Science, Tzu Chi University, Hualien, Taiwan

ARTICLE INFO

Article history:

Received 30 November 2015

Received in revised form

30 January 2016

Accepted 2 February 2016

Available online xxx

Keywords:

laparoendoscopic single-site surgery

manual morcellation

specimen removal

surgical tissue pouch

ABSTRACT

This work proposes a modified method for removing the uterine body in laparoendoscopic single-site subtotal hysterectomy based on the principle of “contain before transection, and contain before manual morcellation,” using a surgical tissue pouch (LapSac, Cook Inc., Bloomington, IN, USA). The main advantage of this method is a low likelihood of a bag rupture during manual morcellation which minimizes the potential risk of iatrogenic parasitic myoma and/or cancer cell dissemination. This method also benefits from lower cost, less surgical time, and “containing before transection” makes the shifting of uterine specimens in the laparoendoscopic single-site more feasible. The limitations of this method, and potential means of overcoming them, are also discussed. Potentially, this method of “contain before transection, contain before manual morcellation” can be applied to other organ tissue removal in laparoscopic surgeries but more cases must be studied to confirm its safety and feasibility.

Copyright © 2016, The Asia-Pacific Association for Gynecologic Endoscopy and Minimally Invasive Therapy. Published by Elsevier Taiwan LLC. This is an open access article under the CC BY-NC-ND license (<http://creativecommons.org/licenses/by-nc-nd/4.0/>).

Introduction

In the past decade, power morcellator has been widely used in laparoscopic surgery to facilitate specimen removal,¹ and it has reduced limitations associated with minimally invasive surgery. However, the United States Food and Drug Administration has questioned the safety of using a power morcellator to remove uterine leiomyoma owing to the risk of cancer dissemination and upstaging in intraperitoneal occult malignancies,² and suggested using a specimen bag to contain unsuspected uterine tumors when power morcellation is necessary.³ As well as the dissemination of occult uterine malignancies, iatrogenic or parasitic myomas related to power morcellator use have been reported,⁴ causing gynecologic surgeons to change their approaches to hysterectomies and myomectomies. Recently, many studies have focused on techniques for safe specimen removal of unsuspected uterine tumors.^{5,6}

Manual morcellation using a scalpel to fragment a surgical specimen into small pieces has been used for years especially in laparoendoscopic single-site surgery (LESS). The risk of vascular and bowel injury is lower in manual morcellation than in the power morcellation.⁷ To remove a specimen in LESS, manual morcellation is more effective than power morcellation because of the small surgical field, loss of angulation, and lack of an extra hand. However, manual morcellation is still associated with the possibility of the spreading of tumor cells if the specimens are not well contained.

This case report describes a modified method of specimen removal using a tissue pouch and manual morcellation to minimize unexpected cell/tissue dissemination in LESS subtotal hysterectomy.

Case Report

A 37-year-old multipara presented with dysmenorrhea and menorrhagia ongoing for 3 months. Physical examination revealed bilateral pale conjunctiva. Pelvic vaginal examination showed no visible cervical lesion. Transvaginal ultrasonography revealed an enlarged uterus with adenomyomas and thick irregular

Conflicts of interest: The authors report no conflict of interest in relation to this article.

* Corresponding author. Department of Obstetrics and Gynecology, Buddhist Tzu Chi General Hospital, 707, Section 3, Chung Yang Road, Hualien 970, Taiwan.

E-mail address: jeff06038@gmail.com (M.-K. Hong).

<http://dx.doi.org/10.1016/j.gmit.2016.02.005>

2213-3070/Copyright © 2016, The Asia-Pacific Association for Gynecologic Endoscopy and Minimally Invasive Therapy. Published by Elsevier Taiwan LLC. This is an open access article under the CC BY-NC-ND license (<http://creativecommons.org/licenses/by-nc-nd/4.0/>).

Please cite this article in press as: Wu M-Y, et al., “Contain before transection, contain before manual morcellation” with a tissue pouch in laparoendoscopic single-site subtotal hysterectomy, *Gynecology and Minimally Invasive Therapy* (2016), <http://dx.doi.org/10.1016/j.gmit.2016.02.005>

endometrium (11.3 mm). The laboratory examination revealed anemia with low hemoglobin (7.1 g/dL). Hysteroscopy revealed uneven endometrium. Dilation and curettage were performed and the pathology report was negative for malignancy. The patient underwent LESS subtotal hysterectomy and bilateral salpingectomy based on the principles of “contain before transection and contain before manual morcellation.”

Preparations of the tissue pouch

The LapSac surgical tissue pouch (COOK Medical Incorporated, Bloomington, IN, USA) was used to contain the body of the uterus before supracervical transection. To facilitate containment during surgery, Vicryl sutures were placed at four separate points on the edges of the pouch (Figure 1A). A plastic ruler (an accessory of a sterilized marker pen) was cut in half and sutured at both angles of the pouch so that it would open in the abdominal cavity (Figure 1B).

Operative procedures

When the patient was under general anesthesia, a uterine elevator was inserted. The single port setting was used as described in the literature.⁸ In this modified method, four trocars were used for the camera, the cutting loop (26183 MB, KARL STORZ, Tuttlingen, Germany), and two graspers (Figure 1C). Supracervical

hysterectomy was conducted involving transecting the round, ovarian, and broad ligaments with Ligasure (Valleylab Inc., Boulder, CO, USA) and opening the peritoneum at the utero-vesical junction. The bilateral uterine artery at each side of the cervix was identified by dissection and transected following coagulation with Ligasure. The pouch was then inserted into the abdominal cavity via the single port hole (Figure 1D). A grasper was utilized to move the opening of the pouch near the uterus (Figure 2A). A cutting loop was used to loop the uterus at the supracervical level (Figure 2B). Two graspers were used to contain the uterine body into the pouch, from the fundus to the lower segment of uterus (Figure 2C). It is necessary that the uterine elevator is removed and to ensure that no bowels or other organs are trapped by the cutting loop. A 70–80-watt cutting energy was applied for cervical transection. The pouch was simply closed by pulling up the drawstring (Figure 2D) and pulling up to the single port site (Figure 3A). The opening of the pouch was reopened and shortened by wrapping outward (Figure 3B), and the body of the uterus was cut into one or more long strip(s) (Figure 3C). All the tissue fluids from the cutting were contained in the pouch (Figure 3D).

Discussion

The surgical tissue pouch that was used in this report had several characteristics that made it very suitable for removing a

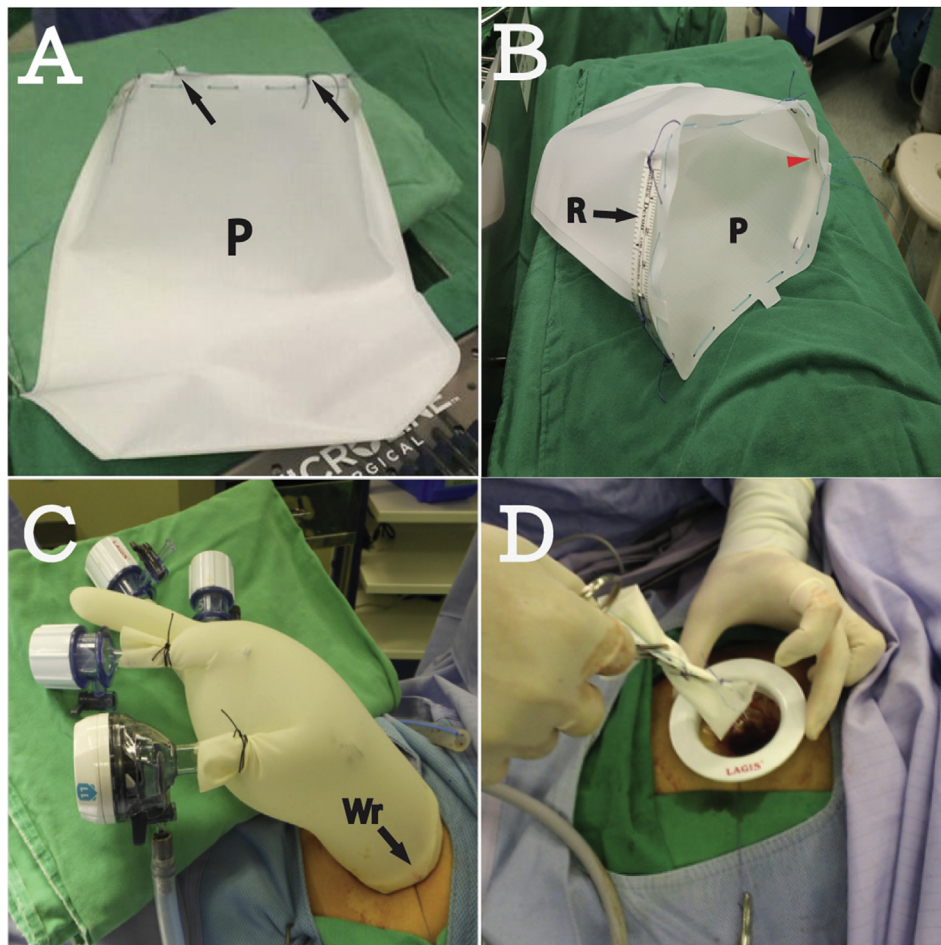


Figure 1. (A) Four sutures of 0 Vicryl were placed at the edges of the pouch (P). The sutures were cut 1.5 cm from the knots (black arrows). (B) Half of a plastic ruler (R) was sutured at the edges of the P with three sutures, so that the pouch would open itself in the abdomen. The middle suture was at the angle of the P (red arrowhead). (C) A laparoscopic single-site surgery port setting that comprises a wound retractor (Wr) and four trocars each inserted in the fingers of a surgical glove. (D) Using a pean, the pouch was clamped and inserted into the abdominal cavity.

Download English Version:

<https://daneshyari.com/en/article/5696234>

Download Persian Version:

<https://daneshyari.com/article/5696234>

[Daneshyari.com](https://daneshyari.com)