American Journal of Ophthalmology Case Reports 7 (2017) 55–58

Contents lists available at ScienceDirect

American Journal of Ophthalmology Case Reports

journal homepage: http://www.ajocasereports.com/

Case report

A stepping stone in treating dendritic keratitis

Hosam Sheha, MD, PhD [a, b, *], Sean Tighe, MSc [a, b], Anny M.S. Cheng, MD [a, b], Scheffer C.G. Tseng, MD, PhD [a]

[a] Ocular Surface Center, Miami, FL, USA
[b] Department of Ophthalmology, Florida International University, Herbert Wertheim College of Medicine, Miami, FL, USA

ARTICLE INFO

Article history:
Received 16 December 2016
Received in revised form
17 May 2017
Accepted 2 June 2017
Available online 6 June 2017

Keywords:
Amniotic membrane
Antiviral
Dendritic keratitis
Interferon

ABSTRACT

Purpose: To report the outcome of self-retained amniotic membrane after debridement in recurrent dendritic keratitis.
Observations: A 70-year-old female with a recurrent dendritic corneal ulcer received debridement followed by placement of self-retained amniotic membrane. Five days after treatment, the patient experienced a complete resolution of symptoms, marked reduction of inflammation, complete re-epithelialization of the cornea and improvement of visual acuity. The corneal surface remained stable for 18 months despite noncompliance in using antiviral therapy.
Conclusions and importance: Self-retained amniotic membrane after debridement appears effective in treating dendritic keratitis. While early debridement is crucial to remove the infected corneal epithelium, amniotic membrane was shown to enhance the healing without scarring or recurrence. Besides the known anti-inflammatory and anti-scarring effects of the amniotic membrane, it may have a potential topical antiviral effect that warrants further investigation.
© 2017 The Authors. Published by Elsevier Inc. This is an open access article under the CC BY-NC-ND license (http://creativecommons.org/licenses/by-nc-nd/4.0/).

1. Introduction

Herpes simplex virus (HSV) keratitis is one of the most frequent causes of corneal blindness in the United States and worldwide.[1] Typically, it begins with epithelial involvement which may spontaneously resolve or spread to the stroma and endothelium. Pathogenesis includes viral replication within the infected epithelium, followed by the characteristic dendritic ulceration, immune mediated stromal inflammation and subsequent sight-threatening complications. The strategy for treatment is to eliminate the infectious virus, minimize stromal damage and prevent subsequent corneal scarring, melting or perforation.

Debridement has been used in HSV epithelial keratitis in an attempt to remove the infected epithelium, however it provides inadequate treatment with a high rate of recurrence.[2] Antiviral therapies are commonly used to target the infectious agent and reduce the recurrence.[3] In this regard, oral antiviral agents are recommended over topical antiviral agents due to their superior safety profile and corneal penetration. However, oral antivirals are also linked to a lack of compliance.[4,5]

If the disease progresses to immune-mediated keratitis, the priority usually shifts to managing the stromal manifestations due to the potential for irreversible visual loss. Corneal damage observed at this stage is mainly caused by pro-inflammatory molecules released by the infected cells. The associated inflammation can be focal, multifocal, or diffuse and may lead to corneal thinning, scarring, or neovascularization. Available evidence in randomized clinical trials suggests a role for therapeutic doses of oral antivirals combined with judicious use of topical corticosteroids to suppress the associated inflammatory response. However, the use of steroids is controversial as it may induce complications such as flaring up the infection, corneal melting, elevation of the intraocular pressure, cataract, and/or increase the tendency toward recurrence.[6] Due to these significant side effects, other alternatives are sought to control inflammation and enhance the healing.

Cryopreserved amniotic membrane (CAM) has successfully been used in the treatment of ocular surface disorders induced by infectious keratitis.[7,8] More specifically, studies have shown that CAM as a temporary patch along with antivirals and corticosteroids can significantly improve HSV keratitis[9–11] and the action mechanism has been attributed to its known anti-inflammatory and anti-scarring effects.[12,13] Herein we report a case of recurrent dendritic

* Corresponding author. Ocular Surface Center, 7000 SW 97th Avenue, Suite 213, Miami, FL 33173, USA.
E-mail address: hsheha@ocularsurface.com (H. Sheha).

http://dx.doi.org/10.1016/j.ajoc.2017.06.002
2451-9936/© 2017 The Authors. Published by Elsevier Inc. This is an open access article under the CC BY-NC-ND license (http://creativecommons.org/licenses/by-nc-nd/4.0/).

keratitis that had been successfully treated with self-retaining CAM without the use of antiviral therapy, suggesting CAM may have a potential antiviral effect as well.

2. Case report

A 70-year-old female with a history of stable rheumatoid arthritis had been treated with systemic methotrexate 7.5 mg weekly and prednisolone 2.5 mg daily for 5 years. She had experienced three episodes of dendritic keratitis in less than a year which were treated with topical acyclovir (3%) ointment 5 times per day during the acute phase and prophylactic oral acyclovir 400 mg twice daily between episodes. She developed allergy to her prescription contact lenses and used 0.1% dexamethasone 4 times daily for 10 days after which she presented with worsening in left ocular pain, photophobia, and blurry vision. Slit-lamp examination and fluorescein staining showed left paracentral dendritic corneal ulcer (Fig. 1, top), decreased corneal sensation, conjunctival injection, 20/80 vision, and borderline intraocular pressure of 21 mmHg. Diagnosis of recurrent dendritic keratitis was made based on the history and clinical impression. Under topical anesthesia, gentle corneal epithelial debridement was performed using a dry weck-cel (Microsponge™, Alcon®) (Fig. 1, middle left) to remove the loose epithelium at the edge of the dendritic ulcer. Then, a self-retained CAM (PROKERA Slim®, Bio-Tissue Inc. Miami, FL) was placed and the baseline epithelial defect was detected by fluorescein staining (Fig. 1, middle right). No topical antiviral was used to avoid its known toxicity to the corneal epithelium so oral acyclovir 200 mg 5 times per day was prescribed. However, the patient reported that they did not use it.

Five days after treatment, the CAM dissolved and Prokera was removed. The ocular discomfort disappeared, inflammation was reduced, the corneal epithelium healed completely (Fig. 1, bottom left), and the visual acuity improved to 20/30. During the 18 months follow up, the corneal surface remained stable without recurrence despite the patient not taking systemic antiviral (Fig. 1, bottom right).

3. Discussion

Although debridement is a commonly used procedure in HSV epithelial keratitis, studies have demonstrated that 50% of patients usually develop recurrence within a week if antiviral agents were not used.[2,3] Moreover topical corticosteroids are usually

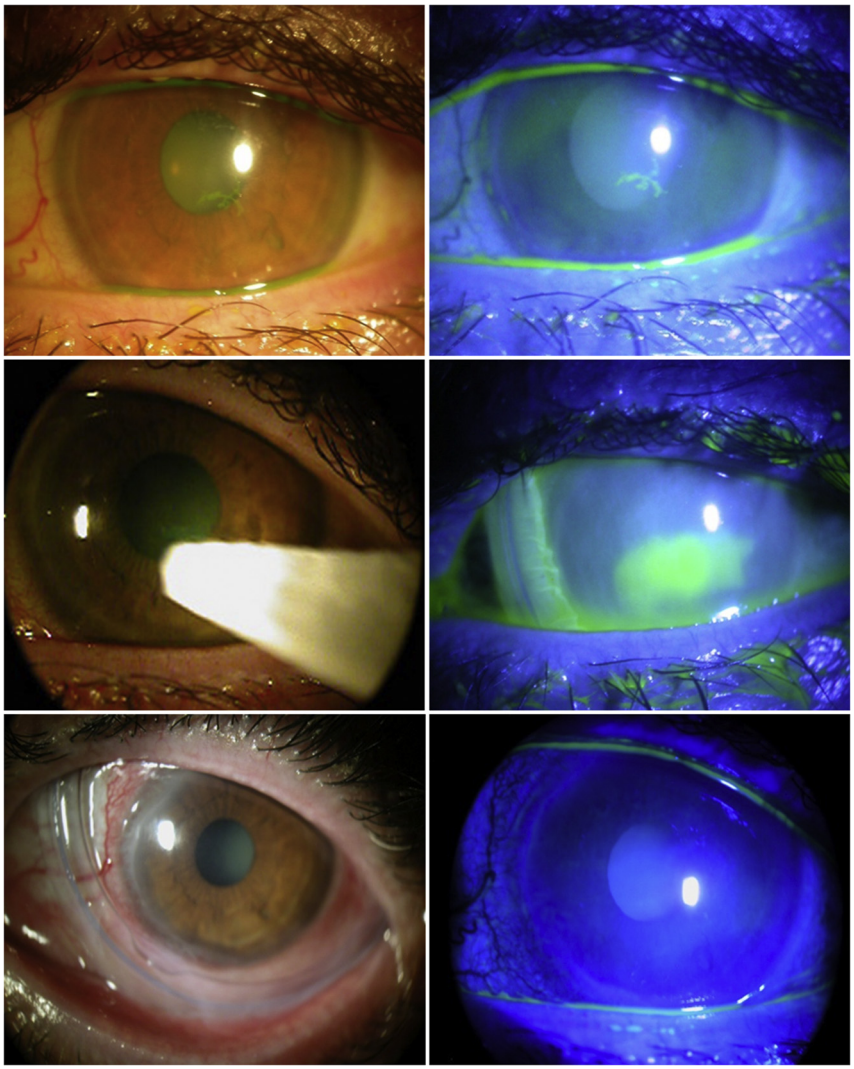

Fig. 1. Treatment of acute dendritic keratitis. Recurrent dendritic corneal ulcer (Top), treated with self-retained cryopreserved amniotic membrane after debridement (Middle), complete epithelization was achieved within 5 days and remained stable without recurrence (Bottom).

Download English Version:

https://daneshyari.com/en/article/5703349

Download Persian Version:

https://daneshyari.com/article/5703349

Daneshyari.com