



Case report

Malignant solitary fibrous tumor of the orbit: Spectrum of histologic features

Lilangi S. Ediriwickrema ^{a,1}, Michael Burnstine ^{a,b,2}, Maria S. Saber ^{a,3}, Narsing Rao ^{a,*}^a Department of Ophthalmology, University of Southern California, Los Angeles, CA, USA^b Eyesthetica, Oculofacial and Cosmetic Surgery Associates, Los Angeles, CA, USA

ARTICLE INFO

Article history:

Received 28 July 2016

Received in revised form

18 September 2016

Accepted 25 October 2016

Available online 28 October 2016

Keywords:

Solitary fibrous tumor

Orbit

Extra-pleural

Malignant

Immunoprofiling

ABSTRACT

Purpose: Primary malignant solitary fibrous tumor (SFT) of the orbit is a rare spindle cell neoplasm that requires excisional biopsy for histopathological diagnosis. We present a clinical case using contemporary immunohistochemical stains, report on the latest World Health Organization classification, and provide a review of the literature.

Observations: Report of a single case of a 65 year old male who presented with right-sided proptosis, limited adduction, ptosis, lateral globe displacement, and cheek festooning. Neuroimaging revealed a 2.2 cm, extraconal heterogeneous mass that diffusely enhanced.

En-bloc tumor resection confirmed SFT malignancy based upon nuclear atypia, hypercellularity, and increased mitotic activity (13 mitotic figures/10 high powered fields). Ki-67 showed 2% nuclear staining in the benign tumor and 10–15% staining in the malignant counterpart. Immunohistochemical analysis revealed diffuse Stat6 positivity, CD 34 positivity with partial lack of staining within the malignant portion, S-100 positivity in the malignant portion, and overall negativity for CAM 5.2, desmin, actin, CD 31, and CD 117.

Conclusions and importance: Immunoprofiling is helpful to making the diagnosis of malignant solitary fibrous tumor of the orbit. Complete tumor resection continues to be the preferred treatment. The behavior of extrathoracic SFT is unpredictable, and patients with SFT in all locations require careful, long-term follow-up.

© 2016 The Authors. Published by Elsevier Inc. This is an open access article under the CC BY-NC-ND license (<http://creativecommons.org/licenses/by-nc-nd/4.0/>).

1. Introduction

Initially described in the pleura by Stout in 1942, solitary fibrous tumors (SFT) are rare spindle cell neoplasms of mesenchymal origin. Today, SFTs comprise a spectrum of tumors ranging from those arising from the pleura with associated paraneoplastic syndromes such as hypoglycemia, to multiple soft tissue sites and the meninges.¹ Primary malignant orbital SFT, however, is a rare entity. We report an additional case that was diagnosed based upon current histopathology and immunoprofiling techniques.

* Corresponding author. Keck School of Medicine at USC, 1450 San Pablo Street, Suite 211, Los Angeles, CA 90033, USA.

E-mail addresses: lilangi@jhu.edu (L.S. Ediriwickrema), burnstin@usc.edu (M. Burnstine), maria.sibugsaber@med.usc.edu (M.S. Saber), narsing.rao@med.usc.edu (N. Rao).

¹ Keck School of Medicine at USC, 1450 San Pablo Street, Suite 5900, Los Angeles, CA 90033, USA.

² Eyesthetica, 625 South Fair Oaks, Suite 265, Pasadena, CA 91105, USA.

³ Keck School of Medicine at USC, NNT 4420, Health Sciences Campus, Los Angeles CA 90089, USA.

2. Case report

A 65 year old male presented with persistent swelling and discharge from the right eye for over nine months. Best corrected visual acuity was noted to be 20/40 and 20/25 in the right and left eyes, respectively. Pupils were round and reactive without afferent pupillary defect, visual fields were normal to confrontation, and intraocular pressures were normal in both eyes. On external examination, the patient had limitation on adduction of the right eye resulting in binocular horizontal diplopia on left gaze. The patient also had right upper eyelid ptosis and conjunctival injection that had been previously attributed to allergic conjunctivitis. Dilated funduscopic examination was normal without signs of disc edema, optic atrophy, or choroidal folds. Neuroimaging revealed a 2.2 cm heterogeneously enhancing right medial extraconal mass (Fig. 1).

The patient underwent a transcaruncular orbitotomy for biopsy, which revealed solitary fibrous tumor based on positive staining for CD34 and BCL2 on histopathological analysis. Subsequent en bloc orbital tumor removal revealed a malignant solitary fibrous tumor

with nuclear atypia, hypercellularity, and increased mitotic activity (13 mitotic figures/10 high powered fields). Ki-67 showed 2% nuclear staining in the benign tumor and 10–15% staining in the malignant counterpart. Immunohistochemical analysis revealed diffuse Stat6 positivity, CD 34 positivity with partial lack of staining within the malignant portion, S-100 positivity in the malignant portion, and overall negativity for CAM 5.2, desmin, actin, CD 31, and CD 117 (Fig. 2). The case and histology have been carefully reviewed by two pathologists. Since resection, the patient continues to be tumor free at approximately eighteen months in follow-up.

3. Discussion

Two percent of solitary fibrous tumors arise from soft tissue and typically affect individuals in their fifties. Hypoglycemia has been described; and ten to fifteen percent of patients have metastases at the time of diagnosis.¹ In 2013, the World Health Organization reclassified extrapleural solitary fibrous tumors to be a “ubiquitous mesenchymal tumor of fibroblastic type,” which shows a prominent “branching vascular pattern,” and rescinded the term, “hemangiopericytoma” (HPC).²

Historically, the term ‘hemangiopericytoma’ has been used to describe lesions with a characteristic “staghorn” branching vascular pattern. However, it appears that it may have been a misnomer; and in fact this growth pattern is shared by unrelated entities that are both benign and malignant. In 2006, Gengler and Guillou proposed categorizing these HPC-like tumors into lesions that infrequently display the characteristic features (i.e. synovial sarcoma), clearly show “myoid/pericytic differentiation” that are usually benign (i.e. glomangiopericytoma/myopericytoma, infantile myofibromatosis, and a subset of sinonasal HPCs), and those that are solitary fibrous tumors, which also includes fibrous-to-cellular lesions (i.e. giant cell angiofibromas and lipomatous HPCs).³

Orbital SFTs can present as unilateral proptosis, eyelid swelling, or dysmotility. Diagnostically, they are indolent lesions that are oftentimes heterogeneous with low T2 signal intensity on MRI.^{1,4} Tumor excision typically reveals well circumscribed, partially encapsulated, colorless masses that are firm and multinodular. SFTs

are oftentimes benign with intermediate biologic potential due to low rates of local recurrence or metastasis.^{2,4} Clinical and radiological features, however, do not necessarily correlate with histological signs of malignancy.

It is important to establish the diagnosis of malignant SFT because of their higher mortality rate. Immunohistochemical analysis continues to be the gold standard for diagnosis. Histological analysis of SFT reveals mixed hypo and hypercellular regions delineated by hyalinized collagen and thin vessels, as well as frequent myxoid changes and rare mitotic figures. Tumor cells usually stain positive for specific markers such as CD34 (90–95%) and Stat6, but variably to S-100 protein, keratin, and desmin.^{2–6}

In contrast, locally aggressive or malignant SFTs can show interval increase in size, increased cell mitoses, atypia, necrosis with and without hemorrhage, and infiltration into adjacent structures. Mitotic index appears to be the best prognostic indicator to date.² Areas of malignancy are typically CD 34 negative, while positive for Stat6, S-100, p53, cytokeratin, and certain gene fusion variants of NAB2-STAT6 (Table 1).^{1–4,6–9}

Long term follow-up is essential. Further efforts to identify signaling pathways that lead to tumor dedifferentiation and malignant transformation will likely establish prognostic indicators and targets for multimodal therapy. Currently, the identification of signaling pathways that portend poor prognosis has yet to be fully elucidated. Recent biomolecular studies suggest the potential role of the nuclear signal transducer and activator of transcription 6 (STAT6) gene, given the discovery of NGFI-A binding protein 2 (NAB2)-STAT6 as a SFT-specific fusion gene.^{8,9} However, while Stat6 is a highly specific marker for SFTs, the prognostic role of various NAB2-STAT6 fusion genes in determining disease free survival remains unclear.^{6,10} Future studies will continue to delineate the oncogenic cascade in malignant SFTs, and these genes may impact overall prognostication and serve as designer therapy targets.

4. Conclusions

Complete surgical resection with long term follow-up and longitudinal neuroimaging to monitor for recurrence is essential. Locally advanced, recurrent, or metastatic extrapleural SFT lesions

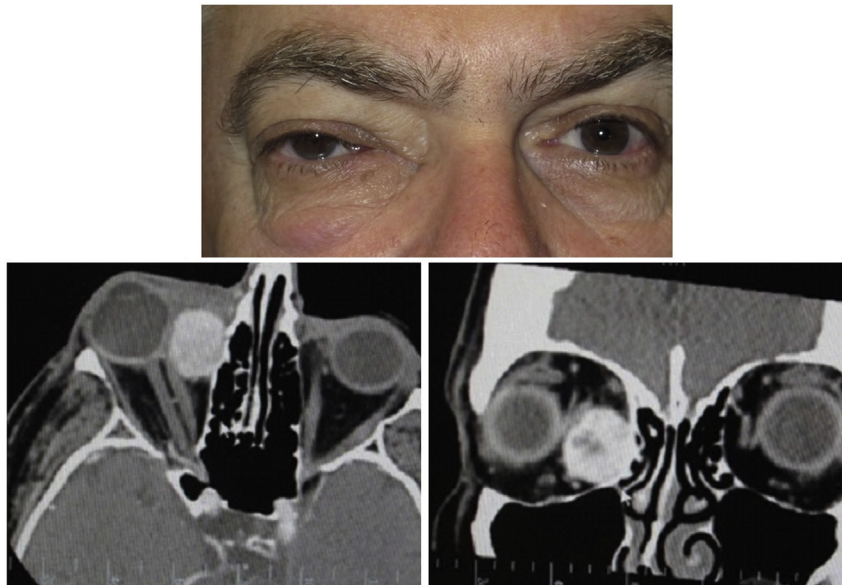


Fig. 1. Patient Characteristics: Patient presents with right-sided exophthalmos, lateral globe displacement, upper eyelid ptosis, and diminished adduction. Axial and coronal computed tomography scans reveal a large, enhancing, extraconal mass displacing the globe laterally.

Download English Version:

<https://daneshyari.com/en/article/5703382>

Download Persian Version:

<https://daneshyari.com/article/5703382>

[Daneshyari.com](https://daneshyari.com)