



ELSEVIER

## ORIGINAL ARTICLE

# Polyethylene dissociation from humeral stem status after reverse total shoulder arthroplasty

Karan A. Patel, MD, Kara L. Boyd, PA-C, Kevin J. Renfree, MD, Steven J. Hattrup, MD\*

*Department of Orthopedics, Mayo Clinic Arizona, Scottsdale, AZ, USA*

**Background:** Reverse shoulder arthroplasty (RSA) is an important treatment option for 4-part proximal humerus fractures in the elderly and arthrosis of the glenohumeral joint with incompetence of the rotator cuff. Unique complications do occur with use of this type of prosthesis.

**Methods:** We present 4 cases of polyethylene dissociation after RSA.

**Results:** In a series of 549 patients who underwent RSA, the incidence of polyethylene dissociation was found to be 0.7%.

**Conclusions:** Polyethylene dissociation is a rare complication after RSA. Surgeons should be aware of this possibility if a closed reduction of an RSA dislocation is not possible.

**Level of evidence:** Level IV; Case Series; Treatment Study

© 2017 Journal of Shoulder and Elbow Surgery Board of Trustees. All rights reserved.

**Keywords:** Shoulder; arthroplasty; complications; reverse; polyethylene; dissociation

Reverse shoulder arthroplasty (RSA) continues to gain popularity as a treatment option for a multitude of shoulder disorders after approval by the Food and Drug Administration in 2003. Current use of RSA includes glenohumeral arthropathy with severe rotator cuff deficiency, proximal humeral fractures in the elderly, and revision for failed arthroplasty with soft tissue deficiency. Because of its unique biomechanics, the RSA typically allows overhead shoulder motion by the restoration of glenohumeral stability and optimization of deltoid function.<sup>3,11,24</sup> Whereas long-term survivability of current-generation implants and techniques is not yet available, recent case series have reported 10-year implant survival rates of approximately 90%.<sup>9,12,20,25,27</sup>

As increased experience with RSA devices led to expanding indications, deeper understanding of complications

developed. Commonly recognized complications include scapular notching, dislocation, loosening, mechanical failure, infection, fractures, and neurapraxia. Complication rates vary in the literature and range between 10%-20% and up to 96% for scapular notching.<sup>1-8,10,14,16-18,21,24,27-29,31</sup> Dislocation rates in particular have been reported at up to 5% after RSA and can be influenced by soft tissue balance, glenosphere size, and version of the components.<sup>13,23,28,31</sup> The use of a deltopectoral vs. an anterosuperior approach has also been associated with a higher instability rate.<sup>19</sup> First-time dislocations may occasionally be treated with closed reduction and immobilization, and revisions are often required for repeated dislocations. Closed reduction, though, requires a mechanically intact implant, and failure of the implant requires preparation for open reduction with revision surgery.

We present a case series of 4 patients with a rare complication after RSA. These patients presented with signs, symptoms, and imaging consistent with dislocation but were found to have a dissociation of the polyethylene from the humeral head component, rendering a closed reduction impossible.

This study was determined to be exempt from approval by Mayo Clinic Institutional Review Board.

\*Reprint requests: Steven J. Hattrup, MD, Department of Orthopedics, Mayo Clinic Arizona, 5777 East Mayo Blvd, Phoenix, AZ 85054, USA.

E-mail address: [Hattrup.steven@mayo.edu](mailto:Hattrup.steven@mayo.edu) (S.J. Hattrup).

## Case reports

### Case 1

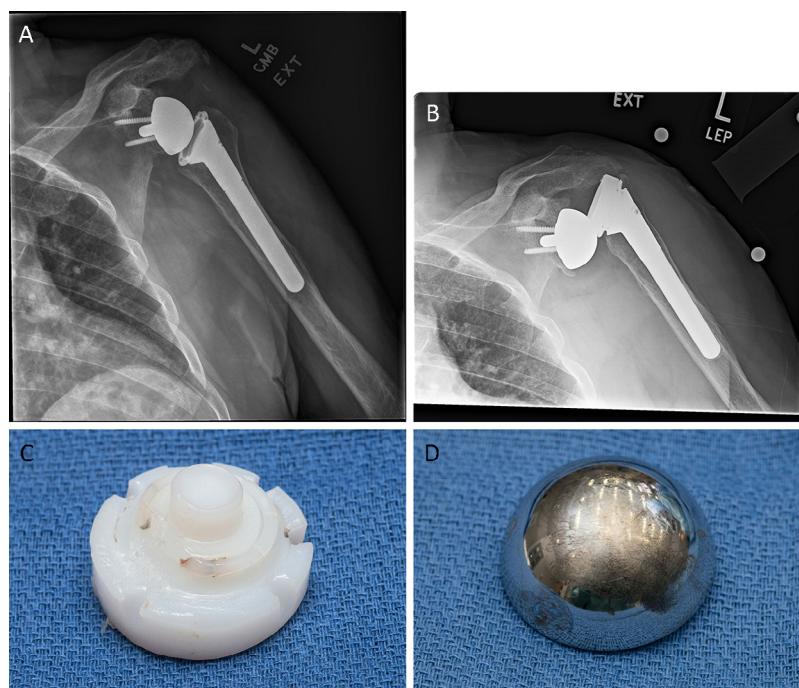
This 63-year-old man underwent a left RSA for rotator cuff arthropathy using the Trabecular Metal Reverse Shoulder System (TM RSA; Zimmer-Biomet, Warsaw, IN, USA). The articulating surfaces were a 40-mm glenosphere with a +3-mm polyethylene liner. The patient's perioperative and acute postoperative periods were without complications. Five months postoperatively, the patient developed sensations of instability in the prosthesis, leading to revision of his reverse total shoulder arthroplasty approximately 1.5 years postoperatively with insertion of a 9-mm metal humeral augment along with a +6-mm polyethylene. The original glenosphere and humeral stem were found to be stable and were retained. The patient's perioperative and postoperative courses were without complications. The patient presented to the clinic approximately 3 years later, describing decreased motion in his operative shoulder as well as concomitant clicking and instability. A radiograph of the left shoulder demonstrated a superiorly dislocated humeral stem in relation to the glenosphere (Fig. 1). He underwent repeated routine blood work, which again showed a normal white blood cell count and sedimentation rate of 8.7 and 21, respectively. His C-reactive protein level was somewhat elevated, measuring 12.9. The patient had an unsuccessful attempt at a closed reduction performed at an outside hospital. At open reduction,

the polyethylene component was found to be dissociated from the humeral stem and severely scored. The glenosphere also demonstrated signs of fretting. The polyethylene cup was downsized to 3 mm because of contraction of the soft tissues. Two of 3 tissue samples from surgery eventually grew *Propionibacterium acnes*, and he was treated with 6 weeks of cefazolin intravenously. At the 3-month postoperative visit, he was doing well, with no pain or mechanical symptoms with 150° of elevation and 50° of external rotation.

Nevertheless, the patient dislocated his RSA in his sleep 4 months postoperatively. Successful closed reduction was performed in the emergency department.

### Case 2

This 64-year-old man underwent a left RSA for a painful malunion of the proximal humerus. The TM RSA with a 40-mm glenosphere and +6-mm polyethylene cup was used. Two years after his initial surgery, the patient suffered a fall, leading to a superior dislocation of his RSA. He underwent an unsuccessful attempt at closed reduction. During this evaluation, he was also found to have a subdural hematoma, which required evacuation, substantially postponing the open reduction of the shoulder. Interval imaging demonstrated no changes to his dislocation during the next 5 months. Five months after the fall, the patient was taken to the operating room for revision of his dislocated RSA. During surgery, it was found that the polyethylene component had completely dissoci-



**Figure 1** These images from case 1 show a postoperative view (A) with concentric reduction and the subsequent dislocation (B). The inferior glenoid scalloping and lucency were noted on prior radiographs and found to be stable. Intraoperative photographs demonstrate the severe polyethylene wear (C). The amount of wear that occurred before the dissociation vs. after is indeterminate. The final image shows the damage to the glenosphere surface (D).

Download English Version:

<https://daneshyari.com/en/article/5710087>

Download Persian Version:

<https://daneshyari.com/article/5710087>

[Daneshyari.com](https://daneshyari.com)