



ELSEVIER

## ORIGINAL ARTICLE

# Nine-year outcome after anatomic stemless shoulder prosthesis: clinical and radiologic results

Nael Hawi, MD<sup>a,b,\*</sup>, Petra Magosch, MD<sup>c,d</sup>, Mark Tauber, MD<sup>a,e</sup>, Sven Lichtenberg, MD<sup>c</sup>, Peter Habermeyer, MD<sup>a</sup>

<sup>a</sup>Department of Shoulder and Elbow Surgery, ATOS Clinic Munich, Munich, Germany

<sup>b</sup>Trauma Department, Hannover Medical School, Hannover, Germany

<sup>c</sup>Department of Shoulder and Elbow Surgery, ATOS Clinic Heidelberg, Heidelberg, Germany

<sup>d</sup>Orthopaedic and Trauma Surgery Center, University Medical Centre Mannheim, University of Heidelberg, Heidelberg, Germany

<sup>e</sup>Department of Traumatology and Sports Injuries, Paracelsus Medical University, Salzburg, Austria

**Background:** Several stemless shoulder implants are available on the market, but only a few studies have presented results with sufficient mid- to long-term follow-up. The present study evaluated clinical and radiologic outcomes 9 years after anatomic stemless shoulder replacement.

**Methods:** This is a prospective cohort study evaluating the stemless shoulder prosthesis since 2005. Anatomic stemless shoulder replacement using a single prosthesis was performed in 49 shoulders; 17 underwent total shoulder replacement, and 32 underwent hemiarthroplasty. Forty-three patients were clinically and radiologically monitored after a mean of 9 years (range, 90-127 months; follow-up rate, 88%). The indications for shoulder replacement were primary osteoarthritis in 7 shoulders, post-traumatic in 24, instability in 7, cuff tear arthropathy in 2, postinfectious arthritis in 1, and revision arthroplasty in 2.

**Results:** The Constant-Murley Score improved significantly from 52% to 79% ( $P < .0001$ ). The active range of motion also increased significantly for flexion from 101° to 118° ( $P = .022$ ), for abduction from 79° to 105° ( $P = .02$ ), and for external rotation from 21° to 43° ( $P < .0001$ ). Radiologic evaluation revealed incomplete radiolucency in 1 patient without clinical significance or further intervention. No revision caused by loosening or countersinking of the humeral implant was observed.

**Conclusions:** The 9-year outcome after stemless shoulder replacement is comparable to that of third- and fourth-generation standard shoulder arthroplasty.

**Level of evidence:** Level IV; Case Series; Treatment Study

© 2016 Journal of Shoulder and Elbow Surgery Board of Trustees. All rights reserved.

**Keywords:** Stemless shoulder arthroplasty; primary osteoarthritis; post-traumatic osteoarthritis; shoulder; total shoulder arthroplasty; hemiarthroplasty; canal-sparing shoulder arthroplasty

Ethical Committee Approval was obtained from the Freiburger Ethik-Kommission.

\*Reprint requests: Nael Hawi, MD, ATOS Clinic, Department of Shoulder and Elbow Surgery, Effnerstraße 38, D-81925 München, Germany; Trauma Department, Hannover Medical School, Carl-Neuberg-Str. 1, D-30625 Hannover, Germany.

E-mail address: [hawi.nael@mh-hannover.de](mailto:hawi.nael@mh-hannover.de) (N. Hawi).

The surgical treatment option for severe glenohumeral arthritis is shoulder arthroplasty, resulting in loss of pain and improvement of shoulder function.<sup>5,10,31</sup> As a result of complications caused by the stemmed implant design, such as bone stock loss, intraoperative and postoperative periprosthetic fractures, malpositioning of the humeral implant, especially in

post-traumatic cases with malalignment, and an altered center of rotation, the development of new concepts has been necessary.<sup>7,24</sup>

To provide the advantages of 3-dimensional reconstruction of the humeral head and avoid stem-related complications, Biomet, Inc. (Warsaw IN, USA) introduced a stemless prosthesis, the Total Evolutive Shoulder System (TESS), in 2004.<sup>20</sup> The second stemless design available was the Eclipse shoulder prosthesis (Arthrex, Inc., Naples, FL, USA) and first introduced in 2005. In contrast to other implants, the Eclipse prosthesis offers epiphyseal and metaphyseal anchoring and is inserted over a compression screw for primary stability of the implant. A number of different stemless implants are currently available on the market. However, all types of prostheses aim to reconstruct the humeral center of rotation independent from the shaft axis and to avoid additional osteotomy of greater tuberosity in post-traumatic cases.

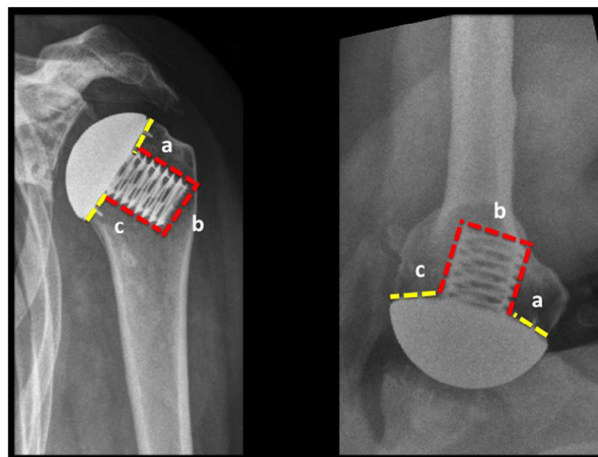
Short- and midterm outcomes available in the literature offer very promising clinical and radiologic results.<sup>4,5,9,22,25,29,33,39,41</sup> Nevertheless, studies with longer follow-up are needed to definitively prove the benefits of this kind of implant. Here, we present clinical and radiologic results obtained 9 years after implanting the Eclipse stemless anatomic shoulder prosthesis. In 2015 we published our results after stemless shoulder arthroplasty with a follow-up of 72 months.<sup>22</sup> The analyzed data and presented results of the current study may involve the same patient cohort, but all patients were evaluated at a different follow-up time.

## Materials and methods

This is a prospective cohort study evaluating the stemless shoulder prosthesis. The stemless shoulder prosthesis has been evaluated prospectively by the senior author (P.H.) since 2005. Included are 49 humeral arthroplasties (27 women and 22 men), with a mean follow-up of 9 years (range, 90-127 months). The patients were a mean age of 56 years (range, 21-81 years). The study excluded patients with rheumatoid arthritis, osteoporosis, and large subchondral cysts. All patients were seen at our hospital 6 weeks, 3 months, 6 months, and 1 year after surgery, and then annually for clinical and radiologic follow-up. Six patients were lost to follow-up, resulting in a follow-up rate of 88% (n = 43).

The age- and sex-related Constant-Murley Score was used to assess the clinical results.<sup>16,17</sup> The ISOBEX dynamometer (MDS Medical Device Solutions AG, Oberburg, Switzerland) was used to measure abduction strength. Radiologic follow-up was performed by examination in 3 planes: true anteroposterior, axillary, and scapular Y views. These planes were used to assess humeral- and glenoid-sided radiolucency, to evaluate changes in mineral bone density, to analyze secondary glenoid wear in cases of hemiarthroplasty, and to observe possible superior migration of the humeral head over time (gothic arc). We used a previously described zone classification in the anteroposterior (AP) and the axillary views by dividing the surrounding humeral and glenoidal bony area in 3 zones (zone A, B, and C; Fig. 1).<sup>22</sup>

Superior migration of the humeral head was defined as progressive discontinuation of the gothic arc compared with the postoperative AP radiographs 6 weeks after surgery. Rotator cuff deficiency was



**Figure 1** We used a previously described zone classification system in the anteroposterior and the axillary views by dividing the surrounding humeral bony area in three different zones (zone a, b, and c).

defined as migration of the humeral head in addition to a loss of active range of motion.

A total of 32 patients were treated with hemiarthroplasty and 17 with total shoulder arthroplasty using a metal-backed glenoid (n = 13) component or a cemented all-polyethylene-keeled glenoid (n = 4) component. Fig. 2 shows a 78-year-old woman 10 years after the hemiarthroplasty procedure. All data were collected as part of the standardized clinical investigation through experienced orthopedic surgeons (P.H., P.M., S.L., M.T.), and all patients provided written consent for the use of their anonymized data.

## Surgical technique

The procedure was performed in all patients by the senior author. The patient was placed in a beach chair position after general anesthesia and interscalene brachial plexus block. A deltopectoral approach was used, and arthrotomy was performed by subscapularis tenotomy. The humeral head was resected at the level of the anatomic neck, the trunnion size was determined using a drill template, and the length of the cage screw was determined using a special cage screw sizer.

After the glenoid arthroplasty, if needed, was completed, the definite trunnion was seated onto the cortical rim of the anatomic neck without overlap, and the definite cage screw was inserted into the cancellous metaphyseal bone near, but not perforating, the lateral cortex. Thus, trunnion compression is achieved resulting in primary stable head fixation. A trial humeral head was used to determine the definite head size. After the humeral head was placed onto the trunnion, reattachment of the subscapularis tendon and wound closure were performed in standard fashion.

## Postoperative rehabilitation

After surgery, the shoulder was immobilized by an abduction brace for 3 weeks. Rehabilitation began on the first postoperative day, restricted to passive motion (45° flexion, 30° abduction, 45° internal rotation, 10° external rotation). The range of motion was

Download English Version:

<https://daneshyari.com/en/article/5710396>

Download Persian Version:

<https://daneshyari.com/article/5710396>

[Daneshyari.com](https://daneshyari.com)