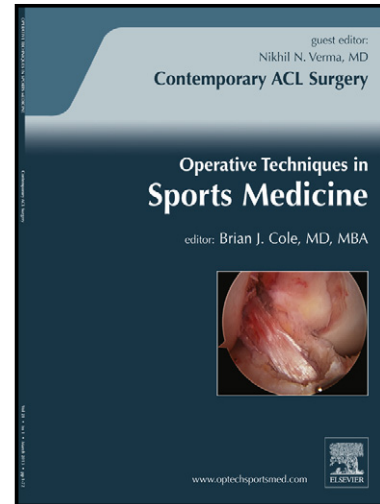


# Author's Accepted Manuscript

Partial rotator cuff Tears in throwing athletes

Jeffrey R. Dugas MD, Taylor P. Mathis MD



PII: S1060-1872(16)30007-7  
DOI: <http://dx.doi.org/10.1053/j.otsm.2016.04.007>  
Reference: YOTSM50553

To appear in:  
*Oper Tech Sports Med*

Cite this article as: Jeffrey R. Dugas MD, Taylor P. Mathis MD, Partial rotator cuff Tears in throwing athletes,  
*Oper Tech Sports Med* , <http://dx.doi.org/10.1053/j.otsm.2016.04.007>

This is a PDF file of an unedited manuscript that has been accepted for publication. As a service to our customers we are providing this early version of the manuscript. The manuscript will undergo copyediting, typesetting, and review of the resulting galley proof before it is published in its final citable form. Please note that during the production process errors may be discovered which could affect the content, and all legal disclaimers that apply to the journal pertain.

## Partial Rotator Cuff Tears in Throwing Athletes

Jeffrey R. Dugas, MD  
Professor, American Sports Medicine Institute  
Andrews Sports Medicine and Orthopedic Center  
Birmingham, AL

Taylor P. Mathis, MD  
Fellow, American Sports Medicine Institute  
Andrews Sports Medicine and Orthopedic Center  
Birmingham, AL

From American Sports Medicine Institute  
Birmingham, AL

Email: [Jeff.Dugas@andrewscenters.com](mailto:Jeff.Dugas@andrewscenters.com)  
Phone: (205) 939-3699  
Fax: (205) 581-7155  
Mailing Address: 805 St. Vincent's Drive, Suite 100  
Birmingham, AL 35205

Draft - Partial Rotator Cuff tears in Throwing Athletes

Andrews Sports Medicine Institute, Birmingham, AL

### Abstract

The throwing shoulder presents many challenges for the treating orthopedic surgeon. High functional demands, season-specific schedules, and complex pathologies make proper evaluation and treatment difficult, and accurate diagnosis is especially important in decision making in this difficult group of patients.

Adaptive changes must be differentiated from pathologic injury, and a detailed and accurate history and physical exam is crucial. Often multiple abnormalities are seen on imaging. Advanced imaging must be paired with examination to determine the

Download English Version:

<https://daneshyari.com/en/article/5710967>

Download Persian Version:

<https://daneshyari.com/article/5710967>

[Daneshyari.com](https://daneshyari.com)