



Available online at
ScienceDirect
www.sciencedirect.com

Elsevier Masson France
EM|consulte
www.em-consulte.com/en



Original article

Influence of fixation point of latissimus dorsi tendon transfer for irreparable rotator cuff tear on glenohumeral external rotation: A cadaver study



K. Bargoin^{a,*}, M. Boissard^b, J. Kany^c, J. Grimberg^d

^a Le Confluent-Nouvelles Cliniques Nantaises, Nantes, France

^b Centre Hospitalier Universitaire, Nantes, France

^c Clinique de l'Union, Saint Jean, France

^d Institut de recherche en chirurgie orthopédique et sportive, Paris, France

ARTICLE INFO

Article history:

Received 20 December 2015

Accepted 5 September 2016

Keywords:

Latissimus dorsi

Rotator cuff tear

Tendon transfer

Joint range of movement

Cadaver study

ABSTRACT

Latissimus dorsi tendon transfer is a surgical option for treating irreparable posterosuperior rotator cuff tears, notably when attempting to reconstruct active external rotation. We hypothesized that the positioning of the transfer's point of fixation would differ depending on the desired elbow-to-body external rotation or external rotation with the elbow abducted.

Material and methods: Seven shoulders from four whole frozen cadavers were used. We created two systems to install the subject in a semi-seated position to allow external rotation elbow to body and the arm abducted 90°. Traction sutures were positioned on the latissimus dorsi muscle and a massive tear of the rotator cuff was created. We tested six different transfer positions. Muscle contraction of the latissimus dorsi was stimulated using 10-N and 20-N suspended weights.

Results: The point of fixation of the latissimus dorsi on the humeral head had an influence on the elbow-to-body external rotation and with 90° abduction ($P < 0.001$). The fixation point for a maximum external rotation with the elbow to the body was the anterolateral position ($P < 0.016$). The fixation point for a maximum external rotation at 90° abduction was the position centered on the infraspinatus footprint ($P < 0.078$).

Conclusion: The optimal point of fixation differs depending on whether external rotation is restored at 0° or 90° abduction.

Level of evidence: Fundamental study, anatomic study.

© 2016 Elsevier Masson SAS. All rights reserved.

1. Introduction

Muscle-tendon transfers are frequently used to treat muscle paralysis. Latissimus dorsi (LD) tendon transfer is a surgical option for treatment of irreparable posterosuperior rotator cuff tears, initially proposed by Gerber et al. in 1988 [1–4]. The objective of this surgery is to reduce pain and restore shoulder function [1,3,5–10]. Gerber et al. have recently shown good long-term results for this indication [11]. A massive and irreparable tear of the rotator cuff is defined as a tear involving more than two tendons [12] with reattachment to the greater tubercle impossible despite extended release [13].

Active external rotation of the glenohumeral joint intervenes in many basic daily activities such as eating, shaving, shaking hands, and combing one's hair [14,15]. Active external rotation of the shoulder solicits the infraspinatus and teres minor muscles depending on the arm position. External rotation elbow to body at 90° abduction is assessed through functional tests (dropping sign and hornblower's sign) [16–18]. Biomechanical studies on LD transfer have contributed to improving the fixation and positioning of tendon transfer [19]. However, some of these studies were conducted with computer simulations of these movements [20–24], not necessarily accurately representative of actual biomechanics.

Shoulder tendon transfers have shown variable results in the literature [25–27]. LD transfer should respect several fundamental biomechanical rules to function properly [28,29]: physiological tension of the tendon transferred, the least invasive possible surgical exposure to reduce postoperative peritendinous fiber reactions, synergetic work of the tendon transferred, the type fixation

* Corresponding author at: NCN, Le Confluent, 4 rue Eric Tabarly, 44277 Nantes Cedex 2, France.

E-mail address: dr.bargoin@gmail.com (K. Bargoin).

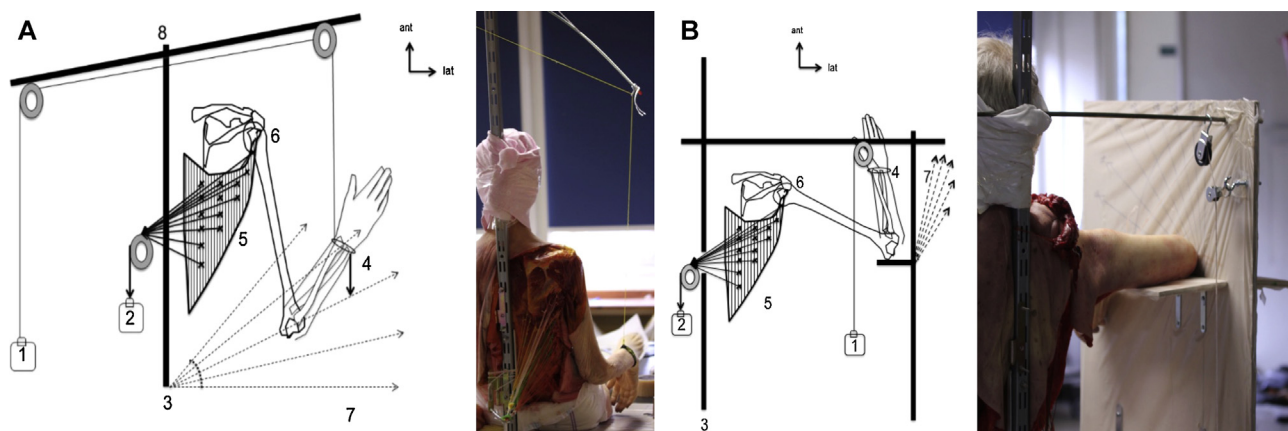


Fig. 1. (A) External rotation measured with the elbow to the body. (B) External rotation measured with the arm abducted 90°. 1 – Suspended weight equivalent to the forearm weight; 2 – suspended weight to simulate contraction of the latissimus dorsi (10 N and 20 N); 3 – system for the beach-chair position; 4 – pointer attached to the wrist; 5 – latissimus dorsi with traction sutures every 2 cm²; 6 – fixation point of the tendon transfer on the humeral head; 7 – measurement system using direct reading in degrees; 8 – rotating arm for external rotation.

resisting physiological traction forces, and ideal positioning to restore joint movements.

In addition, arthroscopic procedures have recently been proposed to improve the result given its less invasive approach [30–32]. The tendon can also be tubularized [33] to obtain a specific fixation and provide sufficient resistance to traction [19,34]. The most frequently used position is located at the junction of the supraspinatus footprint and the infraspinatus [22,35].

To date, the position of the tendon transfer on the external rotation using an entire, fresh subject in the semi-seated position has not been studied. The objective of the present study was therefore to assess the optimal fixation point for the tendon transfer of the LD on the humeral head to restore active external rotation. We hypothesized that the positioning of the transfer fixation point would differ depending on the external rotation desired, elbow to body or with the elbow abducted.

2. Materials and methods

We used seven shoulders from fresh-frozen whole-body cadavers, three right shoulders and four left shoulders. The cadavers were preserved at –15 °C for a maximum 10 days after their death. All the shoulders had complete freedom of movement. Two of the authors performed the dissections.

The exclusion criteria were a cadaver more than 10 days since death, rotator cuff tear already present, a history of shoulder surgery, osteoarthritis, and an injured shoulder.

2.1. Preparation of tendon transfer

A wide posterior approach was opened to expose the LD muscle and its proximal insertions up to its distal insertion. We released it from its skin attachments and from the inferior angle of the scapula. The deltoid was excised to allow access to the rotator cuff. The tendon of the LD was tubularized with Ethibond suture (ETHIBOND EXCEL size 1, Ethicon® Cincinnati, OH, USA).

During the dissection, the neurovascular pedicle of the LD was identified and preserved. The traction sutures were placed every 2 cm² using cross stitches through the entire thickness of the muscle on the different bodies of the LD. Each traction suture was adjusted independently, following the orientation of the muscle fibers, and then they were joined for traction on the entire muscle.

A massive tear of the rotator cuff was created by resecting the infraspinatus and supraspinatus tendons. The subscapularis, the

long head of the biceps, the capsule, the coracoacromial and coracoclavicular ligaments were left intact.

2.2. Installation in the beach-chair position

Two adjustable systems, adapted to the size of the cadavers, were created to install them in the beach-chair position. The first system was designed to allow external rotation, elbow to the body, maintaining the elbow flexed at 90° using a suspended weight attached to the wrist. This weight was equivalent to the weight of the forearm. The amplitude of the external rotation was assessed with no obstruction between the forearm and the measurement system (Fig. 1A). The second system was designed to allow external and internal rotation, the arm abducted 90°, using a block placed under the elbow. A suspended weight, equivalent to the weight of the forearm, was attached to the wrist to compensate for gravity (Fig. 1B).

2.3. Fixation

The footprint of each tendon on the greater tubercle was identified and mapped to facilitate the reproducibility of each fixation point [36].

Each shoulder was tested with six different positions of the tendon on the humeral head using staple fixation. Staple fixation for the tendon was preferred over anchor or screw fixation to reduce the risk of humeral head fracture and to allow repositioning the transplant as often as needed.

The LD tendon was tubularized and attached on the insertion area of the humeral head with two metal staples in a cross to simulate an anchor fixation.

Six positions were tested (Fig. 2A): position X1: lower part of the infraspinatus footprint, X2: centered on the infraspinatus footprint, X3: between the footprint of the infra- and supraspinatus, X4: centered on the footprint of the supraspinatus, X5: anterolateral position, X6: double fixation on the anterolateral position and the lower part of the infraspinatus footprint (X1 + X5).

2.4. Measurement

LD contraction was simulated using a suspended weight from 10 N to 20 N. Each position was tested three times at 0° and 90° abduction. The amplitude of the external rotation after simulation of the LD contraction was measured in degrees by a direct reader

Download English Version:

<https://daneshyari.com/en/article/5711129>

Download Persian Version:

<https://daneshyari.com/article/5711129>

[Daneshyari.com](https://daneshyari.com)