



Contents lists available at ScienceDirect

## International Journal of Pediatric Otorhinolaryngology

journal homepage: <http://www.ijporlonline.com/>

## Case Report

## Refractory sleep apnea caused by tubal tonsillar hypertrophy



Seok Chan Hong, Hyun Jin Min, Kyung Soo Kim\*

Department of Otorhinolaryngology – Head and Neck Surgery, Chung-Ang University College of Medicine, Seoul, Republic of Korea

## ARTICLE INFO

## Article history:

Received 29 December 2016

Received in revised form

6 February 2017

Accepted 8 February 2017

Available online 11 February 2017

## Keywords:

Tubal tonsil

Snoring

Adenoid

Tonsil

Adenotonsillectomy

## ABSTRACT

Snoring/sleep apnea are usual symptoms of adenotonsillar hypertrophy, and adenotonsillectomy is usually recommended. In rare cases, symptoms remain after surgery, and tubal tonsil hypertrophy could be the cause. We experienced a pediatric patient whose symptoms were refractory snoring/sleep apnea although he previously underwent three times of adenotonsillectomy. We diagnosed tubal tonsil hypertrophy which was the cause of refractory symptoms, and decided to perform volume reduction with radiofrequency ablation. We suggest that tubal tonsil hypertrophy should be taken into account of the cause of refractory sleep apnea after adenotonsillectomy, and volume reduction with radiofrequency may be an effective method.

© 2017 Elsevier B.V. All rights reserved.

## 1. Introduction

Severe adenotonsillar hypertrophy is the most common cause of respiratory alterations in children [1]. Adenoidectomy is generally considered to be the treatment of obstructive adenoids, recurrent chronic adenoiditis, chronic sinusitis, and recurrent otitis media, and adenotonsillectomy is the first-line treatment of pediatric sleep-disordered breathing [2]. Also, after adenoidectomy, various symptoms, especially snoring and sleep apnea, are mostly improved [3].

However, with very rare probability, symptoms may recur after adenotonsillectomy. Recurrent and residual adenoid, tubal tonsil hypertrophy and rhinosinusitis have been known to be the main causes [4].

Tubal tonsils, also known as the Eustachian tonsils, tonsilla tubaria, or Gerlach tonsils are found beneath the mucosa of the Eustachian tube within Rosenmuller fossa [5]. Removal of adenoid tissue could lead to the compensatory reactive hyperplasia of remaining lymphoid tissue, and this is a possible hypothesis of tubal tonsil hypertrophy [4]. Although tubal tonsil hypertrophy might be one of the causes of postoperative recurrent snoring and sleep apnea, little concern has been paid regarding tubal tonsil

hypertrophy in pediatric snoring and sleep apnea patients.

Recently, we experienced a pediatric patient who complained of severe snoring and sleep apnea which was refractory to three times of previous adenotonsillectomy. Based on computed tomography (CT) and retrovelar nasopharyngoscopy with a 70° endoscope, we concluded that tubal tonsil hypertrophy was the cause of refractory symptoms. We think our case might be helpful in doctors who encounter pediatric patients with recurrent or refractory snoring and sleep apnea after adenotonsillectomy.

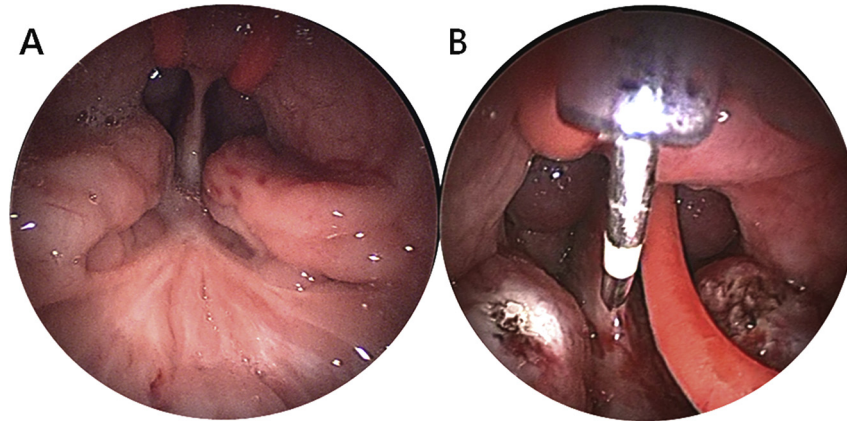
This study was approved by the Institutional Review Board of Chung-Ang University College of Medicine (1702-001-16033).

## 2. Case report

A 10-year-old boy was referred to our hospital with the symptoms of snoring, mouth breathing and sleep apnea, with the discomfort of 10 VAS score, which is a tool by which patients indicated their general satisfaction with 1 meaning least and 10 meaning maximum satisfaction on a 10 cm line. He had previously received adenotonsillectomy and additional two times of adenoidectomy for same symptoms at 3, 5, 7 years old. Although the symptoms were temporarily improved after each operation, they were still remained and got worse within one month of operation. He had no other medical (including allergic rhinitis and asthma) and psychological diseases. On physical examination, both palatine tonsils were absent, but retropharyngeal airway was severely narrowed. Although, we supposed that the patient has obstructive sleep apnea (OSA) based on parents' testimony, we tried to confirm

\* Corresponding author. Department of Otorhinolaryngology – Head and Neck Surgery, Chung-Ang University College of Medicine, 102, Heukseok-ro, Dongjak-gu, Seoul, 156-755, Republic of Korea.

E-mail address: [99-21045@hanmail.net](mailto:99-21045@hanmail.net) (K.S. Kim).



**Fig. 1.** Pre- and intra-operative endoscopic view of nasopharynx. A. Endoscopic transoral view of nasopharynx demonstrating bilateral tubal tonsil hypertrophy. B. Radiofrequency ablation with celonpro breath (Olympus) was performed as a treatment of tubal tonsil hypertrophy.

about the presence of OSA. Therefore, we performed polysomnography using Watch-PAT 200 for the purpose of our research, although Watch-PAT 200 is not recommended for children. Apnea hypopnea index (AHI) was 12.9 by polysomnography (Watch-PAT 200), and diagnosed as severe obstructive sleep apnea (OSA). On CT images taken to evaluate the causes of snoring and sleep apnea in head and neck area, they showed bilateral, heart-shaped enlargement of lymphoid tissues on both lateral pharyngeal wall, which was suggestive of tubal tonsil hypertrophy (Fig. 1). Based on these findings, we decided to perform surgery for volume reduction with biopsy for ruling out malignancy, and did not perform any medical treatment before surgery.

Under general anesthesia, tubal tonsil hypertrophy was observed through retrovelar nasopharyngoscopy using a 70°-endoscope. Remnant/recurred adenoid from nasopharyngeal wall was not observed (Fig. 2A). We got a piece of tissue for biopsy from hypertrophied tubal tonsil and performed volume reduction using with radiofrequency (Celonpro breath, Olympus) (Fig. 2B). The biopsy result was just reactive lymphoid hyperplasia. The patient was satisfied with surgical outcome, and snoring and sleep apnea was decreased to VAS score 1 after 1 week of operation. There were no recurrence and complications until 3 months after operation.

### 3. Discussion

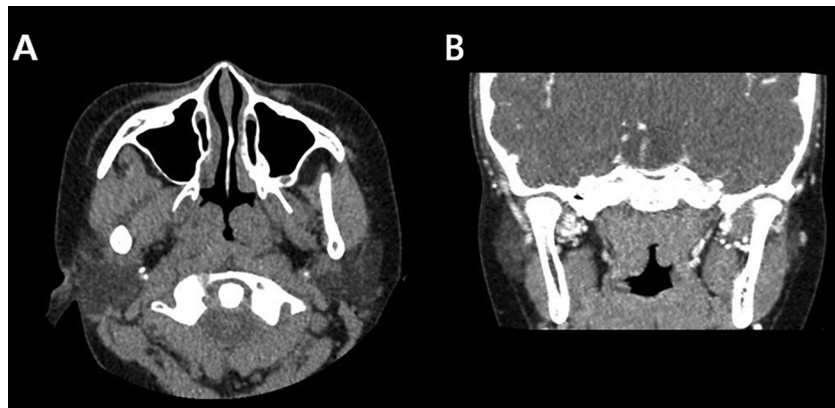
Adenotonsillar hypertrophy is associated with various disease

entities such as recurrent otitis media, upper airway obstruction and obstructive sleep disorder syndrome [6]. Surgical removal of hypertrophied adenotonsillar tissues is known to be effective treatment for snoring and sleep apnea, reported to be about 80% in cure rate [1].

In case of recurrent snoring and sleep apnea after adenotonsillectomy, tubal tonsil hypertrophy, recurrent/residual adenoid and chronic rhinosinusitis have been known to be the main causes [4]. Recurrent/residual adenoid and presence of rhinosinusitis could be evaluated by simple X-ray or nasal endoscopic findings. However, it is not easy to evaluate the presence of tubal tonsil hypertrophy because simple X-ray such as PNS view or 0° sinus endoscopy is not helpful for the detection of tubal tonsil hypertrophy. Also, it was reported that tubal tonsil hypertrophy was not related to various clinical features such as BMI and gender [4]. So, there is no predictable factor.

In our case, although patient underwent three times of adenotonsillectomy and adenoidectomy, snoring and sleep apnea were persistent. We have found that there was no remnant adenotonsillar tissue, or infection in upper airway such as rhinosinusitis. With pre-operative CT and 70° endoscopic findings during operation, we could not find definite septal deviation or concha bullosa which could be the reasons of recurrent OSA after tonsils and adenoids are removed. Therefore, we conclude that tubal tonsil hypertrophy was the main cause of snoring and sleep apnea.

Regarding the treatment of tubal tonsil hypertrophy, there were very few previously reported studies. Thermal ablation and closed



**Fig. 2.** CT images of patient. A. An axial view shows enlarged lymphoid tissue on both lateral sides. B. A coronal view shows a heart-shaped enlarged lymphoid tissue mass.

Download English Version:

<https://daneshyari.com/en/article/5714671>

Download Persian Version:

<https://daneshyari.com/article/5714671>

[Daneshyari.com](https://daneshyari.com)