



Thoracic wall reconstruction with bioabsorbable plates in pediatric malignant thoracic wall tumors



Guillén G.^{a,*}, García L.^a, Marhuenda C.^b, Pellisé F.^c, J.A. Molino^a, C.G. Fontecha^c, López S.^a, Lloret J.^a

^a Pediatric Surgery Department, Hospital Vall d'Hebron, Barcelona, Spain

^b Pediatric Surgery Department, Hospital Son Espases, Palma de Mallorca, Spain

^c Orthopedics Department, Hospital Vall d'Hebron, Barcelona, Spain

ARTICLE INFO

Article history:

Received 17 February 2016

Received in revised form 22 August 2016

Accepted 24 August 2016

Key words:

Pediatrics

Chest wall

Ewing's sarcoma

Osteosarcoma

Bioabsorbable implants

Scoliosis

ABSTRACT

Aim: Childhood malignant chest wall tumors may require extensive surgical resection and reconstruction with musculoskeletal flaps or non-resorbable prosthetic materials. Implant-related complications and scoliosis often occur. This study analyzes the outcomes of chest wall reconstruction using resorbable plates as an alternative approach.

Methods: Retrospective review (2007–2015) of patients who underwent resection of malignant primary chest wall tumors in 2 tertiary pediatric centers. Reconstruction was performed using copolymer (L-lactic and glycolic acid) plates, fixed to the ribs and surrounding structures with copolymer screws and/or polyglactin sutures.

Results: Eight patients aged 10.6 ± 2.6 years were treated. There were no operative complications, and implant removal was not required in any case. Six patients received postoperative radiotherapy. Over follow-up (39.6 months, range 9.4–78), chest wall shape was maintained in all, and there were no radiological artifacts. Three patients developed scoliosis (Cobb 17°–33°), but treatment was needed only in one, who had undergone hemivertebrectomy. There were no cases of local tumor relapse. One patient died because of metastatic spread.

Conclusions: Implantation of bioabsorbable L-lactic and glycolic acid copolymer plates with a relatively simple technique provided a rigid, stable reconstruction with only mild mid-/long-term complications. Resorbable plates may be a good alternative for pediatric chest wall reconstruction.

Level of evidence: IV.

© 2017 Elsevier Inc. All rights reserved.

Primary malignant chest wall tumors are uncommon in the pediatric age. Management of this condition is complex and requires a multidisciplinary approach, in which a combination of chemotherapy, radiotherapy, and surgical resection has yielded improved survival rates [1]. A key factor in survival is procuring tumor-free surgical margins [2]. This may require extensive resections that can lead to chest wall deformities, scoliosis, and restrictive pulmonary disease at long term [3]. It is a challenge for surgeons and an essential part of the surgical treatment to achieve adequate reconstruction of the chest wall.

The objectives in chest wall reconstruction are to protect the thoracic viscera and preserve their physiologic functions, and to attain an acceptable cosmetic outcome. To achieve these goals, various techniques based on the use of autologous tissue flaps have been described, although they are technically complex and not exempt from associated complications [4,5]. As an alternative to these reconstructive techniques, the use of several types of resorbable and non-resorbable

materials has been reported [6]; nonetheless, consensus regarding the ideal material for this purpose is lacking.

In this study, we analyze our experience with chest wall reconstruction using rigid, malleable copolymer plates composed of 82% L-lactic acid and 18% glycolic acid, a material that is resorbed in 12 months' time and replaced by fibrosis. There is broad experience in pediatric use of this material for craniofacial surgery [7].

1. Material and methods

This is a retrospective study of the medical records of pediatric patients diagnosed with primary malignant chest wall tumors in 2 tertiary pediatric oncology referral centers between 2007 and 2015. In the diagnostic workup, all patients underwent plain chest radiography, computed tomography (CT) scanning, magnetic resonance imaging (MRI), and Tru-Cut biopsy in the diagnostic workup. Patients were treated according to the protocols of the Spanish Society of Pediatric Hematology and Oncology (SEHOP, *Sociedad Española de Hematología y Oncología Pediátrica*). All patients received preoperative and postoperative chemotherapy; radiotherapy and stem cell transplantation were performed as needed, according to the protocols.

* Corresponding author at: Hospital Universitario Vall d'Hebron, Pediatric Surgery Department, Surgical Oncology Unit, Passeig de la Vall d'Hebron, 119-129, 08024, Barcelona, Spain. Tel.: +34 934893094; fax: +34 934893099.

E-mail address: gguillen@vhebron.net (G. Guillén).

In the surgery workup, patients underwent preoperative CT with 3D reconstructions to evaluate the resectability of the lesion, the extent to which the ribs and spine were affected, and to estimate the size of the chest wall defect to be reconstructed.

All procedures had been performed by the same 2 surgeons, with experience in both oncologic and thoracic pediatric surgery (GG and CM). Tumor excision and chest wall reconstruction were done in the same procedure. Before performing the resection, an exploratory thoracoscopy was carried out to determine the intercostal space for the thoracotomy and to assess invasion of adjacent organs. Thoracotomy was performed with complete removal of the affected rib (in some cases with disarticulation) and resection of the superior and inferior ribs when required to obtain tumor-free margins. The posterior arch of the ribs (3–4 cm) was preserved whenever possible. A double hemivertebrectomy was needed in 1 patient to achieve complete excision of the mass without violating the tumor margins. The resection included the surrounding soft tissues, the biopsy trajectory, the intercostal muscles, pleura, and any adjacent structures in which tumor invasion was suspected.

Chest wall reconstruction used L-lactic acid and glycolic acid copolymer plates (LactoSorb, Lorenz Plating System, Biomet Microfixation, Jacksonville, FL), a biodegradable material that is resorbed within 1 year and replaced by fibrosis. The plates were cut to the size and shape of the defect and formed with heat. They were then fixed to the surrounding ribs and tissues at the resection margins using screws of the same copolymer and/or interrupted 1–0 or 2–0 polyglactin sutures (Fig. 1). As a reference, the cost of the material in our setting is around 1250 euros for a 10 × 10-cm plate and 50 euros for each screw. We usually place 4 to 6 screws to fix the plate to bony structures, and then place several pericostal and muscle stitches to achieve optimal fixation. In one patient the diaphragm was reimplanted in the prosthetic plate. At least one intrapleural chest drain was placed in all patients.

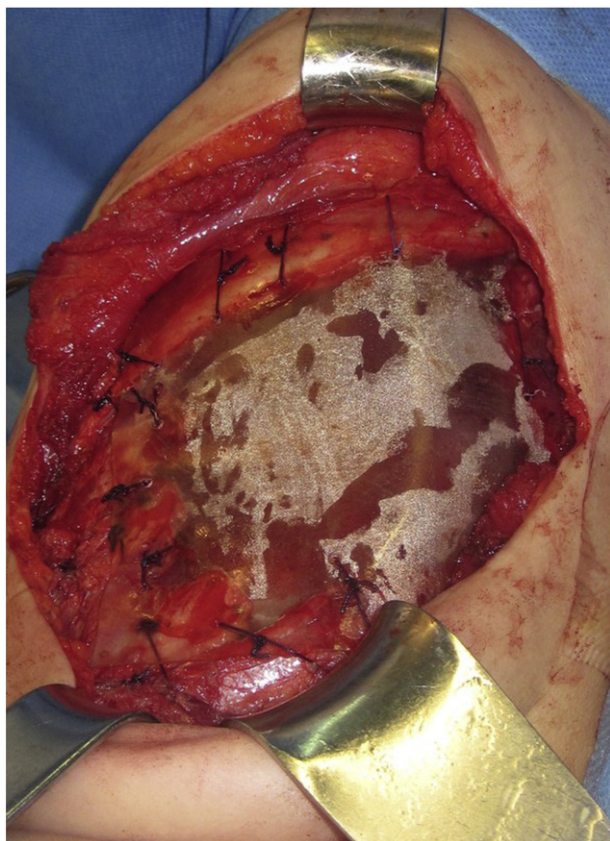


Fig. 1. Case 4: Chest wall reconstruction using resorbable copolymer plates fixed to the borders of the defect with screws and polyglactin sutures.

Patient follow-up was performed according to the oncology protocols (including MRI and CT), with subsequent yearly outpatient controls and chest radiography. The variables analyzed for the study were survival, local or distant recurrence, scoliosis severity determined by Cobb angle measurement, chest wall morphology on imaging study, presence of radiologic artifacts, and final aesthetic outcome.

2. Results

Eight patients (7 girls, 1 boy) with a mean age of 10.6 ± 2.6 years (Table 1) underwent surgery (GG 5 cases, CM 3 cases). Ewing's sarcoma was diagnosed in 7 patients and osteosarcoma in 1. At the time of the diagnosis, 5 patients had pulmonary metastasis. All patients received neoadjuvant chemotherapy.

En bloc resection was carried out in all cases, and the patient with osteosarcoma additionally required a T9–T10 hemivertebrectomy (Table 2). Suspicious pulmonary nodules were resected in 3 patients. All patients underwent resection of 2 or more ribs, and 5 patients had partial posterior arch resection of more than 1 rib. Microscopically tumor-free margins were obtained in all patients.

The chest wall was reconstructed with resorbable plates, and there were no intraoperative complications. In the patient who underwent hemivertebrectomy, a T8–T11 spinal fusion was carried out. Postoperative complications included 2 pleural effusions that did not require treatment, and a skin flap necrosis in the osteosarcoma patient requiring graft placement.

Six patients with Ewing's sarcoma received postoperative radiotherapy (45 to 55 Gy) based on the criteria of the SEHOP therapeutic protocols. Four patients additionally underwent stem cell transplantation.

Mean follow-up was 39.6 months (9.4–78), there were no cases of local recurrence or second neoplasms, with an overall survival and event free survival of 87.5%. One patient died because of pulmonary metastasis refractory to treatment at 4 years following the intervention. Of note, this patient was operated through a thoracotomy 13 months after the initial procedure, with no operative difficulties related to the previous chest wall reconstruction. The other patients have remained disease-free up to the time of writing. There have been no complications related to the implant material, even following radiotherapy treatment. The plates did not produce radiologic artifacts on either CT or MR imaging (Fig. 2).

As to the evolution of chest wall morphology, 3 patients (patients 2, 3, and 4) developed mild, non-progressive scoliosis that did not need orthosis or surgical treatment. The single patient who underwent hemivertebrectomy (patient 6) developed progressive kyphoscoliosis despite prophylactic spinal fusion (Cobb angle reached 33°) and required further surgical treatment. With regard to function, all patients are able to carry out normal daily activities, including sports and dancing, and all consider that the aesthetic outcome is satisfactory (Fig. 2).

3. Discussion

Achieving adequate surgical margins is one of the main factors that determine disease-free survival in patients with non-metastatic sarcomas [2]. This objective may be particularly difficult to attain in pediatric patients, as their small size impedes application of the margins recommended in adults. It is also difficult to achieve a reconstruction that meets the requisites of functionality, aesthetics, minimal short- and long-term complications, and the potential to reinstate chemotherapy or radiotherapy in the shortest time possible.

In small, limited surgical resections, direct closure is feasible, but the resections performed in thoracic sarcomas usually imply creation of large wall defects. Significant long-term complications have been reported in relation to these surgeries, such as restrictive pulmonary syndrome and severe scoliosis [8]. Over the last decades, several reconstruction methods have been proposed for these patients.

Download English Version:

<https://daneshyari.com/en/article/5718162>

Download Persian Version:

<https://daneshyari.com/article/5718162>

[Daneshyari.com](https://daneshyari.com)