



## Operative Technique

## Ultrasound-guided gastrostomy tube placement: A case series

Joseph T. Church<sup>a</sup>, Karen E. Speck<sup>b</sup>, Marcus D. Jarboe<sup>a,\*</sup><sup>a</sup> Section of Pediatric Surgery, Department of Surgery, University of Michigan Health System, Ann Arbor, MI, USA<sup>b</sup> Department of Pediatric Surgery, Vanderbilt University Medical Center, Nashville, TN, USA

## ARTICLE INFO

## Article history:

Received 7 January 2017

Received in revised form 10 March 2017

Accepted 30 March 2017

## Key words:

Gastrostomy

G-tube

Ultrasound

## ABSTRACT

**Purpose:** Gastrostomy tubes (G-tubes) can be placed utilizing a variety of techniques. Here we present a case series to demonstrate feasibility of a novel method, ultrasound-guided G-tube placement (USGTP).

**Methods:** All cases of USGTP at our institution from September 2015–August 2016 were reviewed. Data included demographics, operative time, complications, time to first feeding, and 30-day readmissions. All steps of the procedure were carried out using ultrasound guidance, resulting in placement of a low-profile G-tube.

**Results:** Twelve patients underwent USGTP. Median age at operation was 2.6 years (IQR 0.9–5.3) and median weight 9.9 kg (IQR 7.2–18.4). Median operative time was 27 min. (IQR 20–44). First feeding occurred  $8.8 \pm 2.9$  h after the procedure. The second patient in the series experienced the only operative complication. In this case, a linear probe was used with insufficient gastric distension, resulting in placement of the tube through a fold in the stomach wall. This was recognized and remedied intraoperatively. This prompted successful technique modification for future USGTPs. Only one patient was readmitted within 30 days, and this was related to urinary retention, an underlying problem.

**Conclusion:** US-guided G-tube placement appears initially to be safe, efficient and effective. Advantages include good anatomical delineation, a single incision, initial placement of a low-profile G-tube, and avoidance of endoscopy, laparoscopy, and radiation. This report illustrates feasibility of USGTP paving the way for further investigation and comparison to other existing gastrostomy insertion methods.

**Level of evidence:** IV.

© 2017 Elsevier Inc. All rights reserved.

Enteral access procedures, in particular gastrostomy tube (G-tube) placement, are some of the most common operations performed by pediatric surgeons [1]. G-tube placement can be performed by a variety of techniques, including open (Stamm) gastrostomy, laparoscopic gastrostomy, percutaneous endoscopic gastrostomy (PEG), and fluoroscopy-guided gastrostomy. These procedures are largely safe and effective, but not perfect, and the choice of procedure depends on both patient characteristics and surgeon decision-making.

Ultrasound-guidance has been reported as an effective means of both placing and replacing gastrostomy tubes percutaneously in adults, but has not been reported in children [2–5]. Ultrasound-guided gastrostomy tube placement (USGTP) therefore represents a novel approach to a common procedure in children. This technique offers the advantages of using single incision, providing good delineation of upper abdominal anatomy, obviating the need for laparotomy, laparoscopy, or endoscopy, and allowing for initial placement of a low-profile or “button” tube. Here we report our experience and outcomes with USGTP in a case series to support the feasibility of this method.

## 1. Methods

## 1.1. Data collection and analysis

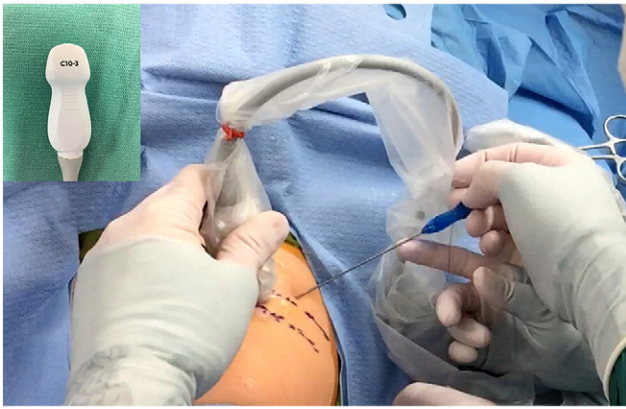
After IRB approval (HUM00117537), all cases of USGTP at our institution from September 2015–August 2016 were retrospectively reviewed. Data collected included demographics, operative time, complications, time to first feeding, and 30-day ER visits and readmissions. Statistics were descriptive.

## 1.2. Procedure

After induction of general anesthesia, a curved ultrasound probe (C10–3 Curved-Phased Array, Zonare, Mountain View, CA) is used to delineate the upper abdominal anatomy (Fig. 1). In particular, the stomach, colon, small bowel, and liver are identified. An orogastric tube is passed and warm saline is instilled to fill the stomach. Gastric distension is observed with ultrasound as saline is infused. If maintaining this distention is difficult, glucagon 0.5–1 mg IV can be administered to delay gastric emptying. A standard site for the G-tube is then chosen, subcostal and at least one finger-breadth from the costal margin. The stomach should abut the anterior abdominal wall at the proposed site

\* Corresponding author at: Section of Pediatric Surgery, University of Michigan, Mott Children's Hospital, 1540 E. Hospital Dr., SPC 4211, Ann Arbor, MI, 48109-4211. Tel.: +1 734 936 8464; fax: +1 734 232 8667.

E-mail address: [marjarbo@med.umich.edu](mailto:marjarbo@med.umich.edu) (M.D. Jarboe).



**Fig. 1.** Upper abdominal ultrasound. A curved ultrasound probe (inset) is used to delineate upper abdominal anatomy, identifying the locations of the stomach, colon, small bowel and liver. T-fasteners, the access needle, wires, and the G-tube are all placed under direct visualization with the ultrasound (T-fastener shown being placed here).

with no intervening structures. This site should be chosen expeditiously, as gastric emptying limits prolonged distention.

With ultrasound guidance, three T-fasteners (Gastrointestinal Anchor Set, Halyard Health, Alpharetta, GA) are placed through the abdominal wall and into the stomach surrounding the planned G-tube site (Fig. 2). Ideally, the T-fasteners triangulate the future G-tube site and are close enough to support the wall of the stomach during dilation and tube placement, but far enough away to avoid interference with the external portion of the G-tube. Each needle is seen entering the gastric lumen, and when the T-fasteners are deployed and traction applied, they can be seen with ultrasound securing the stomach flush to the abdominal wall. The stomach is then accessed with an 18G introducer needle placed between the T-fasteners under US guidance. A 0.035-in. 75-cm Amplatz super stiff wire (Boston Scientific, Marlborough, MA) is advanced through the needle and into the stomach, again under US guidance (Fig. 3). A small skin nick is made at the wire's entry point to accommodate the dilators and G-tube.

The needle is withdrawn, keeping the wire in place, and the tract is serially dilated to 16 or 18 Fr (Applied Medical Technology (AMT), Brecksville, OH). This will accommodate placement of a 14-Fr low-profile tube. The tract length is then sized using a stoma-measuring device (AMT, Brecksville, OH), placed over the wire and into the stomach,

again, with ultrasound guidance (Fig. 4). A 14Fr G-tube of appropriate length is selected. A 7-Fr dilator is placed through the lumen of the tube, and the combination is advanced over the wire and into the stomach under US guidance. The balloon is inflated, and examined with the ultrasound to confirm intraluminal location: the mucosa lies flat against the muscularis (Fig. 5); if the mucosa is seen tented by the balloon, the tube has been placed intramurally.

Once intraluminal placement has been confirmed, the wire and dilator can be removed. The T-fasteners are secured and generally left in place for 5 days. The tube is ready for use, though the protocols at the authors' institutions call for feeds to begin 6 h post-operatively.

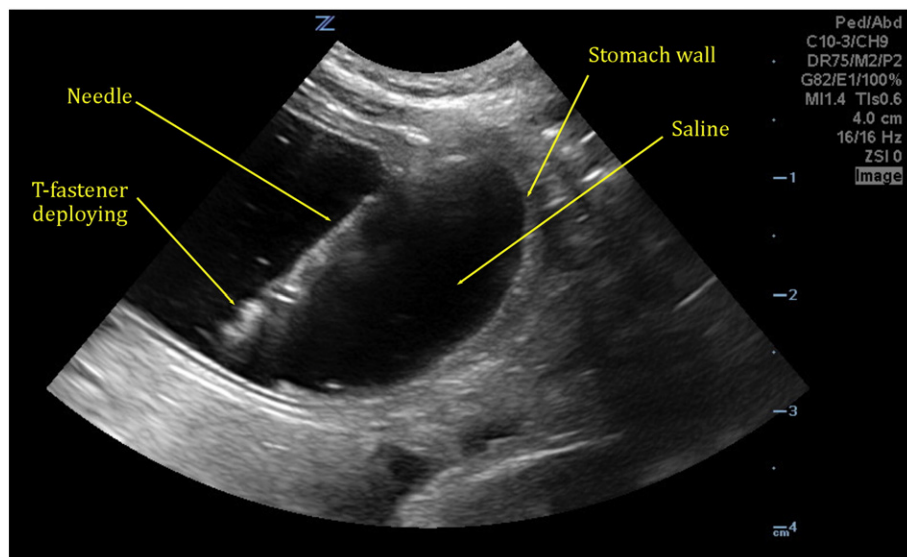
## 2. Results

Twelve patients underwent USGTP. Patient characteristics and outcomes are summarized in Table 1. Indications for enteral access (with number of patients in parentheses) included genetic syndromes (4), cerebral palsy (2), myoclonic epilepsy (2), nutritional support after liver transplant (1), Dandy Walker (1), glycogen storage disease (1), and eosinophilic esophagitis (1). Two patients were tracheostomy-dependent but none were supported by long-term ventilator support.

The second patient in the series experienced the only operative complication. In this case, a linear probe was used with insufficient gastric distension, which resulted in placement of the tube through a fold in the stomach wall, resulting in a second gastrotomy. This was immediately recognized and remedied by conversion to an open Stamm gastrotomy. The patient did well following this procedure. Subsequent G-tube placements were performed with a curved probe. Only one patient was readmitted within 30 days, and this was related to urinary retention, an underlying problem, rather than the G-tube which was working well. One additional patient presented to the emergency room within 30 days with concerns regarding the appearance of the G-tube site, but upon evaluation it was found to be normal and the patient returned home.

## 3. Discussion

Gastrostomy placement is a mainstay of the pediatric surgeon's practice. These tubes can be placed by a number of techniques, including open (Stamm) gastrotomy, laparoscopic gastrotomy, percutaneous endoscopic gastrostomy (PEG), and fluoroscopic gastrostomy.



**Fig. 2.** T-fastener placement. T-fasteners are placed under the guidance of ultrasound. Here the needle, containing the T-fastener, is seen in the lumen of the stomach. The T-fastener can be seen deploying into the lumen of the stomach from the needle tip. The three T-fasteners will anchor the anterior stomach to the anterior abdominal wall.

Download English Version:

<https://daneshyari.com/en/article/5718265>

Download Persian Version:

<https://daneshyari.com/article/5718265>

[Daneshyari.com](https://daneshyari.com)