Journal of Pediatric Urology (2017) 13, 268.e1–268.e6

Scrotal testis size in unilateral non-palpable cryptorchidism, what it can and cannot tell: Study of a Middle Eastern population

P. Shadpour, A.H. Kashi, A. Arvin

Hasheminejad Kidney Center (HKC), Hospital Management Research Center (HMRC), Iran University of Medical Sciences (IUMS), Tehran, Iran

Correspondence to:
P. Shadpour, Hasheminejad Kidney Center (HKC), Vanak Sq., Tehran, 19697, Iran, Tel.: +98 2188644444; fax: +98 2188644447

shadpour.p@iums.ac.ir
(P. Shadpour)

Keywords
Cryptorchidism; Testis; Undescended; Unilateral; Laparoscopy; Orchidopexy

Abbreviations
UDT, undescended testis; NPT, non palpable testis; ROC, receiver operating characteristic curve; AUC, area under curve

Received 7 June 2016
Accepted 13 December 2016
Available online 21 January 2017

Summary

Background
Predicting the fate of a unilateral non-palpable testis based on its scrotal counterpart has been recommended by some, yet disputed by others, and the question remains open.

Objective
To investigate the accuracy of contralateral testis hypertrophy in predicting the absence of a unilateral non-palpable testis in a Middle Eastern population.

Study design
This retrospective study included all patients referred to the present institution with unilateral non-palpable testis between June 2010 and August 2014, who had undergone laparoscopy. The scrotal testis was examined by sonography for size and volume, and diagnostic laparoscopy was utilized to determine the state of the cryptorchid testis.

Results
Of the 135 referred patients, 64 were aged ≤8 years, 29 were 9–18 years, and 42 were >18 years old. Diagnostic laparoscopy revealed 63 intra-abdominal testes, 20 small intra-inguinal testes, 32 vanished testes, and 20 nubbins or aplasia (Summary fig.). Scrotal testis volume was only a modest predictor for absence of the contralateral gonad in adult patients in whom a 22 ml cut-off yielded 64.3% sensitivity and 92.9% specificity. For those aged <18 years, overall accuracy was poor and dropped below 60%. Relative enlargement of contralateral testis in decreasing order of size was observed in patients with primary monorchism, followed by those with secondarily atrophic or nubbin testis, and then those with normal sized inguinal or abdominal testis.

Discussion
Unlike some previous series, which based their conclusions upon open exploration and mostly studied pre-pubertal subjects, the present results exclusively from laparoscopic exploration suggested that contralateral testis volume is a poor and inconsistent predictor of monorchism in children, and marginally predictive for young adults with unilateral non-palpable testis. This study comprised a reasonably large overall sample size compared with preceding reports; however, the number of patients within in each age group was limited. Greater numbers could allow for statistical comparison stratified by age group, for which this study was not powered.

Conclusion
Contralateral testis volume predicts, with modest accuracy, monorchism in adults with unilateral non-palpable testis. In younger patients, the overall predictive accuracy of scrotal testis size is poor and not consistently dependable.

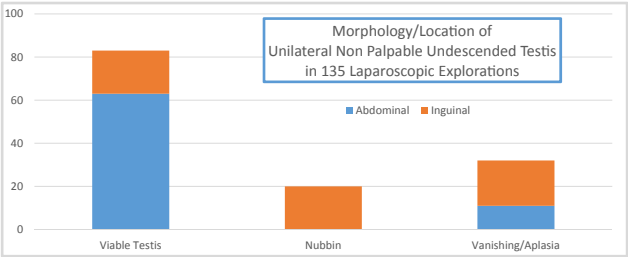

Summary figure Morphology/location of unilateral non-palpable undescended testis in 135 laparoscopic explorations.

http://dx.doi.org/10.1016/j.jpurol.2016.12.013
1477-5131/© 2017 Journal of Pediatric Urology Company. Published by Elsevier Ltd. All rights reserved.

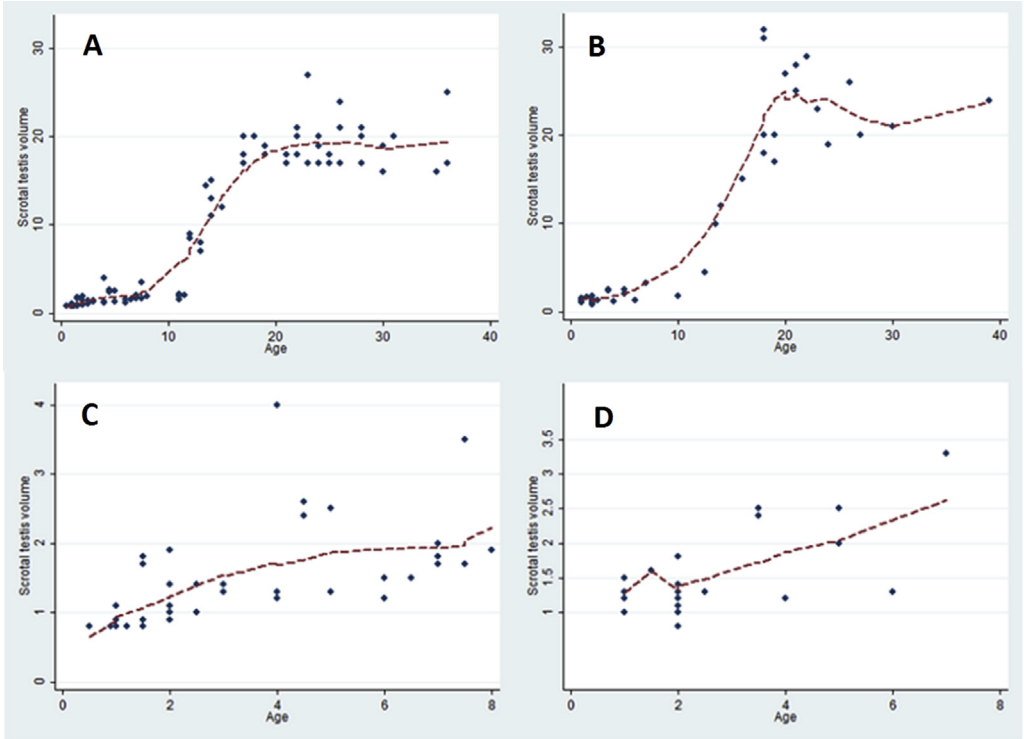

Figure 1 Scatterplot and lowest line fit for age and contralateral testis volume in: A. all patients without monorchism; B. all patients with monorchism; C. patients aged ≤8 years with monorchism; D. patients aged ≤8 years without monorchism.

Introduction

Undescended testis (UDT) afflicts 2—4% of all full-term newborn males [1]. Most of these gonads descend spontaneously by 6 months of age, leaving 1% of boys with the need for intervention [1]. Some 20% of UDT are non-palpable, for which laparoscopy is advocated after the age of 6—12 months [2]. Ultimately this leads to one of four diagnostic possibilities: abdominal testis, extra-abdominal testis, abdominal vanished/nubbin, and extra-abdominal vanished/nubbin [2,3]. Given the low accuracy of imaging for non-palpable testis (NPT) and the more invasive nature of diagnostic surgery, much hope has been invested in utilizing clinical findings to predict the need for surgery, advising patients and parents, and allocating healthcare resources judiciously [2,4,5].

Hypertrophy of the contralateral (i.e. scrotal) testis has been proposed to predict monorchism. Koff et al. showed that contralateral testis hypertrophy occurs between the age of 8 months and 3 years [6], and suggested a volume >2 ml as predictive of monorchism. Other investigators have also suggested the use of predictive value of the contralateral testis size or volume [2,3,5,7—9]. Nevertheless, the matter is by no means settled, as exemplified by Huff et al., who questioned the accuracy of contralateral testis volume for judgment [10]. Furthermore, ethnic difference in testis size has been reported [11], which could preclude both the diagnostic accuracy of testis size for determination of monorchism and using a fixed cut-off for such clinical purpose in other populations. Previous reports have studied European, North American and Japanese boys. The present study reported the results of a study on NPT in a Mediterranean setting, and more importantly, including older children and boys.

Materials and methods

This retrospective study included all patients who underwent laparoscopic evaluation for investigation of unilateral NPT between June 2010 and August 2014. After a detailed history and physical exam, bilateral sonography of the scrotum, inguinal areas and abdomen were obtained, and the size and volume of the descended testis and presumptive presence and location of the NPT were documented. Testis volume was calculated according to the formula proposed by Goede et al. [12] and verified by Sotos et al. [13] using ultrasonography reported dimensions of the descended contralateral testis. Different radiologists performed the ultrasound examination within 1 month preceding the operation.

Patients with bilateral NPT, previous orchidopexy and history of gonadotropin use were excluded from this analysis. Those in whom the gonad became palpable upon

Table 1 Laparoscopic findings regarding morphology and location in 135 unilateral non-palpable testes.

Location	Morphology		
	Viable	Nubbin	Vanishing/aplasia
Abdominal	63	0	11
Inguinal	20	20	21

Download English Version:

https://daneshyari.com/en/article/5718586

Download Persian Version:

https://daneshyari.com/article/5718586

Daneshyari.com