



Neurocognitive Complications of Cystinosis

Doris Trauner, MD

Until effective treatments for the renal complications of nephropathic cystinosis became available, cystinosis was not thought to affect the brain. Any neurologic problems reported in patients with cystinosis were attributed to the chronic renal disease and associated metabolic derangements, or to treatments such as steroids and other immunosuppressant agents. Since the successful advent of renal transplantation, individuals with cystinosis have been living well into adult life. Over the past 20 years, treatment with cysteamine has been widely available and has been shown to effectively clear cystine from cells and allow for maintenance of renal function for many years before renal transplantation is needed. As children have been living longer and healthier lives, other organ involvement (including brain and muscle) have been identified.

There are several potential neurologic complications found in patients with cystinosis (Table). These include cognitive dysfunction, particularly in visual spatial and visual memory domains¹; structural brain differences, particularly changes in white matter volume and integrity²; motor incoordination³; difficulties with academic function⁴; neuromuscular problems; seizures; idiopathic intracranial hypertension (pseudotumor cerebri with increased intracranial pressure); Chiari I malformation⁵; memory impairment; and progressive myopathy.⁶

One of the earliest and most common areas of neurologic dysfunction in cystinosis is that of neurocognitive differences. A specific cognitive profile has been described in individuals with nephropathic cystinosis.^{1,3,7,8} This consists of a background of normal intelligence, language, and visual perceptual functions but difficulty with visual spatial skills, visual memory, visual motor coordination, and attention (Figures 1-3). In addition, many children with cystinosis experience academic difficulties especially in math and spelling, which have been attributed to the deficits in visual spatial/visual memory skills. Visual spatial and memory deficits can be demonstrated with a number of cognitive tasks, but results are remarkably consistent across tasks, across ages, and across treatments.⁷⁻¹⁰

Differences in brain structural development have also been found in children with cystinosis, and many of these changes correlate with performance on visual spatial tasks.^{2,11} Children with cystinosis have evidence of volume loss in the brain, with enlarged ventricles, and reduced volume of both cerebral cortex and cerebral white matter (Figure 4). More specifically, there are delays in the maturation of white matter fiber tracts in areas of the brain associated with visual spatial and visual memory functions. We have found reduced thickness of parietal lobe structures and delayed myelination in the parietal lobes of children with cystinosis compared with age-matched controls.² Furthermore, these structural changes correlate with performance on visual spatial tasks (Figure 5), indicating a relationship between brain structure and function in this condition. These findings are present in young children with cystinosis who have been treated early with cysteamine, suggesting that the cognitive and structural differences are not merely due to cystine accumulation in the brain but perhaps to an early effect of the genetic mutation on brain development.

The most compelling evidence for a direct effect of the cystinosis gene on brain function is based on studies of carriers of the gene, who do not exhibit any symptoms of cystinosis. Heterozygous carriers have normal renal function and never develop renal or other systemic manifestations of the disease. However, otherwise asymptomatic carriers of the gene demonstrate the same cognitive deficits as do homozygous individuals with cystinosis.¹² Asymptomatic parents of children with cystinosis are obligate heterozygotes. These parents demonstrate similar difficulties with visual spatial, visual memory, and visual motor tasks as do their homozygous children (Figures 6 and 7). Thus, it is unlikely that the neurocognitive deficits are secondary to the renal disease or treatments. Further, there is evidence that brain structure is altered in cystinosis, even in young children, supporting the idea that the brain develops differently in the face of the genetic mutation.

Treatment with cysteamine has been shown to have a striking effect on renal function. When children are treated from a young age, renal function can be preserved into the third decade of life. Some other manifestations of cystinosis, such as thyroid dysfunction, may also be delayed or prevented with cysteamine therapy. In the case of the brain, however, there are indications that the neurocognitive changes are present from early life and may not be affected to any notable extent by early treatment. For example, visual motor coordination is no better in children treated before 2 years of age from that of children treated later in childhood.¹³ Also, unlike other organs, it appears that the brain of the child with cystinosis develops differently from that of children without cystinosis. Specific structural and functional differences suggest an early influence of the gene on brain development. These cannot be explained merely by renal dysfunction, cystine accumulation, or medical treatments because similar changes are present in asymptomatic carriers of the cystinosis gene. Even very early treatment

From the Departments of Neurosciences and Pediatrics, University of California, San Diego School of Medicine, La Jolla CA

Please see the author disclosures at the end of the article.

0022-3476/\$ - see front matter. © 2016 Elsevier Inc. All rights reserved.

<http://dx.doi.org/10.1016/j.jpeds.2016.12.054>

Table. Neurologic complications of nephropathic cystinosis	
Cognitive	Visual spatial, visual memory, visual motor problems
Structural brain differences	Cortical and central volume loss, reduction in white matter integrity in parietal lobes
Motor incoordination	Gross and fine motor
Swallowing dysfunction	Early and late
Academic function	Particularly with arithmetic and spelling
Neuromuscular function	Hypotonia, weakness
Seizures	
Increased intracranial pressure	Pseudotumor cerebri
Chiari I malformation	
Memory impairment	Manifesting in adults
Progressive myopathy	Manifesting in adults

is, thus, not likely to alter the fundamental neural changes. However, recognition of these problems, when they occur, can lead to interventions that may reduce the academic and emotional consequences of the early neurocognitive differences.

What can we learn from examining the extrarenal complications of cystinosis? Is there a common thread in basic physiology? Cystinosis is a lysosomal storage disease, and lysosomal dysfunction is one candidate for a common thread. However, there is increasing evidence of mitochondrial dysfunction in cystinosis as well. Mitochondrial dysfunction could also explain all of the multisystem abnormalities present in cystinosis. Much more work needs to be done to elucidate all of the mechanisms by which cystinosis affects the brain as well as all other organs, but the study of affected as well as nonaffected tissues may be the most likely means of understanding the underlying pathophysiology of the disorder. ■

INTELLIGENCE AND VISUAL PERCEPTION

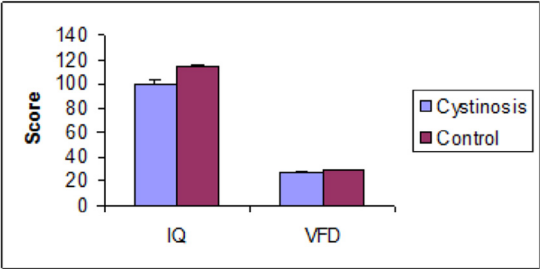


Figure 1. School-age children with cystinosis scored significantly lower than their matched controls on a standardized test of intelligence, although still within the average range (SS = 100). They did not perform differently from controls on Visual Form Discrimination (VFD), a test of visual perception. Adapted from Ballantyne and Trauner.⁷

VISUAL/VERBAL ASYMMETRY

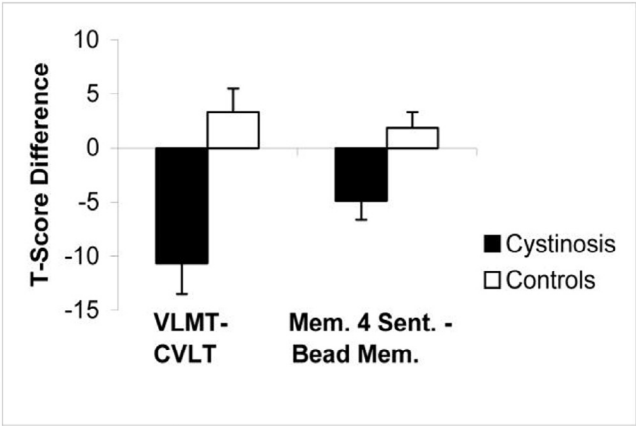


Figure 2. Visual and verbal learning and memory were studied in 37 cystinosis subjects and 37 age-matched controls. The California Verbal Learning Test (CVLT) was used to assess verbal learning. The Visual Learning and Memory Test (VLMT) is a test somewhat analogous to the CVLT but in the visual domain, and was used to examine visual learning. Two subtests from the Stanford Binet Intelligence Scales, Fourth Edition, were used to test verbal and visual memory (Memory for Sentences [Mem. 4 Sent] and Bead Memory [Bead Mem]), respectively. T-scores were calculated for visual (VLMT) and verbal (CVLT) learning and Visual (Bead Mem) and verbal (Mem. 4 Sent.) memory tasks, and the difference between visual and verbal scores was calculated. If there was no difference between modalities, the T score differences would approach zero. However, for both learning and memory tasks, cystinosis subjects performed significantly more poorly on visual than verbal tasks, such that the difference scores were large. Children with cystinosis scored at a comparable level to age-matched controls on a verbal learning task (CVLT), but much more poorly than controls on a visual learning task (VLMT; difference scores were significant at $P = .003$). Children with cystinosis scored significantly more poorly than controls on a visual memory task (Bead Memory [Bead Mem]) but not on a verbal memory task (Memory for Sentences [Mem. 4 Sent.]; difference scores were significant at $P = .004$). Reprinted with permission from Spilkin et al.⁸

Download English Version:

<https://daneshyari.com/en/article/5719256>

Download Persian Version:

<https://daneshyari.com/article/5719256>

[Daneshyari.com](https://daneshyari.com)