



## African Journal of Urology

Official journal of the Pan African Urological Surgeons' Association  
web page of the journal

[www.ees.elsevier.com/afju](http://www.ees.elsevier.com/afju)  
[www.sciencedirect.com](http://www.sciencedirect.com)



### Case report

# Facial nerve palsy as a primary presentation of advanced carcinoma of the prostate: An unusual occurrence



A. Abdulkadir<sup>a,\*</sup>, M. Ahmed<sup>b</sup>, U.M. Tela<sup>c</sup>, A. Ismail<sup>d</sup>,  
B.M. Abubakar<sup>e</sup>

<sup>a</sup> Urology Unit, Department of Surgery, Bayero University/Aminu Kano Teaching Hospital, Kano, Nigeria

<sup>b</sup> Division of Urology, Department of Surgery, Ahmadu Bello University/Ahmadu Bello University Teaching Hospital, Zaria, Nigeria

<sup>c</sup> Department of Surgery, University of Maiduguri Teaching Hospital, Maiduguri, Nigeria

<sup>d</sup> Department of Radiology, Bayero University/Aminu Kano Teaching Hospital, Kano, Nigeria

<sup>e</sup> Department of Surgery, Federal Medical Centre, Nguru, Yobe State, Nigeria

Received 22 April 2015; received in revised form 4 October 2015; accepted 6 October 2015

Available online 2 July 2016

#### KEYWORDS

Advanced prostate carcinoma;  
Facial nerve palsy;  
Orchidectomy;  
Palliative treatment;  
Physiotherapy

#### Abstract

**Introduction:** Cranial nerve neuropathy is a rare presentation of advanced cancer of the prostate.

**Observation:** We report a case of 65-year-old man who presented with right lower motor neuron (LMN) facial nerve palsy. The prostate had malignant features on digital rectal examination (DRE) and the prostate specific antigen (PSA) was 116 ng/ml. Histology of the prostate biopsy confirmed an adenocarcinoma with the Gleason score of (4 + 3) = 7/10. The computerised tomography (CT) scan of the skull revealed dense osteosclerosis at the base, worse in the petrous part of the right temporal bone with narrowed ipsilateral facial nerve canal. Androgen deprivation therapy (ADT) was achieved by bilateral orchidectomy. Analgesics and bisphosphonates with facial muscles physiotherapy were also administered. He had significant resolution of the facial nerve palsy and the other symptoms at subsequent follow-ups. The related literatures were reviewed.

**Conclusion:** Facial nerve palsy as a primary presentation of advanced cancer of the prostate is unusual, thus, a high index of suspicion is required to establish the diagnosis. ADT provided adequate palliation.

© 2016 Pan African Urological Surgeons' Association. Production and hosting by Elsevier B.V. All rights reserved.

\* Corresponding author. Tel.: +234 8036781418.

E-mail address: [aabdulkadir21@gmail.com](mailto:aabdulkadir21@gmail.com) (A. Abdulkadir).

Peer review under responsibility of Pan African Urological Surgeons' Association.

<http://dx.doi.org/10.1016/j.afju.2015.10.004>

1110-5704/© 2016 Pan African Urological Surgeons' Association. Production and hosting by Elsevier B.V. All rights reserved.

## Introduction

Cranial nerves may be invaded by malignant tumour from Cranio-oropharyngeal region or rarely the metastasis from distal sites such as the breast, lung, prostate and kidney following the haematogenous spread to the base of the skull [1]. The few reported cases of cranial nerve palsies from metastatic prostate cancer were however in patients whose disease progressed while on palliative treatment. These resulted in recognised syndromic cranial nerve lesions such as Villaret's syndrome [2], Occipital condyle syndrome [3], Jugular foramen syndrome [4], Parasellar syndrome [5], Collet syndrome [6] or isolated II [7], III, VI and VIII nerves palsy [8,9]. Isolated facial nerve palsy is unusual as the first presentation of the patient with advanced carcinoma of the prostate.

We obtained a written consent from the patient, and clearance from the Hospital Ethics Committee to report this unusual presentation of an advanced prostate cancer.

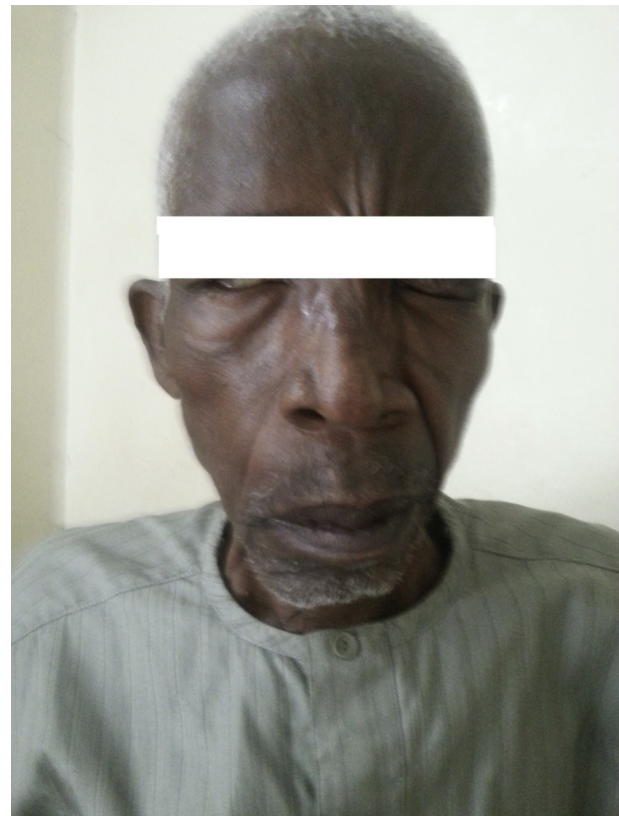## Case report

A 65-year-old man, retired journalist, who presented with three weeks history of deviation of his mouth towards the left side and difficulty with feeding due to the escape of feeds from the contra lateral angle of his mouth. He could not close the right eye even while asleep. On further evaluation, he was found to have mild irritative lower urinary tract symptoms (LUTS), low back pain that was not bothersome and generalised body weakness. He was not hypertensive or diabetic and had no other co-morbidity.

On physical examination, he was pale, had lost the naso-labial fold on the right side of the face while his mouth was deviated to the left. His right eye remained opened on his attempt to clench his teeth and close his eyes (Fig. 1). He had no swelling in the periauricular region and his ear, nose and throat (ENT) examinations were normal. The rectal examination revealed an enlarged prostate with malignant features; clinical stage T2C. His Pack Cell Volume was 25% and hence, he was transfused two units of whole blood. The PSA was 116 ng/ml and the six cores of the digital guided prostate biopsy taken all confirmed adenocarcinoma of the prostate that had the Gleason score of 7/10(4+3) (Fig. 2). His lumbosacral radiographs revealed osteoblastic bone lesions involving the lumbosacral and pelvic bones. The skull CT showed dense sclerosis at the base which was worse in the petrous part of the right temporal bone with narrowed ipsilateral facial nerve canal (Figs. 3 and 4) but the cerebral and cerebellar hemispheres were normal. He was counselled for palliative treatment. Androgen deprivation therapy was achieved by bilateral orchidectomy. Other adjuvant treatments he had were; facial muscles physiotherapy, analgesics and oral bisphosphonates. He had significant resolution of symptoms at subsequent follow ups; he had regained good facial symmetry with the reappearance of the nasolabial fold on the right side and he could close both eyes (Fig. 5).

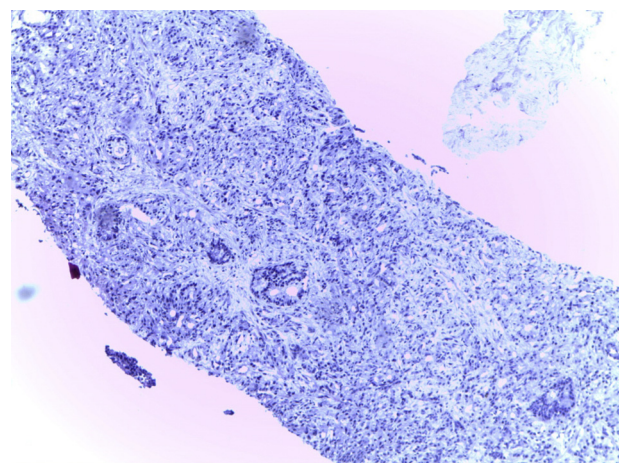
## Discussion

Prostate cancer is the second commonest malignancy in men worldwide [10]; however, it accounts for only 6% of the metastasis from all cancers to the skull [11]. The exact mechanisms of its haematogenous spread to the skull is still poorly understood [12]. Only a few cases of facial nerve palsy following metastasis from prostate cancer to the base of the skull in patients with castration resistant



**Figure 1** Right eye remained open on attempt at closing the eyes and clenching the teeth seen in right LMN facial nerve palsy.

prostate cancer (CRPC) have been reported in the literature. We could not find any report of facial nerve palsy as the first sole presentation of cancer of the prostate prior to ADT or before the development of CRPC. Our patient presented primarily with facial nerve palsy, which posed a significant diagnostic challenge. Because of the impact of facial nerve palsy on the patient's body image and quality of life [13], it was expedient to establish the cause. Metastasis to the temporal bone typically presents with the classical triad of otalgia, periauricular swelling and facial nerve palsy [14] but this patient had only facial nerve palsy.



**Figure 2** Histology of the patient's prostate biopsy specimen. Haematoxylin and Eosin Stain (40×). Gleason score (4+3) = 7/10.

Download English Version:

<https://daneshyari.com/en/article/5729477>

Download Persian Version:

<https://daneshyari.com/article/5729477>

[Daneshyari.com](https://daneshyari.com)