



African Journal of Urology

Official journal of the Pan African Urological Surgeon's Association
web page of the journal

www.ees.elsevier.com/afju
www.sciencedirect.com



Reconstructive Urology

Original article

Functional and cosmetic outcome of partial penile disassembly repair in isolated male epispadias patients



A. Bhat*, M. Bhat, R. Kumar, V. Kumar

Department of Urology, Preventive and Social Medicine, S.P. Medical College, Bikaner 334003, India

Received 14 July 2015; received in revised form 27 September 2015; accepted 30 September 2015

Available online 4 July 2017

KEYWORDS

Congenital anomalies;
Epispadias repair;
Single stage repair;
Partial penile disassembly;
Urethroplasty;
Complication of epispadias repair;
Continence;
Functional and cosmetic outcome

Abstract

Introduction: Epispadias is a rare congenital anomaly and requires a carefully constructed and well-planned approach for the management. Modified Cantwell-Ransley technique and Mitchell's complete penile disassembly are commonly used technique and these may require multiple surgeries in majority of the patients to achieve the goals of cosmesis and continence.

Objective: To evaluate the functional and cosmetic outcome of single stage partial penile disassembly repair in isolated male epispadias.

Patients and methods: A retrospective analysis of 43 cases of primary epispadias repair, performed during July 1998 to March 2013. Patients were classified on the basis of type of epispadias, urinary incontinence, presence/degree of chordee and penile rotation.

Technique: Penile de-gloving with mobilization of urethral plate from ventral to dorsal aspect with preservation of blood supply at both ends, distally up to the level of mid-glans and proximally up to pubic symphysis with division of peno-pubic ligament to lengthen the penis and position the urethra ventrally. Tubularization of urethral plate followed by spongioplasty, corporoplasty with medial rotation of corporeal bodies (without any corporotomy) and glanuloplasty with meatoplasty is done to bring the meatus ventrally. Skin cover with rotation of ventral flaps and z-plasty when required.

Results: Age of the patients varied from 6 months to 26 years with a mean of 9 years. Ninety three percent of the patients had excellent cosmetic outcome while seven percent had minimal residual chordee/torque but did not require any surgery. None of the patients developed complications like fistula or stricture. All the 12 patients in the postpubertal group reported normal erections and successful ejaculations after the surgery. Postoperative follow up ranged from 2 to 10 years with a mean of 4 years.

* Corresponding author at: C-15 Sadul Ganj, Bikaner, Rajasthan 334003, India.

E-mail addresses: amilalbhat@rediffmail.com (A. Bhat), mahak199027@gmail.com (M. Bhat), drrajeekr2k@gmail.com (R. Kumar), vinaysinghkgmc99@gmail.com (V. Kumar).

Peer review under responsibility of Pan African Urological Surgeons' Association.

<http://dx.doi.org/10.1016/j.afju.2015.09.010>

1110-5704/© 2017 Pan African Urological Surgeons Association. Production and hosting by Elsevier B.V. This is an open access article under the CC BY-NC-ND license (<http://creativecommons.org/licenses/by-nc-nd/4.0/>).

Conclusions: The technique incorporates all the benefits of Cantwell-Ransley repair, can be done with less extensive dissection than total penile disassembly. Both functional and cosmetic results are good with low complication rate. Spongioplasty reconstructs near normal urethra and corporoplasty with spongioplasty also helps in prevention of urethral fistula.

© 2017 Pan African Urological Surgeons Association. Production and hosting by Elsevier B.V. This is an open access article under the CC BY-NC-ND license (<http://creativecommons.org/licenses/by-nc-nd/4.0/>).

Introduction

Epispadias is a rare congenital anomaly which occurs in 1 in 117,000 and male's most common variety being peno-pubic epispadias (70%) [1,2]. These patients may suffer from urinary incontinence especially the peno-pubic variant. A carefully constructed and well-planned approach is the pre-requisite to the management of these patients. Currently, there are two popular surgical techniques described well in the literature are; modified Cantwell-Ransley technique, which involves partial disassembly of the penis and placement of the urethra in a ventral position and Mitchell's complete penile disassembly. The drawbacks of Modified Cantwell-Ransley technique are persistence of short penile length and residual dorsal chordee along with a need for second procedure to achieve continence [3,4]. The major disadvantages of the Mitchell technique are the aggressive dissection which endangers the blood supply to urethra and resultant hypospadias meatus which may require a second surgery in significant proportion of cases [5]. Both the techniques require multiple surgeries in majority of the patients to achieve the goals of cosmesis and continence. Purpose of the study was to evaluate the functional and cosmetic outcome of single stage partial penile disassembly repair in isolated male epispadias patients.

Patients and methods

A retrospective analysis of surgical outcome of 50 cases of primary epispadias repair operated during July 1998 to March 2013 was performed. All patients of primary epispadias who were continent or partially incontinent were included in the study. Primary epispadias with total incontinence (7 cases) who underwent partial penile with double breasting of bladder neck were published earlier so excluded from the study [6]. The exclusion criteria were: (1) those who underwent partial penile disassembly with double breasting of the bladder neck; (2) those with epispadias associated with bladder exstrophy; and (3) re-operative cases.

Surgical technique

Circum-coronal incision with U shape extension encircling the urethral plate and meatus after local infiltration of adrenaline (1:100,000) (Fig. 1A–C). Penile de-gloving is done up to root of the penis. Mobilization of urethral plate from ventral to dorsal aspect (Fig. 1D and E), proximally right up to pubic symphysis exposing the bladder neck with division of peno-pubic ligament and distally up to the level of mid-glans helps in penile lengthening. Blood supply to urethral plate is to be preserved at both ends and it is dissected off from both the corpora one after other (Fig. 1F and G) to disassemble the penis into three separate compartments with mobilization of the

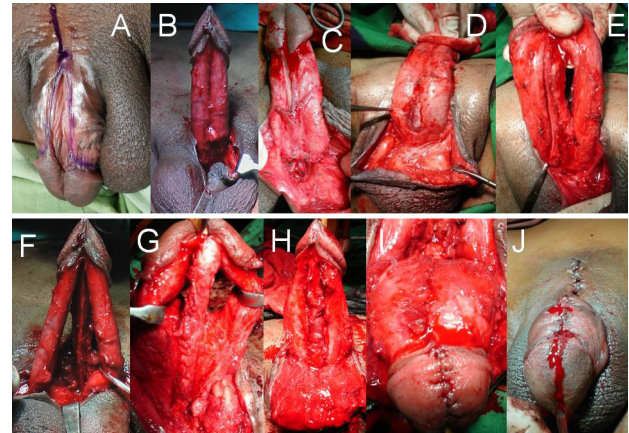


Fig. 1 (A) Peno-pubic epispadias. (B, C) Incision around the epispadiac meatus, coronal Sulcus and urethral plate and Penile de-gloving. (D, E) Urethral plate mobilization. (F, G) Urethral plate dissected off corpora and penis disassembled into 3 separate compartments (2 corpora & urethral plate with spongiosum). (H) Tubularization of urethral plate Spongioplasty ventral fixation of urethra. (I) Corporoplasty and glanuloplasty. (J) Skin closure and final appearance straight penis.

both the corpora and urethral plate with spongiosum leaving only the distal most attachment at glans intact. Corporal bodies are mobilized partially from the pubic rami to lengthen the penis. Tubularization of urethral plate is done after placing a feeding tube (suitable size for age) starting proximally from the bladder neck. Spongioplasty (Vicryl 6–0) is done subsequently (Fig. 1H). Corporal bodies are rotated medially with transposition of neurovascular bundle dorsally, no corporotomy incision is given, but a corporoplasty along the entire length with Vicryl 4 to 6–0 is performed keeping the urethra ventrally. Urethra is fixed with the corpora at its newly created, normal anatomical ventral location. Glanuloplasty and meatoplasty is done to create a conical glans with normal ventral location of meatus having adequate calibre (Fig. 1I). Penile skin is covered by rotation of ventral flaps (Fig. 1J). Mobilization of urethral plate and urethra is done up to bulbar region even in penile epispadias to bring the urethra ventrally and corporal bodies are mobilized to gain the length as well as correction of rotational deformity (Fig. 2). Z plasty is added when required for skin closure and to create adequate peno-pubic angle.

Prepuceplasty was done in all suitable cases when adequate prepuce was available to restore the normal morphology. Gentle pressure dressing was to be applied and check dress was usually done on 5th postoperative day. Third generation cephalosporins and anti-

Download English Version:

<https://daneshyari.com/en/article/5729533>

Download Persian Version:

<https://daneshyari.com/article/5729533>

[Daneshyari.com](https://daneshyari.com)