



Usefulness of cervical computed tomography and magnetic resonance imaging for rapid diagnosis of crowned dens syndrome: A case report and review of the literature

Akihiro Inoue^{a,*}, Kanehisa Kohno^a, Satoko Ninomiya^b, Hitomi Tomita^b, Shinji Iwata^a, Shiro Ohue^a, Kenji Kamogawa^b, Kensho Okamoto^b, Shinya Fukumoto^a, Haruhisa Ichikawa^a, Shinji Onoue^a, Saya Ozaki^a, Bungo Okuda^b

^a Departments of Neurosurgery, Ehime Prefectural Central Hospital, Japan

^b Departments of Neurology, Ehime Prefectural Central Hospital, Japan

ARTICLE INFO

Article history:

Received 25 August 2016

Accepted 21 November 2016

Available online 23 November 2016

Keywords:

Crowned dens syndrome

Crystalline deposition disease

Nonsteroidal anti

Inflammatory drugs

Meningitis

MRI findings

ABSTRACT

INTRODUCTION: Crowned dens syndrome is a rare disease entity which radiologically shows calcification of the cruciform ligament around the odontoid process. We report a patient with crowned dens syndrome who improved dramatically in 5 days following treatment with oral nonsteroidal anti-inflammatory medication.

PRESENTATION OF CASE: A 61-year-old man was admitted to our hospital with a severe occipital headache and sudden onset of neck stiffness. Neurological examination on admission revealed a high fever and cervical rigidity. Laboratory examination revealed a markedly elevated white blood cell count and C-reactive protein level, but cerebrospinal fluid studies revealed only a slight abnormality. A cervical computed tomography scan and its three-dimensional reconstruction detected a remarkable crown-like calcification surrounding the odontoid process. Cervical magnetic resonance imaging did not demonstrate strong direct compression of the cervical cord; however, the soft tissue surrounding the odontoid process was hyperintense on T2-weighted imaging with fat suppression. Based on the radiological findings, the patient was diagnosed with crowned dens syndrome and was immediately treated with non-steroidal anti-inflammatory drugs. The patient's condition drastically improved within 5 days.

DISCUSSION: It was very interesting that the soft tissue surrounding the odontoid process was hyperintense on magnetic resonance T2-weighted imaging with fat suppression, and the signal change disappeared 2 weeks after the administration of oral non-steroidal anti-inflammatory drugs. We think that magnetic resonance imaging is useful for proving inflammation in patients with crowned dens syndrome.

CONCLUSION: This is the first report making reference to the magnetic resonance imaging findings of crowned dens syndrome.

© 2016 The Author(s). Published by Elsevier Ltd on behalf of IJS Publishing Group Ltd. This is an open access article under the CC BY-NC-ND license (<http://creativecommons.org/licenses/by-nc-nd/4.0/>).

1. Introduction

Crowned dens syndrome (CDS) is a radioclinical entity defined by the association of microcrystalline deposition of calcium pyrophosphate dehydrate (CPPD) in the cruciform ligament around

Abbreviations: CDS, crowned dens syndrome; CPPD, calcium pyrophosphate dehydrate; CRP, creatinine protein; ANCA, anti-neutrophil cytoplasmic antibody; MRI, magnetic resonance imaging; Gd, gadolinium; CT, computed tomography; 3D, three-dimensional; NSAIDs, non-steroidal anti-inflammatory drugs; FLAIR, fluid attenuated inversion recovery.

* Corresponding author at: Departments of Neurosurgery, Ehime Prefectural Central Hospital, 83 Kasugamachi, Matsuyama, Ehime Prefecture 790-0024, Japan.

E-mail address: iakihiro3@gmail.com (A. Inoue).

<http://dx.doi.org/10.1016/j.ijscr.2016.11.045>

2210-2612/© 2016 The Author(s). Published by Elsevier Ltd on behalf of IJS Publishing Group Ltd. This is an open access article under the CC BY-NC-ND license (<http://creativecommons.org/licenses/by-nc-nd/4.0/>).

the odontoid process and is demonstrated radiologically as a radiopaque density in a crown or halo-like distribution that appears at the superior and lateral portions of the odontoid process [1–4]. The deposits of CPPD can remain asymptomatic or can be responsible for chronic cervical illness or spinal cord compression and lead to periodic acute cervico-occipital pain with fever, neck stiffness, and biological inflammatory syndrome [1,5]. Here, we report a patient with CDS who dramatically improved in 5 days following treatment with oral nonsteroidal anti-inflammatory medication.

2. Case description

A 61-year-old man with a history of subarachnoid hemorrhage was admitted to our hospital because of a sudden onset of high

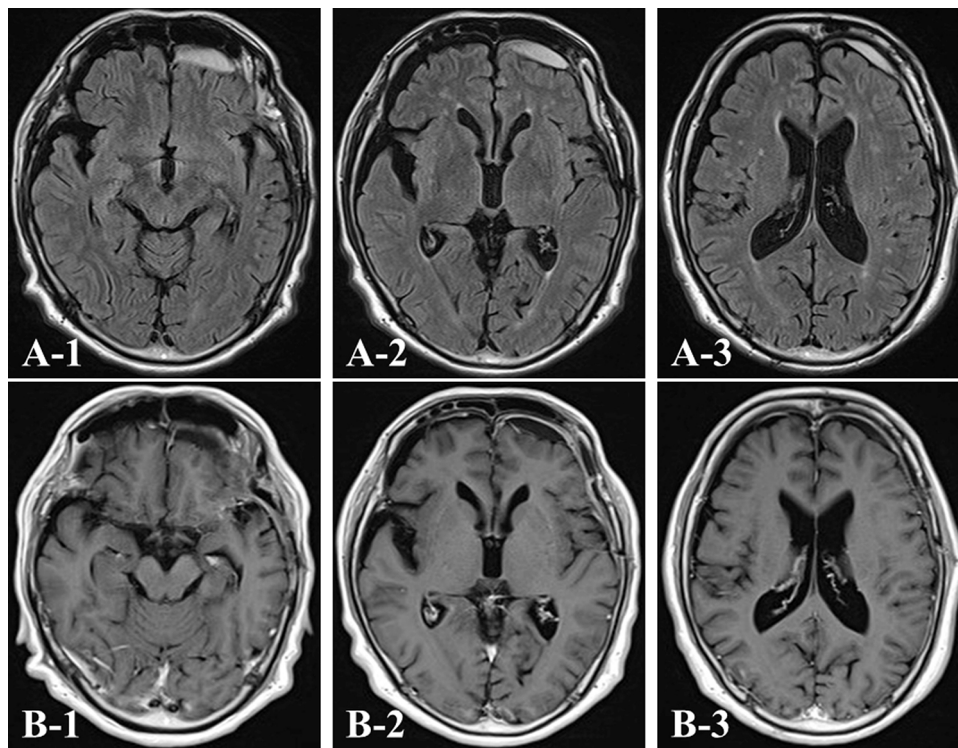


Fig. 1. Magnetic resonance imaging (MRI) findings. Axial fluid-attenuated inversion recovery (FLAIR) (A) and gadolinium (Gd)-enhanced T1-weighted (B) MR images showing slight retention of the subdural hematoma. The hematoma is not enhanced on the administration of Gd.

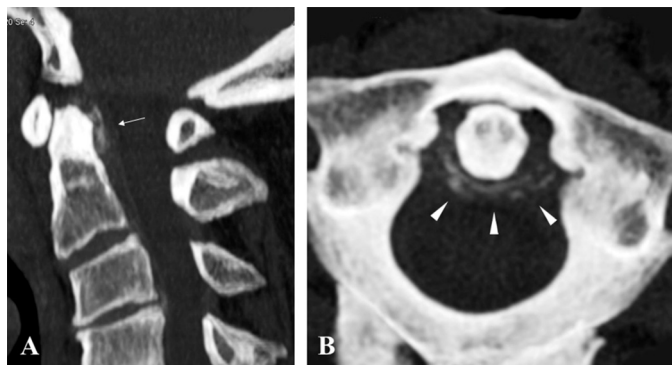

Fig. 2. Cervical computed tomography (CT) scans around the odontoid process. Sagittal reconstruction showing the linear calcification at the posterior side of the dens suggesting calcium pyrophosphate dehydrate (CPPD) (white arrow) (A). The axial image demonstrates the right-dominant, half-ringed form of calcification at the posterolateral side of the dens (white arrowhead) (B).

fever, severe occipital headache, and neck stiffness. At admission, his body temperature was 39.3 °C. He did not show any neurological deficits, including Kernig's sign. Laboratory examination revealed a markedly elevated white blood cell count (12270/ μ L) and C-reactive protein (CRP) level (23.29 mg/dL). His serum uric acid level (5.2 mg/dL) was not elevated. Blood testing for connective tissue disease or vasculitis, including rheumatoid factor, cytoplasmic anti-neutrophil cytoplasmic antibody (ANCA), perinuclear ANCA, and anti-nuclear and anti-cyclic citrullinated peptide antibodies, were all negative. These findings suggested severe infection such as sepsis and/or meningitis. However, blood cultures were negative, and his serum procalcitonin was not elevated. Routine cerebrospinal fluid studies revealed a slight abnormality (white blood cell 1/ μ L and protein 47 mg/dL), whereas cerebrospinal fluid culture and anti-herpes simplex virus and varicella-zoster virus antibodies were all negative. Intracranial magnetic resonance imaging (MRI)

demonstrated almost normal findings, except for slight retention of the subdural hematoma without gadolinium (Gd) enhancement (Fig. 1). However, a plain cervical computed tomography (CT) scan and three-dimensional (3D)-reconstruction imaging detected a remarkable crown-like calcification surrounding the odontoid process (Fig. 2). In addition, cervical MRI did not demonstrate strong direct compression of the cervical cord; however, the soft tissue surrounding the odontoid process was hyperintense on T2-weighted imaging with fat suppression without Gd enhancement (Fig. 3). Based on these radiographic findings, the patient was diagnosed with a severe case of CDS. Although clinically asymptomatic without a previous history of arthritis, the patient's X-ray and CT of the knee joints revealed calcium deposits, suggesting underlying crystalline deposition disease (Fig. 4). Non-steroidal anti-inflammatory drugs (NSAIDs) were immediately started and tapered off within 3 weeks. The patient's symptoms drastically improved within 5 days after initiating NSAID treatment, and the blood results consistent with a serum inflammatory reaction decreased to within normal range 14 days later. The T2 hyperintense lesion on MRI disappeared within 2 weeks (Fig. 5), which helped us exclude infectious meningitis and sepsis from the differential diagnosis. The symptoms improved completely, and the patient was discharged 15 days after admission.

3. Discussion

CDS is a rare disease entity which radiologically shows calcification of the cruciform ligament around the odontoid process and clinically presents with acute cervico-occipital pain, fever, and neck stiffness accompanied by a biological inflammatory reaction [1–5]. The diagnosis of CDS is based on the combination of clinical, biological, radiological, and therapeutic findings: acute periodic attacks of feverish cervico-occipital pain and neck stiffness with biological inflammatory syndrome, radiological identification of a crown-like calcification surrounding the odontoid process due to microcrys-

Download English Version:

<https://daneshyari.com/en/article/5732574>

Download Persian Version:

<https://daneshyari.com/article/5732574>

[Daneshyari.com](https://daneshyari.com)