



Contents lists available at ScienceDirect

International Journal of Surgery Case Reports

journal homepage: www.casereports.com

Peri-prosthetic humeral non-union: Where biology meets bio-mechanic. A case report



Ciurlia Emanuele*, Puddu Leonardo, Caggiari Gianfilippo, Andreozzi Matteo, Carlo Doria

Orthopaedic Department – Medical School of Sassari, Viale San Pietro 47, 07100 Sassari, Italy

ARTICLE INFO

Article history:

Received 26 April 2017

Received in revised form 1 August 2017

Accepted 1 August 2017

Available online 5 August 2017

Keywords:

Non-union

Bone-healing

Peri-prosthetic fracture

ABSTRACT

INTRODUCTION: The worldwide incidence of traumatic fractures has been growing over the last years due to the progressive aging of the population. Today, the increase of arthroplasty procedures in orthopaedic surgery is related to a high rate of peri-prosthetic fractures. Healing of the fracture is a multifactorial metabolic process; if these factors are impaired, healing process could be interrupted resulting in non-union.

PRESENTATION OF CASE: We report our experience about a case of a humeral diaphysis non-union secondary to peri-prosthetic fracture (reverse shoulder arthroplasty) treated by conservative approach.

DISCUSSION: We treated this patient using a multilevel approach, consisting of revision surgery and drug therapy.

CONCLUSION: We assume that an aggressive revision surgery done with bone autograft implant and a bone healing therapy administering teriparatide off-label can reduce the convalescence in non-unions and can improve prognosis.

© 2017 Published by Elsevier Ltd on behalf of IJS Publishing Group Ltd. This is an open access article under the CC BY-NC-ND license (<http://creativecommons.org/licenses/by-nc-nd/4.0/>).

1. Introduction

The progressive increase of shoulder arthroplasty implants is correlated to a major incidence of peri-prosthetic fractures. The frequency of these traumatic events on shoulder is 0.6–3% and 40% of these cases are represented by low-energy post-operative fractures [1]. Treatment varies from conservative to implant revision and depends on the type of fracture and the stability of prosthesis [2,3]. If not completely treated, peri-prosthetic fractures may lead to non-union.

2. Presentation of case

We report a case of a 64-years-old woman with a complete right upper limb dysfunction (DASH 32) [8] due to non-union (type B2 according to Worland classification) [4] occurred on a peri-prosthetic fracture at the distal end of the humeral stem of RSA (reverse shoulder arthroplasty), positioned 3 years before.

Immobilization with an arm brace was used as first conservative treatment.

The following x-ray evaluations showed a progression from fracture to non-union and a varus angle deformity (Fig. 1).

* Corresponding author.

E-mail addresses: ciurlia81@gmail.com (C. Emanuele), lpuddu86@gmail.com (P. Leonardo), gianfilippocaggiari@gmail.com (C. Gianfilippo), matteo.andreozzi88@gmail.com (A. Matteo), cdoria@uniss.it (C. Doria).

<http://dx.doi.org/10.1016/j.ijscr.2017.08.001>

2210-2612/© 2017 Published by Elsevier Ltd on behalf of IJS Publishing Group Ltd. This is an open access article under the CC BY-NC-ND license (<http://creativecommons.org/licenses/by-nc-nd/4.0/>).

In order to definitively correct such deformity we chose surgical treatment. We removed fibrous tissue around the locus, reduced the fracture and performed osteo-synthesis with plate, screws and wires in addition to a massive bone autograft. At first a 15 cm autologous bone from peroneal diaphysis and a 8 cm piece of cortical bone from iliac crest were harvested. Then the fracture line was exposed and the surface was regularized, scratched and freshened (Fig. 2). Finally, we corrected the skeletal deformity and defect performing an osteo-synthesis of the fracture line using the autologous bone and a straight plate that was fixed distally with 3 screws, proximally with 4 screws and with 3 looping wires [5,6] (Fig. 3).

Postoperatively, the patient followed a therapy with Teriparatide (20 µg/die for 3 months) [7,8]. X-ray control was performed at 3 months. Teriparatide is the foreshortened amino terminal peptide of PTH and has a osteoanabolic effect when administered once daily in low doses for the treatment of osteoporosis. There is evidence that Teriparatide also accelerates the fracture healing process by improving the biomechanical properties of the fracture callus, increasing endochondral ossification and bone remodelling in animal models [9].

The control X ray at 1 year postoperatively showed a complete fracture healing (Fig. 4). Clinical control was good (DASH Score 76) [10].

3. Discussion

Multiple factors can contribute to fracture non-union. Humeral diaphysial fracture is always unstable and requires surgical

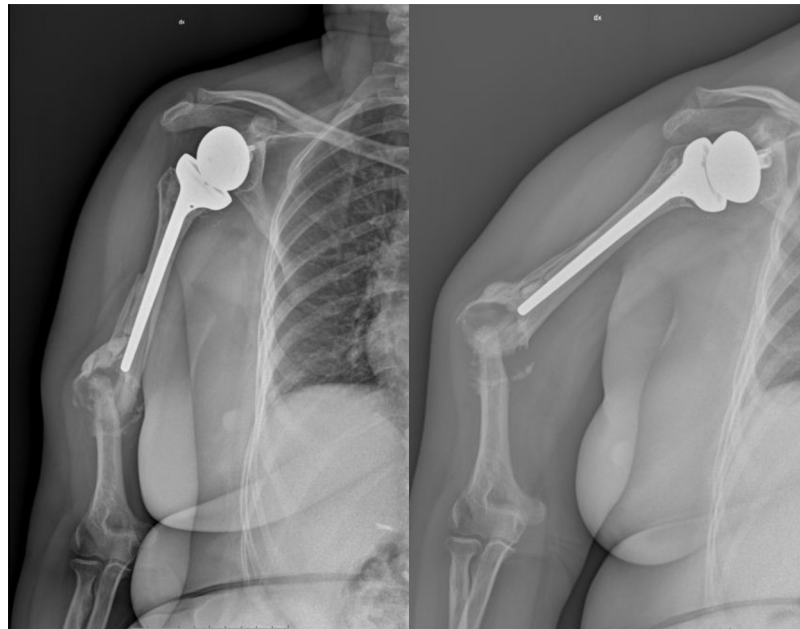


Fig. 1. Pre-operative x-ray view (left); varus angle deformity in shoulder abduction (right).

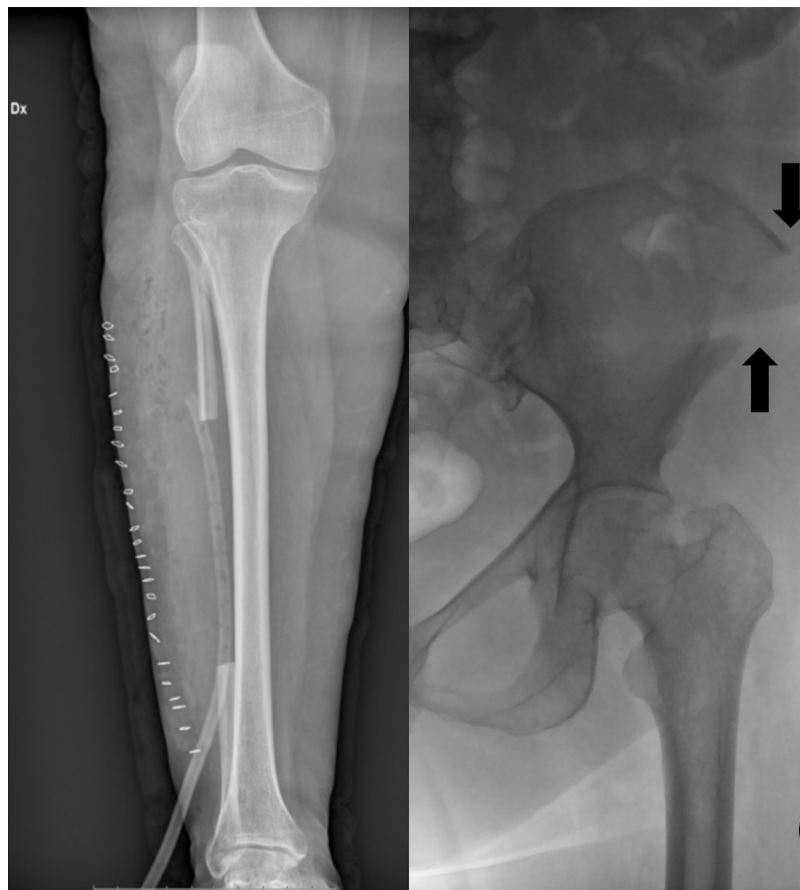

Fig. 2. Autograft bone from peroneal diaphysis (left); cortical bone from iliac crest (right).

approach. Non-union may occur after surgical treatment when a good reduction of the fracture or a stable fixation is not achieved. Systemic environment can be another cause of bone healing failure and non-union, but it is essential to respect biomechanical principles to reduce failure percentage.

The application of bone autografts offers an additional guarantee to “revitalize” non-union locus. Actually bone substitutes [11], scaffolds, bone marrow, platelet rich plasma [12] and mesenchymal stem cells represent a supplementary resource for efficacious treatment. In this case, we tried to achieve the best solution in

Download English Version:

<https://daneshyari.com/en/article/5732749>

Download Persian Version:

<https://daneshyari.com/article/5732749>

[Daneshyari.com](https://daneshyari.com)